

TRANSACTIONS OF THE NEW YORK SURGICAL SOCIETY
AND THE PHILADELPHIA ACADEMY OF SURGERY

Joint Meeting Held February 9, 1927

DR. WALTON MARTIN in the Chair

CIRRHOISIS OF LIVER; OMENTOPEXY; SPLENECTOMY

DR. ALLAN O. WHIPPLE presented a man, thirty-six years of age, who was admitted to the Presbyterian Hospital of New York, August 24, 1920, on account of copious hæmatemesis. His history was essentially negative. He had never had any pain or discomfort after meals. He had noted, that at times during the past year, his stools had been dark; had been subject to frequent nose bleeds. Two months ago when apparently in perfectly normal health, he experienced sharp pain referred to the middle of the abdomen which disappeared after a few minutes. During the following night, he began to vomit food mixed with blood, the vomiting recurred at frequent intervals for a period of some hours when it ceased. There was no pain. He remained in bed thereafter for a period of ten days when he felt as well as ever. Three days before admission he was awakened from a sound sleep by nausea and vomiting. The vomitus was chiefly dark blood; was about one-half pint in amount. Soon after he also passed a black stool. Following this, his hemorrhage ceased, leaving marked weakness. When he was admitted, his general physical examination was essentially negative save for anæmia; the abdominal examination revealed, in the left upper quadrant, a palpable mass extending from the midline down to the level of the umbilicus, not tender, smooth, firm, edge rounded, no notch made out. Red blood-cells, 3,300,000; hæmoglobin, 50 per cent.; white blood-cells, 2000; polymorphonuclears, 63 per cent. Small lymphocytes, 26 per cent.; large lymphocytes, 8 per cent.; transitionals, 3. Clotting time seven minutes; bleeding time normal. Red cells showed central pallor; platelets slightly diminished in number. The attacks of blood vomiting continued on account of which he was given three transfusions. At time of operation, the red blood count was 2,400,000; hæmoglobin, 60 per cent. Ascites developed with rapidity, demanding two tappings previous to operation.

At operation the peritoneum contained from three to five litres of straw-colored fluid; liver was cirrhotic; spleen was enlarged eight to nine times normal size; spleen was removed and a tongue of the omentum, 10 cm. long, was drawn out through the upper angle of the wound and fastened in the cleft formed by the split rectus fibres. Spleen, after removal, weighed 6 kilos; microscopical section showed almost complete disappearance of Malpighian bodies.

Convalescence was complicated by a right lower lobe pneumonia. Later he developed a thrombo-phlebitis of brachial vein. He gained markedly in weight; there was no re-accumulation of ascitic fluid. When discharged, red blood-cells were 4,500,000; hæmoglobin, 90 per cent. Now, over six years after operation, he remains well; has had no recurrence of ascites; no vomiting of blood; no gastro-intestinal disturbance of any sort; bowels regular; general health perfect. Red blood-cells, 5,000,000; hæmoglobin, 85 per cent.; white blood-cells, 7300; platelets, 350,000. Scar linear and firm; no hernia; no ascitic fluid; liver edge not palpable and on percussion, liver would seem to be somewhat smaller than normal.

CIRRHOSIS OF LIVER

DR. T. TURNER THOMAS (of Philadelphia) said that in the Philadelphia General Hospital, in which the percentage of indigent alcoholics is very high, he had been able to find brief records of four cases in which he had resorted to omentopexy.

DOCTOR THOMAS had undertaken the operation in each case with little expectation of benefit and as the result of his experience had not been able to develop any enthusiasm for it. The greatly lowered vital resistance of the patients, the usual advanced cardio-renal disease, absence of sufficient functioning of the liver and sometimes other grave complications, make the prospects for long-continued benefit doubtful. Except in one case which died thirty-two days after operation, the early results of the operation were distinctly encouraging, but death was not long delayed by it. The combination with splenectomy as done by Doctor Whipple may so change the results as to increase his confidence in the operation.

His first case was operated upon August 17, 1908. In this case, after the abdomen had been opened, the peritoneal surfaces were rubbed with gauze and the omentum was sewed to the anterior parietal peritoneum. The abdominal wound was closed without drainage, leaving a suprapubic opening for drainage to pelvis. The patient was discharged two months and two weeks after operation. During the subsequent year he was readmitted and discharged several times and finally died one year and twenty-three days after operation; still had ascites.

The second case was admitted to Philadelphia General Hospital, April 29, 1919. In February, 1919, without apparent cause, his abdomen began to swell. Getting no relief he came to Philadelphia General Hospital as above stated, about two months after beginning of swelling. From then to October 22, 1919, date of operation, he was tapped seventeen times at intervals of from four to twenty-three days, a total of fifty gallons being removed. Urine examined twelve times and showed a few hyaline and granular casts, a trace of albumin and occasional leucocytes.

Operation.—The adjacent surfaces of the diaphragm and anterior abdominal wall, liver and spleen were rubbed with gauze, the omentum at the upper part sewed to the anterior abdominal wall, and lower part in the abdominal incision. Rubber drainage tube to bottom of pelvis through suprapubic stab wound. Sutures removed November 12, and patient transferred to Medical Department, December 23, and after a short stay discharged. He was readmitted March 1, 1920, and transferred to the almshouse, where he died June 27, 1920, eight months after operation. Could obtain no record of cause of death or of condition preceding it.

The third case was admitted to Philadelphia General Hospital, November 22, 1923. She was a woman, thirty-four years old, and a chronic alcoholic; diagnosis: mitral regurgitation; hepatic cirrhosis, with marked ascites (tapped many times); chronic nephritis.

Under date of December 16, 1923, the following note was made: Repeated abdominal tappings have failed to check the transudation of fluid into the abdominal cavity. The portal obstruction must be extreme, for at times the patient passes blood by the rectum.

December 24, 1923, under spinal anæsthesia, a midline incision was made and a great quantity of straw-colored fluid evacuated. The liver was found to be atrophic and firm, but not nodular. The peritoneal surfaces of the liver

and spleen, stomach and intestines were rubbed with dry gauze, as well as the corresponding surfaces of the abdominal wall and diaphragm to induce the later development of inflammations and adhesions. The omentum was sutured to the peritoneum of the anterior abdominal wall as widely as possible. A suprapubic stab wound was made below the inferior margin of the operation incision and a rubber drainage tube inserted to the depth of Douglas' Pouch.

January 16, 1924, paracentesis yielded 4000 c.c. of greenish, turbid, frothy fluid.

January 23, 1924, abdomen tympanitic. Dulness in flanks. Peristalsis abnormally active in upper abdomen. Diminished in lower abdomen.

January 25, 1924, died, thirty-two days after operation. Autopsy showed fibrinous, purulent peritonitis and intestinal obstruction. Clinically the signs were of mechanical intestinal obstruction.

The fourth case was admitted to Philadelphia General Hospital, September 16, 1925, complaining of weakness and swelling of the abdomen and lower extremities of about three months' duration. He is fifty-six years old and has been a laborer working in and about breweries and saloons. He says he has been a heavy drinker all his life, but was perfectly well until about three months before admission when he first became aware of a gradual swelling of the abdomen and weakness without other symptoms. A physician tapped his abdomen, obtaining a "medium-sized bucketful." He was soon admitted to another hospital, but did not stay longer than a week, his abdomen being tapped there twice, each time about a bucketful being taken out. The swelling of the abdomen has been progressive during the four weeks preceding admission to the Philadelphia General Hospital, the legs and scrotum participating to a very marked degree. He says he was never ill before, never vomits except after excessive indulgence in alcohol. He has averaged a half pint of whiskey a day for the past ten years. He weighed 180 pounds three months ago, since when he lost twenty pounds. Is not now acutely ill but very uncomfortable from the abdominal swelling and oedema of the legs and scrotum and the dyspnoea. He has the characteristic alcoholic facies, but while his heart sounds are impaired in quality it is regular and has no murmurs and his lungs are in good condition. There are distended abdominal veins and ascites present but no gastro-intestinal symptoms except loss of appetite. Repeated examinations of his urine have shown not more than a faint trace of albumin and no casts. On September 18, seven litres of fluid were withdrawn from abdomen, but on September 25, only a small quantity probably because of the shortness of the canula, although on the following day the site of the tapping drained profusely. October 15, forty ounces were withdrawn and on the following day he was transferred to the Surgical Ward. Blood Wassermann, negative. Urine: specific gravity 1020, faint trace of albumin, no casts and no red blood-cells.

Operation.—October 30, 1925. A median incision is made about eight inches long from about two inches below the umbilicus upward. On opening the abdomen only a moderate quantity of fluid escapes, but more is soaked up and removed by gauze pads. The liver is contracted and hardened. The upper surface of the liver and the adjacent diaphragmatic surface is rubbed vigorously with gauze on both sides of the falciform ligament. In like manner the surfaces of the stomach, intestines, spleen and to a less degree the omentum, with the corresponding parietal peritoneum, are irritated. The omentum is then sutured to the anterior abdominal wall by three catgut sutures as far out as can be reached, the lower part of the omentum being

CIRRHOSIS OF LIVER

left free to be brought outside the peritoneum where it is sutured between the recti muscles, the margins of the divided linea alba being sutured together over it, after the peritoneal margins are closed around the protruding omentum. In the preceding cases a suprapubic drain was introduced into the bottom of the pelvis, but is omitted in this case because of the small quantity of fluid withdrawn by tapping and during the operation.

December 2, although the abdomen is moderately distended, free fluid cannot be demonstrated. There is now no œdema of the abdominal wall, scrotum or extremities, although he has been out of bed walking about or sitting down about eight and one-half hours. He says he has no shortness of breath, no feeling of weakness and experiences no difficulty in going up or down stairs. His face has lost the somewhat shiny redness and puffiness which was present before operation and is slightly wrinkled and hollow. He is very anxious to be discharged in order to go to work which he says he is as fully able to do as before his troubles began about three months before admission. He admits a strong desire for something to drink. He was discharged December 4, 1925. Six weeks later he was readmitted to Medical Ward on account of renewed swelling of abdomen and dyspnoea. Admits having been drinking steadily since discharge one month ago. The day after his admission eight quarts of fluid were withdrawn by trocar. He died January 27, 1926, twelve days after admission and almost three months after operation.

DR. JOHN SPEESE (of Philadelphia) said that the addition of an omentopexy in the treatment of Doctor Whipple's case might cause some confusion, that it had been used by him as a measure of further diverting blood from the liver in an advanced case of Banti's disease, whereas Doctor Thomas was alluding to an entirely different group of cases, *i.e.*, portal obstruction from cirrhosis of the liver. The improvement in the patient's condition must have been due to the splenectomy which is now regarded as the operation of choice and if these cases of splenic anæmia are operated upon early in their development, a cure should be obtained by removal of the spleen in a very high percentage. Unfortunately the majority of them come to the surgeon in a late stage, but even with adhesions between the spleen and the surrounding parts, with fibrotic changes in the liver and ascites, removal of the spleen is followed by pronounced improvement in many instances and the hemorrhages occasionally encountered, are almost immediately checked.

DR. WILLY MEYER (of New York) called attention to the eventual benefit to be derived from the use of superheated air treatment, when the omentum had been placed subcutaneously. Last winter he showed a patient before this Society, who had been operated on in 1911 for carcinoma of the rectum which was excised. He returned in 1924 with pronounced ascites. Tapping was done; but the liver was not palpable and not enlarged. X-rays seemed to indicate a possible malignancy of the stomach; and therefore exploratory laparotomy was done without finding any pathology in the stomach. The liver was seen to be rather reduced in size and in a condition of chronic inflammation; the patient was neither alcoholic nor syphilitic. As there was no secondary tumor, omentopexy was clearly indicated and carried out by placing a portion of the omentum in a pocket below the skin. Three weeks

later the patient had to be tapped once more, but subsequently made an uninterrupted recovery under the daily prolonged use of superheated air, which was continued at home for many months. It was observed that the ascites receded from week to week. This was two years ago and the man has remained perfectly well. Judging from this experience the simple method deserves to be tried in similar cases.

DR. A. P. C. ASHHURST (of Philadelphia) said that he believed the splenectomy had more to do with effecting a cure in Doctor Whipple's case of Banti's disease than the omentopexy. Portal obstruction does not cause ascites, it causes gastro-intestinal hemorrhages; and many years ago Rolleston had pointed out that patients with uncomplicated cirrhosis of the liver never lived long enough to require more than one tapping. The patients who survive many tapings have something else than cirrhosis: they have a polyserositis, or they are cases of Banti's disease. It will be noted that the only case in Doctor Thomas' series in which omentopexy was of benefit had hemorrhage from the intestines before operation. The speaker thought one should restrict omentopexy to patients with hemorrhage and in cases of ascites merely take out the spleen, if Banti's disease seemed to be the cause, or attempt to relieve the abdominal serositis by gauze friction over the liver and spleen.

RUPTURED ANEURISM OF FEMORAL ARTERY

DR. ALLAN O. WHIPPLE presented a man, twenty years of age, who was admitted to the Presbyterian Hospital of New York, June 6, 1926, on account of painful swelling of the left thigh. Previous history negative, except for initial lesion of lues four years ago. Five months ago, he first noted a swelling of the left mid-thigh which has gradually increased in size until now it measures the size of an infant's head. Pain has steadily increased in it and has been extreme during past month. Swelling occupies lower two-thirds of left thigh. It is diffuse, fluctuant, hot and tender. There is no definite evidence of any expansile pulsation, although there was a slight bruit. Entire lower leg is oedematous; X-ray shows periosteal proliferation of lower third of femur probably of luetic origin. Red blood-cells, 2,300,000; hæmoglobin, 40 per cent.; white blood-cells, 22,800; polymorphonuclears, 88 per cent. Wassermann positive. A transfusion of 700 c.c. of blood was made, after which the red blood-cells rose to 2,800,000; hæmoglobin, 50 per cent.

Operation, under spinal anæsthesia, was begun by incision over Scarpa's triangle. This opened a cavity from which a sudden gush of old broken-down blood together with fresh blood took place. Left femoral vessels were ligated at once. This controlled the bleeding. On sponging the cavity, there was a sudden release of pus. Amputation was then performed below the trochanters. Patient stood operation well, but because of his anæmia, another transfusion was given after the operation. Cultures of pus showed pure growth of hæmolytic streptococcus. Dissection of the amputated extremity revealed a funnel-shaped enlargement of the femoral artery beginning 7 cm. below the level of the distal end of the femur. This was continuous with an aneurismal wall which had ruptured and become indistinguishable from the surrounding soft parts. Both ends of the funnel-shaped enlargement opened directly into the broken-down tissue of the soft parts. The middle third of the femur showed areas of thickened periosteum and in other areas eroded bone. The operation wound was Dakinized. Pulse and

DIVERTICULUM OF THE BLADDER

temperature rapidly returned to normal. Pain immediately relieved; general condition improved rapidly from day to day. Further healing without complication.

DR. HUBLEY R. OWEN (of Philadelphia) said he had a case similar to Doctor Whipple's in his ward at the Philadelphia General Hospital some fourteen years ago. The patient was an elderly woman who on admission had a large inflammatory tender fluctuating mass in the upper third of the left thigh. As the patient was in considerable pain on her admission in the evening, the Resident Physician ordered the patient taken to the Women's Dressing Room and, after freezing the area with ethyl chloride, opened into the supposed abscess. The mass proved to be a dissected aneurism of the femoral artery. The tissues superimposed upon this aneurism were infected and considerable pus was evacuated before the aneurism was reached. The patient had a massive hemorrhage. The Resident Physician applied a tourniquet and when Doctor Owen was called it was necessary to do an immediate amputation. It was impossible to control all the bleeding about the aneurism. The patient never recovered from the shock of the operation and died a few hours later.

DIVERTICULUM OF THE BLADDER

DR. EDWIN BEER said that it is surprising that diverticulosis of the hollow organs has been recognized as a frequent occurrence only during the last twenty-five years. Diverticulum of the œsophagus and Meckel's diverticulum of the small intestine have been recognized for many years; on the other hand, diverticula of the intestine up to 1904 was scarcely appreciated as a clinical entity. In that year he was able to collect in his original paper on "Intestinal Diverticula" only eighteen cases from the whole literature of the preceding half-century. Nowadays, however, the condition is well known as a clinical entity, and hundreds—if not thousands—of cases of this disease have been recognized by the profession and the condition is regularly considered in the diagnosis of intestinal cases. Diverticula of the bladder have fared even worse than diverticula of the intestine, and it is only during the last fifteen years that numerous observers have been studying this condition and removing diverticula of the bladder by surgical procedures. Cystoscopy and cystography have opened this field to surgical therapy.

DOCTOR BEER then demonstrated a series of diverticula in lantern slides. Some of these diverticula of the bladder are enormous—one case having held as much as twenty-six ounces of residual urine. That they are probably congenital in a great many cases is evident from the fact that numerous cases have been discovered in children—one even in the first year of life. The presence of these diverticula leads to difficulty in emptying the bladder, and frequently a secondary dilatation of the ureter and hydronephrosis. Some of them are associated with obstructions at the neck of the bladder, and in prostatics or patients with contracture of the bladder neck; diverticula are liable to develop. The orifices are seen as a more or less dark hole cystoscopically, but the exact size of the pouch can only be determined by filling

it with an opaque fluid and taking X-ray pictures antero-posteriorly and laterally. Complications set in when these diverticula are infected and, occasionally stones form in these diverticula and have to be removed with the diverticulum. Occasionally, some of these stones project into the bladder as collar-button or dumb-bell stones filling the diverticulum and presenting as a mushroom growth within the bladder lumen. If the stone is left in the diverticulum, the stone extension into the bladder is regularly liable to reform so that the patient will get recurrent vesical calculi. In other cases, tumors

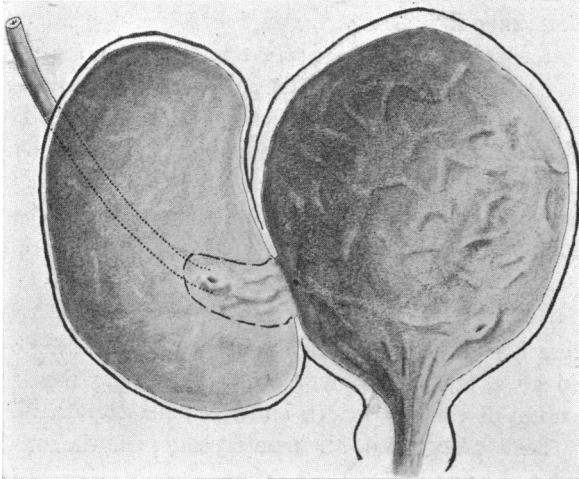


FIG. 1.—Diverticulum of bladder with ureter emptying into diverticulum. Triangular flap of diverticular wall outlined; the rest of diverticulum cut away.

form in the diverticulum, which present a group of cases that are most difficult to treat satisfactorily. With infection, peri-diverticulitis sets in and the pouch becomes firmly adherent to all the pelvic structures so that removal becomes a most difficult and arduous undertaking. In some cases the ureter empties into the diverticulum at some distance from the bladder, and various methods for caring for ureter were developed.

The case about to be presented, shows a new method for caring for such a ureter which emptied into a diverticulum one and one-half inches from the bladder. The presence of one of these infected diverticula leads to very slow healing of the suprapubic wound, and occasionally in prostatectomies, one is forced to go in secondarily to get a closure of the suprapubic wound by the removal of the infected diverticulum. It is interesting to note that in the series of cases numbering well over two dozen that have come to operation in his experience, none of the diverticula have been seen in the female sex.

DOCTOR BEER then presented a man, sixty-six years old, who was admitted to Mt. Sinai Hospital, September 16, 1926, having been troubled with great urinary frequency for some time. At times overflow; at present, apparently, completely obstructed. Immediate suprapubic drainage operation was done, and after patient's blood chemistry had dropped, the second-stage removal of a small fibrous prostate was accomplished. No cystoscopy was done before operation. The patient's suprapubic wound, despite all attempts to encourage healing, failed to heal completely. It would regularly break down after being closed for a short time. His residual urine continued after operation around twelve ounces.

A cystogram was taken, and a large diverticulum was found on the right side of his bladder. Cystoscopy showed that this diverticulum was in the region of the right ureter orifice; its opening was about the size of a dime.

DIVERTICULUM OF THE BLADDER

The left ureter secreted good blue, whereas no right ureter orifice could be seen. It was concluded from the cystoscopy that the right ureter emptied into the diverticulum.

January 7, 1927: A very adherent large diverticulum was excised, and it was found that the right ureter entered this diverticulum about one and one-half inches from the bladder. The ureter was left attached to a triangular flap, the rest of the diverticulum being excised; and the apex of the triangle

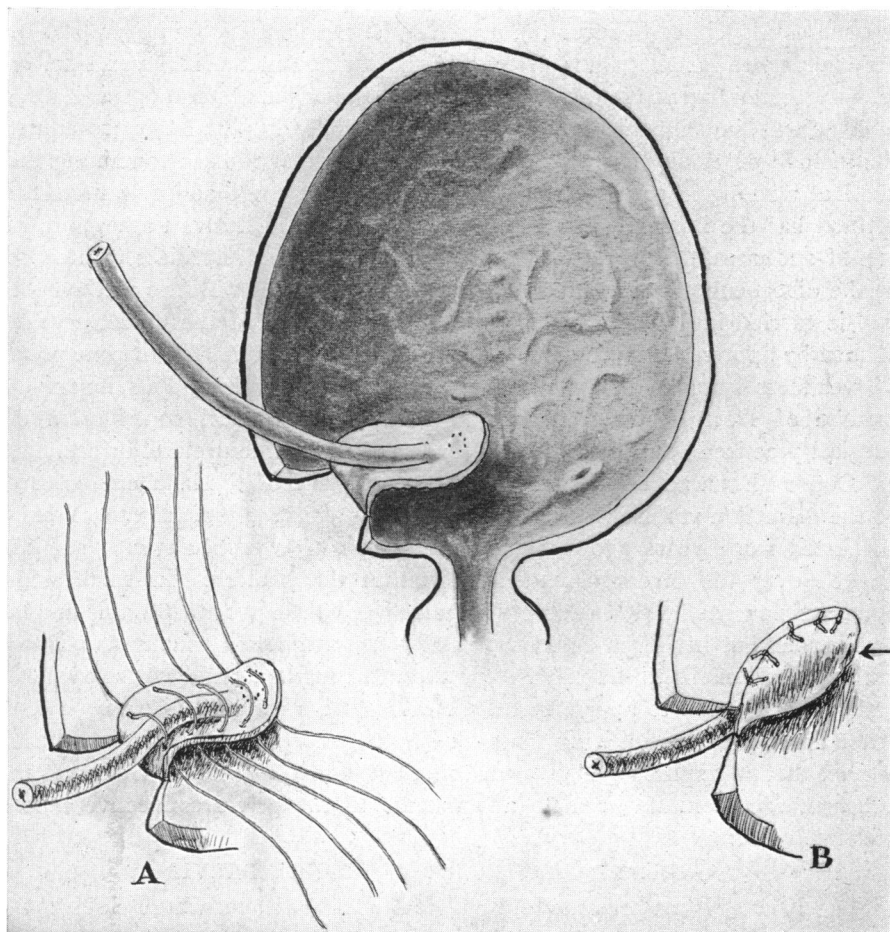


FIG. 2.—Illustrates steps by which right ureter was implanted into bladder and covered with diverticular wall.

was then drawn into the bladder and the mucous membrane of the diverticulum sewed over the ureter which now projected into the bladder. The orifice of the diverticulum was closed by several chromic gut infolding stitches applied to the outer wall of the bladder. The ureter catheter was passed up the right ureter at completion of operation to make sure that there was no stenosis caused by the plastic operation.

The patient's recovery has been uneventful, and with an indwelling catheter, his suprapubic wound has closed almost completely, or completely, so that patient is almost ready to be discharged from the hospital.

DR. LEON HERMAN (of Philadelphia) said that in the surgical treatment of bladder diverticula excision of the sac is undoubtedly the method of choice, but the best means of its accomplishment differs in different cases. There are two types which present unusual difficulties, namely, those in which the ureter opens into the sac, and those in which the sac springs from the inferior wall of the bladder in close approximation to one or the other ureter. In the surgical treatment of the first type, such as that presented by Doctor Beer, it is necessary either to sever the ureter and transplant it to another part of the bladder, to ligate it, thus destroying the kidney on the involved side, or to dissect out a flap of the diverticular sac containing the ureteral opening, and, in some way, implant this into the bladder. In following the latter procedure, the method of Young has been used, in which part of the sac containing the ureteral opening is employed to close the defect in the bladder wall. This method has the inherent disadvantage of employing defective tissue, and, in one of our cases, the procedure was followed by almost immediate recurrence of the diverticulum necessitating re-operation. In Doctor Beer's method the flap is carried into the bladder cavity and the closure of the defect accomplished by approximating the edges of the healthy bladder wall, the one point of weakness being at the point of entrance of the ureter. This ingenious method of Doctor Beer's appears to be a very practical contribution to surgical practice in dealing with diverticula containing the ureteral orifice.

DOCTOR BEER added that in removing diverticula of the bladder, the ease of the dissection varied with the degree of peri-diverticulitis. Doctor Young suggested some years ago a method of aspirating diverticula with suction applied over the diverticular opening within the bladder. In small non-adherent pouches, which probably require very little treatment, this might be feasible, but in larger diverticula that cause symptoms usually associated with firm adhesions to the pelvic structures, this method could not be applied, and the suggestion to apply it in these cases was somewhat jocular. These latter diverticula are so firmly imbedded by peri-diverticular inflammation as a rule, that it requires the greatest muscular effort to pull and dissect the adherent sac from its intimate attachments to the pelvic connective tissue and fat.

PAPILLARY CARCINOMA OF KIDNEY PELVIS

DR. EDWIN BEER presented a man, forty years of age, whose chief complaint was an intermittent hæmaturia, with practically no pain until recently when he experienced some pain in left lumbar region. His painless hæmaturia began a year before admission (May, 1925), lasted three weeks and was profuse. Then there was a quiescent period. Six months before admission he had another attack of hæmaturia, and during the following months prior to admission, he had fifteen to twenty more attacks, bleeding usually for a few days at a time. Of late he has had some pain in the left lumbar region which did not run downward but radiated toward shoulder; pain gradually became more accentuated but seems to have no relation to hæmaturia.

He entered the hospital in May, 1926, after his last attack of hæmaturia had ceased. Physical examination showed no costo-vertebral tenderness and no abdominal palpatory findings. Cystoscopy showed a normal bladder and

PAPILLARY CARCINOMA OF KIDNEY PELVIS

normal ureters; no obstruction in either ureters and no retention in either pelvis. It was impossible to induce bleeding in the left kidney pelvis, where it was thought the tumor was placed, by active to and fro manipulations of ureter catheter. The left kidney urea was 0.6 per cent., whereas the right was 2.0 per cent.; microscopic urinalysis showed an occasional red cell on the left, and many on the right. Several pyelograms were made, one of which showed very definitely incomplete filling of the left kidney pelvis and calices giving the appearance of fluffiness as if the pelvis was more or less filled with a spongy mass, making diffuse irregular densities.

The patient returned in September, 1926, with the history that he had been bleeding for three weeks. Cystoscopy, while bleeding, showed blood came from left ureter, and none from right ureter. Moreover, at all levels in the left tract, bloody urine was obtained. At this examination, just in front of the left ureter meatus, a minute papilloma about the size of the head of an ordinary pin, was discovered which was probably an implant from the renal pelvic tumor. This was immediately destroyed with the high frequency current.

September 13, 1926: Nephro-ureterectomy was done with excision of wedge of bladder about left ureter meatus through a lumbar kidney

incision in which the vascular pedicle was tied; combined with an extra-peritoneal left rectus incision, exposing the lower ureter and bladder. On exposing the left kidney, it was found to be normal in appearance, normal in size, and the pelvis felt as if it were moderately distended with a soft spongy mass. No tumor could be felt. The parenchyma was absolutely normal in consistency. On removing the specimen the kidney was opened, and on incising the pelvis a papillomatous tumor, which filled the pelvis, mushroomed out through a small incision as if it had been under considerable tension.

Pathological diagnosis and microscopic report was "papilloma of kidney pelvis with early malignant changes."

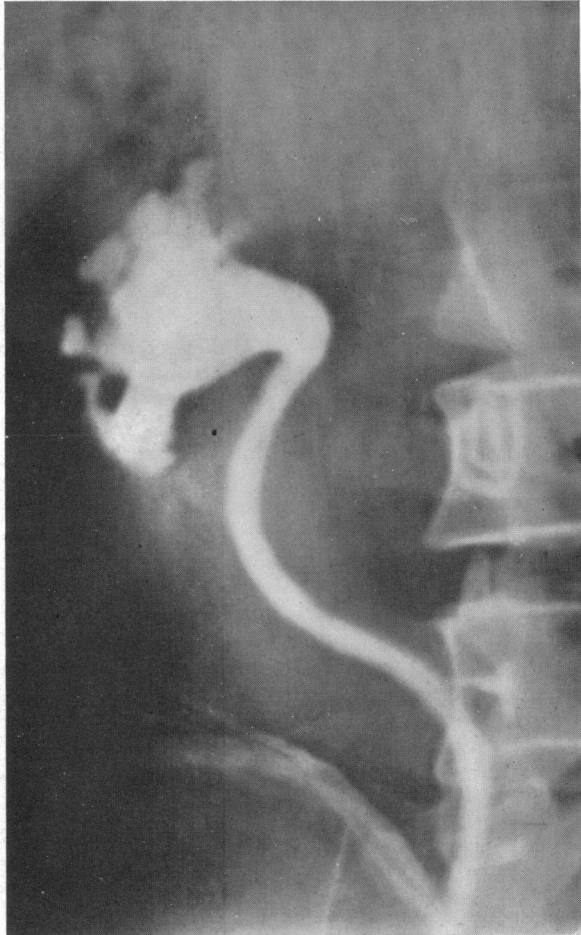

FIG. 3.—Pyelogram of papilloma of kidney pelvis. To bring out the delicate contrast shadows in the pelvis which was filled with a spongy papilloma, the original film had to be reversed and then printed.

TUMOR OF ACOUSTIC NERVE

DR. A. S. TAYLOR presented an adult male who was admitted to Bellevue Hospital, December 10, 1925. Since March, 1924, he had been deaf in his right ear. In December, 1924, he developed an unsteady gait. In November, 1925, hammering sounds developed in right ear with blurred vision; no headache, nausea or vomiting. Upon admission, examination revealed the following conditions: old healed Pott's disease, upper dorsal; bilateral papilloedema; marked nystagmus, coarse to left, fine to right; hypæsthesia of right cranial fifth nerve (including cornea); paresis of seventh nerve; sense of taste diminished on right side of tongue; right auditory nerve deafness; pedal ataxia on the right side; caloric test showed dead labyrinth on right side. Diagnosis was made of right cerebello-pontine angle tumor (acoustic nerve) for which an operation was done December 21, 1925. Ether anæsthesia. *First stage*; a curved, horse-shoe incision running from within one mastoid up over the occipital bone then down on the opposite side to the inner margin of mastoid. The occipital bone was entirely removed, including the posterior one-third of the foramen magnum; also the posterior portion of the Arch of the Atlas was removed. At this stage his general condition was such that operation had to be discontinued and the flap was temporarily sutured. *Second stage*; one week later—the dura was opened across both sides and then a fair-sized tumor of the right acoustic nerve was exposed.

The sheath was quite vascular and because of the generally poor condition of the patient it was not deemed wise to attempt complete enucleation of both the sheath and the tumor. Therefore, the sheath was split longitudinally and the tumor was completely enucleated from inside. When hæmostasis was complete the wound was closed, leaving the dura open for decompression.

His condition was very bad when he went off the table and that evening it was necessary to do a blood transfusion which very greatly improved his condition and after which he made a steady and satisfactory recovery.

In this case the tumor was approached by means of a curved incision passing across the head about 2 cm. above the superior curved line. At the outer ends this incision is turned downward so as to pass just within the posterior border of the mastoid on each side. The skin and galea are dissected downward until a plane has been reached about .5 cm. below the superior curved line, when an incision is carried vertically through the attached muscles down to the occipital bone. In this way a good portion of muscle and fascia is left attached to the superior curved line for the purpose of the later closure. The muscles are then elevated from the occipital bone forward and downward until practically the entire occiput is exposed. From that point on the bone is removed, as usual, including the posterior one-third of the foramen magnum, and the posterior arch of the Atlas in such cases as it is indicated. With this incision, in the majority of heads and necks, it is possible to retract this flap sufficiently to get a perfectly adequate exposure for work anywhere in the posterior fossa.

This incision avoids the necessity of the median leg of the so-called cross-bow incision and, therefore, saves a great deal of time both in the making and in the later suturing; also saves a certain amount of bleeding. The only objection which has been raised to this flap has been that by carrying the outer ends of the incision downward back of the mastoid, there has sometimes been a greater likelihood of the development of a spinal fluid fistula. However, with proper attention to the closure of the lower ends of the incision, the wound can be perfectly protected from such leakage.

The point of chief interest from the standpoint of surgical technic lies

SPINAL CORD NEUROFIBROMA

in the incision; *i.e.*, the horse-shoe flap without the cross-bow midline incision.

This particular case with the kyphos of the uppermost dorsal vertebræ would seem an unusually bad case for this exposure. Nevertheless, with this single flap turned down there was a perfectly good exposure with which to reach this angle tumor.

SPINAL CORD NEUROFIBROMA

DOCTOR TAYLOR presented a colored man, twenty-four years of age, who was admitted to Bellevue Hospital, January 17, 1927, with a history that six months previously he had developed: (a) Numbness of the entire left side of the body. (b) Two weeks later, weakness of the right leg. (c) Chronic constipation. (d) Two months after onset, vesical precipitancy. (e) Three months after onset, weakness in left leg, and right leg had progressed to complete paralysis. (f) Four months after onset, complete paraplegia plus weakness of right hand. Coughing, sneezing and yawning caused sharp pain in both arms. There was no history of venereal or other disease.

Physical examination showed the presence of: (1) Spastic paraplegia with increased knee and ankle jerks. (2) Absent plantar response. (3) Symmetrical atrophy of both lower limbs, also of the hypothenar muscles of the right hand. (4) Sensory level perfectly definite at cervical vi and vii, below which pin-prick was entirely lost; touch sensation much diminished, especially on the left side. Below the sensory level was a well-developed Brown-Sequard syndrome. Temperature sense was lost. Joint position lost in the toes. Vibration lost below the level of the pelvis. Deep pain lost in the calves. *X-ray pictures* were negative. *Blood and spinal fluid* negative. *Manometric test* showed complete block. *Pre-operative diagnosis*: Tumor of spinal cord at level of cervical vi, right side.

Operation.—January 20, 1927, a right hemilaminectomy of the v, vi and vii cervical vertebræ was done. When the laminæ were removed six and seven were somewhat thinned and beneath them there became visible a tumor, dark in color, elastic in consistency and with very marked pulsation, such that it was suspected of being an aneurism for a time. Further exposure showed it to be ventro-lateral, extradural, extending from the sixth intervertebral canal, which was expanded to 1.5 cm. in diameter, inward and upward along the ventro-lateral aspect of the dura. It was largest about 1 cm. from the upper end where it evidently caused the most compressoin of the cord.

It was enucleated by sharp dissection and when completely removed showed both the anterior and posterior nerve roots of cervical vii incorporated in the tumor, most of the fibres lying between its capsule and the surface of the tumor proper. The dura was not opened.

His post-operative recovery was very rapid: (a) Within twenty-four hours he began to move his legs. (b) Four days after operation there was increased voluntary movement of toes, ankles, knees and hip-joints. (c) Sensation to pin-prick and touch returned on the left side. (d) Sensation to pin-prick and touch returned over the sacral area on the right side. (e) Deep sensibility, joint position, deep pain, vibration—unchanged. (f) Urinary precipitancy—gone. Progress has been very rapid since that time, he being able to walk with some assistance in balancing on the nineteenth day.

Pathological Diagnosis.—Neurofibroma.

Remarking upon this case the reporter said that inasmuch as a number of cases have been reported in which bilateral cervical laminectomy has been followed within a few months, or a year or two, by dislocation of the cervical spine, it would seem wise to adopt a method which would preserve as much

of the bones, ligaments and muscles as possible, in order to preserve the stability of the spinal column.

In one case reported by Adson there was sufficient dislocation to have caused complete transverse myelitis, which later resulted in death.

Two cases reported by Mixter showed perfectly definite dislocation; in one case without symptoms, and in the other case, which had passed from observation, a late fatal result which may or may not have been the result of forward dislocation.

In a fourth case, in which a patient after complete bilateral cervical laminectomy returned after two years with well-marked disturbance of all four extremities, definite angulation with forward dislocation of cervical iii on iv is shown. It is probable that his neurological symptoms are not due to this dislocation at the present time. Nevertheless, the changes in the cervical column are certainly ominous for the future.

Every laminectomy in the cervical region should therefore be primarily a hemilaminectomy for the purpose of exploration and then if occasion demands it, bilateral laminectomy may be done readily over as much or as little of the opposite side of the spine as may be necessary.

CHRONIC INFLAMMATION OF CAUDA EQUINA

DOCTOR TAYLOR presented a third patient, a man, aged fifty-five years, who was admitted to Bellevue Hospital, November 1, 1926, with a history of: (a) Sharp pain in both lower extremities since October, 1925. (b) Pain rapidly extended into the lumbar region, followed by difficulty in walking, in May, 1926. (c) Sphincter disturbance developed in August, 1926.

Physical examination showed: (1) Atrophy and weakness of the glutei, ham-strings and calf muscles on both sides. (2) Ankle-joints lost on both sides. (3) Left knee-joint lost; right knee-joint diminished.

Sensory examination showed loss of sensation in the sacral ii, iii, iv and v on the right side and sacral iv and v on the left side. *Manometric test* showed no block. *Lipiodol injection* showed a lesion at the level of the fifth lumbar vertebra. *X-ray plates* also showed considerable osteo-arthritis disturbance of the lower spine.

November 10, 1926, he was subjected to a right hemilaminectomy from lumbar iii to sacral i, inclusive. The muscles were thick and the wound was at considerable depth, so that the procedure was somewhat difficult. When the dura was exposed it was found that there was a perfectly solid, hard tumor about 3 cm. long and apparently 1.5 to 2 cm. in diameter which lay just in the midline and which could not be satisfactorily exposed or dealt with through a hemilaminectomy. Therefore, the exposure was converted into a bilateral laminectomy. The dura was split over the hard tumor which, when exposed, proved to be most of the cauda equina matted into a hard mass by a chronic inflammatory process. After this mass had been separated into the various nerve bundles, a projection was felt extending backward from the anterior wall of the spinal canal, between lumbar v and sacral i. This projection was smooth and extended somewhat across the front of the spinal canal. It was thought to be a chondroma. The anterior layer of the dura was divided vertically as well as the posterior spinal ligament. Spinal fluid was constantly coming into the wound and when the dura and the vertebral ligament were divided, the flow was considerable.

On attempting to feel the tumor over which the incision had apparently been made, it could no longer be distinguished and a probe passed through the incision freely into the space between lumbar v and sacral i. Evidently the disc had liquified and this liquid, under tension, had projected backward,

CHRONIC INFLAMMATION OF CAUDA EQUINA

simulating a chondroma and then had escaped through the incision, mingling with the cerebro-spinal fluid.

There was a slight improvement in the neurological condition following the operation. There was very marked relief from his pains until he began to sit up.

In view of the complete laminectomy and the obvious damage to the intervertebral disc, it was felt necessary to have a well-made support before he was allowed to get up. Therefore, a plaster jacket was applied to lift the weight of his torso from the spine and put it on the iliac crests. In this case, had hemilaminectomy been feasible for the completion of the operation, it would have been possible to do a fusion of the remaining arches and spinous and articular processes, which would have given him earlier relief from the external supporting apparatus.

DR. THOMAS A. SHALLOW (of Philadelphia) said that the question of the use of hemilaminectomy as a primary procedure in all tumors of the spinal cord should be questioned. It is true that in certain limited cases the exposure of the cord or the dura of the cord is all that is sufficient for a proper extirpation of the growth. In certain cases a complete laminectomy is not only advisable but imperative. This is stated with a full realization of the points brought out by Doctor Taylor of tumors of the cervical region where a complete laminectomy had been performed on several of the lamina. Doctor Taylor admits that under certain conditions a complete laminectomy is absolutely necessary for the completion of the operation. He claims that it requires not more than ten minutes to convert a hemilaminectomy into a complete laminectomy. There is valuable time lost after the dura has been opened and the cord exposed; it is at this period in the operation when shock plays a strong rôle in the question of mortality. The speaker believed that in all tumors involving the membrane in front of the cord and tumors within the cord a complete laminectomy is obligatory.

In the tumor of the substance of the cord in the cervical region which Doctor Shallow operated upon, he believed it could not have been removed through a hemilaminectomy, and was sure that had he had only a hemilaminectomy to begin with and then converted this into a complete one, he would have lost his patient through shock on the table from the added ten minutes of exposure of the cord.

DR. CHARLES A. ELSBERG said that since Doctor Taylor had reintroduced the curved incision instead of the cross-bow incision which everyone took up on Cushing's advice, surgeons have been using the single incision more and more often. For many years Doctor Elsberg was opposed to the operation of hemilaminectomy, mainly because the operation is not quite as simple and one could not obtain as free and wide exposure of the spinal canal, and because—in operating around the spinal cord—it is of great importance to handle the cord as little as possible. Consequently he felt that a complete laminectomy was indicated in all instances except where the nerve roots on one side only were to be divided. He thinks, however, that the arguments Doctor Taylor has presented for hemilaminectomy, especially in the cervical

region, are very good ones and that he is right when he says one should begin with hemilaminectomy and then, if necessary, increase the bone removal until both laminae and spinous processes have been removed. In Doctor Taylor's case of extra-dural tumor it would seem there may already have been some bone changes. But that does not interfere with his argument, which is an excellent one, and in the future, Doctor Elsberg said he will do hemilaminectomy in the cervical region more often.

DR. A. P. C. ASHHURST (of Philadelphia) asked Doctor Taylor if he had had trouble from sloughing of the scalp as a result of cutting the occipital artery on both sides. The speaker previously had used the cross-bow incision of Cushing, but he had one patient who had extensive sloughing of the scalp and after that he heard of similar experiences in the hands of other surgeons, because the occipital artery was divided low down. Then his associate, Dr. Temple Fay, called his attention to the midline incision from the inion to the upper cervical region, as described last year by Doctor Frazier, securing more room if necessary by dividing the spinal muscles from within outward below the distribution of the occipital artery. This gives good exposure and there is no subsequent sloughing.

DOCTOR TAYLOR, in closing the discussion, said that he had been doing hemilaminectomy since 1903 and had removed good-sized tumors from within the dura, dividing the posterior roots up both sides; in other words, he got good exposure. Doctor Elsberg and he had discussed this from different points of view for fifteen years and it was pleasant to learn that they were now in accord. It takes a certain amount of facility to acquire the amount of exposure this procedure may give. All those things, regarded as difficult for hemilaminectomy, have been done and the patients have gotten well and stayed well if the proper tools were employed. Of course one cannot get as free and wide an exposure as if one takes both sides to the same degree, but one can get sufficient, so why waste the bone on the other side? Then, too, if hemilaminectomy is done and a lesion is found that cannot be satisfactorily handled through hemilaminectomy, it can be translated to double laminectomy in two minutes. In the old days when neurological localization was not as good as it is now, it was always a possibility that the tumor would be found to be far above or below the apparent localization, and if full laminectomy had been done very little spine was left when the tumor was finally removed. But exploration could be done through hemilaminectomy and then, if more room were needed, it could be taken without so much damage. As to Doctor Ashhurst's question, Doctor Taylor said he had never seen sloughing in this incision and thought there must have been something unusual in Doctor Ashhurst's case. So many had been done without any sloughing that when it occurred the cause must lie elsewhere, than in the division of the occipital artery. With regard to the midline incision, the speaker was attracted by that for cerebellar tumor as it gives good exposure. He had been enabled by it to handle a left lobe cystic glioma successfully.

DILATATION AND PERFORATION OF THE CÆCUM

DILATATION AND PERFORATION OF THE CÆCUM IN OBSTRUCTION OF THE DESCENDING COLON OR SIGMOID

DR. JOHN DOUGLAS said that if, as the result of complete obstruction, the intestine above the point of closure becomes sufficiently distended, perforation may ensue. Usually, the maximum distention and perforation occurs immediately proximal to the point of obstruction. Perforation probably occurs only as a result of mechanical ileus. In the small intestine it is usually located on the intestinal surface most distant from the mesentery.

It has been shown experimentally and clinically that the mechanism of this process depends on interference with the blood supply, due to pressure from within the intestinal lumen acting on the thin wall and narrow lumen of the vessels. This pressure obliterates first the veins, which rupture and cause blood extravasation. Then the additional pressure occludes the arteries and necrosis of the intestinal wall results.

In the large intestine, location of the maximum distention may not be immediately above the point of obstruction, but may be at some distance proximal to this point. That is, in obstruction of the descending colon or sigmoid, great distention of the cæcum may occur, which may result in splitting of the serous coat of the cæcum, or even terminate in perforation and general peritonitis. This condition has a bearing on diagnosis; complicates the symptom complex; and may have a determining influence on the operative procedure. His attention was first directed to this condition by the following case:

A woman, age sixty-five, was admitted to St. Luke's Hospital, June 26, 1924, with symptoms of acute intestinal obstruction. Constipation and gas pains had been present for four months. For ten days before admission she had cramp-like pains in the abdomen with dull pain on the left side under the ribs. Bowels had not moved for forty-eight hours, and vomiting had been persistent for twelve hours. Radiograph, after opaque enema, showed obstruction at the junction of the descending colon with the sigmoid, and marked gaseous distention and dilatation of the cæcum. At operation, an annular carcinoma of the descending colon was found, but the cæcum was so distended that the peritoneal coat had split along a distance of 4 to 5 cm. Although the small intestine and colon between the cæcum and point of obstruction were also distended, the dilatation was far less than that of the cæcum. The condition of the cæcum made it advisable to perform a cæcostomy rather than to attempt immediate delivery of the growth which was above the sigmoid, making mobilization difficult. The resection of the growth was done at a later stage and the cæcostomy closed at a third operation. There have been no signs of recurrence to date.

While this dilatation of the cæcum has been frequently observed, even proceeding to the degree of splitting of the serous coat during operation, it is not well known by the majority of surgeons. Still less so is the fact that as a result of low obstruction in the large intestine the cæcum may become distended to the degree of perforation. This is illustrated in the two following cases:

A man, age fifty-four, was admitted to the Knickerbocker Hospital, November 19, 1924, with a history of general abdominal pain for ten days, finally localizing in the right lower quadrant. Very small movements from

bowels at first, later none. Had vomited frequently, but had continued working and had no medical attention until day before admission to the hospital, when all symptoms became worse. He was admitted in a moribund condition with all the signs of advanced general peritonitis, and died within a few hours, no operation being done. At autopsy, a carcinoma at the rectosigmoid junction was found, and a general peritonitis, due to fecal extravasation from a perforation of the cæcum at the base of the appendix.

A man, age sixty-five, was admitted to Bellevue Hospital, April 19, 1925, with history of constipation for six days; vomiting five days; distention and pain increasing up to admission. The history indicated intestinal obstruction—the physical signs of general tenderness and rigidity, with elevated temperature and blood count, a general peritonitis. At operation, a carcinoma of the pelvic colon was found with a general peritonitis, due to perforation of the cæcum. A cæcostomy was done, but the patient died thirty-six hours later.

These cases are not presented to illustrate a new observation, but to recall to mind an old one apparently not known, or forgotten, by many. Twenty-five years ago, in 1902, Willy Anschutz, in the *Archives für Klinische Chirurgie*, Bd. lxxviii, p. 195, published a report of five cases of obstruction, two of carcinoma of the splenic flexure, two of the sigmoid, and one case of volvulus of the sigmoid. All showed great distention of the cæcum, and one had perforated with resulting peritonitis. He explains this phenomena in certain cases by the resistance of the ileocæcal valve and the fact that the normal diameter of the cæcum is greater than that of the rest of the colon. That this distention should be greater, therefore, in the cæcum by natural physical law he proves by attaching two rubber finger cots or balloons of different diameters at the ends of a T-tube and injecting air at the centre. Although the walls of the balloons were of equal thickness, the one of larger diameter always became the more greatly distended.

It has seemed worth while to recall attention to this condition, as, should the physical signs or the X-ray evidence as shown by a plain plate, of a greatly distended cæcum, in the presence of symptoms of intestinal obstruction, be present, it may point to the possibility of the obstruction being low in the colon. Also this cæcal distention, resulting in pain, and tenderness on the right side may cause a mistaken diagnosis of appendicitis to be made, as was the case in a patient with a carcinoma in the lower part of the sigmoid recently seen. It is also suggested that this tendency of the cæcum to dilate more than other portions of the colon, when the ileocæcal valve is especially resistant, may have some bearing on the vague, irregular, right-sided pains in constipated patients, thus causing a faulty diagnosis of chronic appendicitis to be made.

MEGACOLON

DR. RICHARD W. BOLLING presented two patients as illustrating one of the problems in the treatment of megacolon, or speaking more correctly, of megasigmoid and megarectum. As the anatomical condition was similar, the two cases were presented together.

They were both admitted to the medical side of St. Luke's Hospital in the summer of 1922, at which time one was thirteen and the other fifteen years of age. In both the immediate history was of abdominal pain, diarrhoea and loss of weight. In the case of the younger boy there was a history of stomach trouble and constipation since birth and he had been under obser-

CARCINOMA OF THE COLON

vation at the hospital for one year with recurring attacks similar to the present one. The older boy had a definite history for only one month. In each patient there was an enormous fecal impaction, with greatly dilated rectum and sigmoid colon.

After the relief of the immediate symptoms, the patients were transferred to Surgical Division "A" and assigned to Doctor Bolling for treatment. After careful consideration, resection of the sigmoid colon was carried out and a little over two feet removed in each instance. This portion of the intestine was greatly dilated and the wall thickened. The process obviously involved the rectum. The remainder of the large intestine was relatively normal, though in one case considerably dilated. In this case an axial anastomosis was effected. In the other a lateral anastomosis was carried out on account of the great disparity in the size of the dilated rectum and the apparently normal descending colon. Convalescence was uneventful and within a year one patient gained 22 and the other 29 pounds.

The younger patient was shown to this society May 9, 1923. There persisted in both patients a marked tendency to constipation and in the second and third year after operation, each patient had an attack similar in all respects to the ones before operation. Since that time there have been no attacks of such severity and although evacuation of the bowels is irregular, the condition is kept under fair control by the patients themselves. The involvement of the rectum was fully recognized at the time of operation, but the operation was performed in the hope that removal of the sigmoid loop would increase the efficacy of ordinary medical measures.

Cases such as these should not, in Doctor Bolling's opinion, be included in the group of so-called idiopathic dilatation of the colon, but should be regarded as instances of acquired megacolon resulting from a tendency to fecal stasis due possibly to some developmental defect in the wall of the intestine.

A similar condition is apparently prevalent in Argentina and in 1922 (Corbin, F. G., *Megasigmoid, Megarectum, Fecal Bolus. Surg., Gynec. and Obst.*, vol. xxxv, pp. 23-34, July, 1922). Doctor Corbin referred to a personal experience of over two hundred cases of fecal impaction with enormously dilated rectum and sigmoid. In his article he makes the statement that more deaths occurred in Mendoza from this condition than from appendicitis, gastric ulcer, duodenal ulcer and cancer of the rectum combined.

In a recent article (Mirizzi, P. L., *Total Colectomy as a Treatment of the Megasigmoid. End-to-End Anastomosis. Archives of Surgery*, vol. xiii, pp. 837-845, December, 1926) Doctor Merizzi, of Cordova, reports recurrence following similar operations and advises total colectomy with implantation of the ileum into the recto-sigmoid.

This procedure would seem scarcely justified in cases such as the ones shown by Doctor Bolling. In the future in similar cases Doctor Bolling will be inclined to defer operation and depend upon medical measures, operating only for volvulus or other acute condition. This of course does not apply to true Hirschsprung's disease, in which the rectum is rarely involved.

CARCINOMA OF THE COLON

DR. RICHARD W. BOLLING presented a man, aged fifty-four, as a recent result of the application of the multiple stage operation in carcinoma of the cæcum. The patient was admitted to St. Luke's Hospital in July, 1926, with a history of epigastric distress for three and one-half years and of a tumor

in the right side of the abdomen for three years. There had been no symptoms of intestinal obstruction, but anæmia, weakness and loss of weight had been progressive. On admission the patient appeared in very poor general condition and his hæmoglobin was 45 per cent.

After transfusion, Doctor Bolling operated and found a bulky growth in the cæcum. The cæcum and ascending colon were freed in the usual manner. The growth in the cæcum, with the adjacent ascending colon and ileum, was exteriorized and cut away with the cautery, after the walls of the ileum and ascending colon had been united. A tube was introduced into the ileum.

The first operation was carried out July 20. A clamp was applied to the spur a few days later and the fistula was closed August 19. The patient was discharged September 11. A small sinus persisted for several weeks but the wound is now soundly healed.

This type of operation is not usually indicated in growths of the cæcum, but there are exceptions in which its application is very useful.

DOCTOR BOLLING presented also a woman who was admitted to St. Luke's Hospital in March, 1922, with a history of diarrhœa, abdominal distention and loss of weight. At that time she was twenty-six years of age.

Röntgen-ray examination indicated partial obstruction in the lower sigmoid and the sigmoidoscope revealed an irregular growth eight and one-half inches from the anus.

DOCTOR BOLLING operated and a growth occupying the lower sigmoid and growing into the lumen of the gut was found. Resection of the growth with immediate axial anastomosis after the tube method was done. The pathological report was adenocarcinoma of the sigmoid without involvement of the regional lymph-nodes.

Convalescence was uneventful and the patient was discharged twenty-one days after operation. Following her discharge she received a series of Röntgen-ray treatments and a temporary artificial menopause was induced. She was married about three years ago and recently consulted Doctor Bolling in regard to a perineal laceration sustained at the birth of a child two years ago.

She has no symptoms referable to the original condition and it is now a few weeks less than five years since her operation.

TUMORS OF THE CÆCUM

DR. JOHN F. ERDMANN (of New York) read a paper with the above title, for which see page 722.

DR. GEORGE P. MÜLLER (of Philadelphia) said that he had had nine or ten cases of carcinoma of the cæcum, three of tuberculosis and one case of undetermined origin. This patient was a young Japanese who for three years had had slight pain in the right iliac fossa. Recently there had been an acute exacerbation. The pre-operative diagnosis was acute appendicitis. At operation the mass was found to be in the wall of the cæcum and about four cm. in diameter. It was thought to be cancer or tuberculosis and the cæcum and ascending colon were removed. The mass in the cæcum was a localized abscess in the wall which on culture was found to be sterile. The cases of tuberculosis were of the hyperplastic variety in two instances and one was ulcerated. This man had no other evidence of tuberculosis, yet he

TUMORS OF THE CÆCUM

had a thickened ascending colon containing five ulcers. All of the cases of tuberculosis recovered. In regard to carcinoma of the cæcum, the speaker had noted that Doctor Erdmann had eighteen cases as compared to approximately twenty-two on the left side. Usually the proportion is found to be greater. The speaker believed that in these right-sided tumors obstruction is uncommon; very few of his had acute obstruction. When the end of the ileum was involved the obstruction was chronic and the small bowel hypertrophied. Pain was of more consequence than on the left side. His experience with the X-ray is that of Pancoast who thinks the picture of cancer undistinguishable from that of tuberculosis of the cæcum. Doctor Erdmann had referred to the finding of Craig and McCarty, that in 32 per cent. the lymph-nodes were involved. It is better to put it the other way and state that in sixty-eight there is no metastasis to the lymphatics; hence there is a good chance of curing carcinoma of the cæcum. The operation is very easy. The speaker said he usually makes his incision closer to the bowel than pictured by Doctor Erdmann. In resection for cancer of the cæcum he has had no trouble with the duodenum. Only in carcinoma of the hepatic flexure is one liable to run foul of the duodenum. Regarding the method of operation, Doctor Müller said he had done end-to-end anastomosis and end-to-side, and had found no difference. In the end-to-end one has to trim the bowel, and the speaker was more partial to the end-to-side method. Lateral anastomosis has given him an obstruction in two cases. If there is considerable obstruction a preliminary operation must be thought of, but there is danger of infection from a preliminary ileostomy. So unless there is a real shut down, it is better to do the entire procedure at one time. Doctor Müller agreed with Doctor Erdmann that infection is common. These patients are septic and one has to work carefully. Most of the speaker's cases had bled and some he had had to transfuse. One patient had an ileostomy and then bled and was transfused two or three times. At the operation to remove the growth it was found that it had advanced so far during this period of three months as to be inoperable.

DR. JOSEPH A. BLAKE said in regard to the malignancy of right-sided growths, he had found them to be more so than on the left side of the abdomen. Recurrences had usually taken place within five years, and some in a very short time. The last recurrence, or rather extension, which he had observed only that day, was in a woman twenty-eight years of age, from whom the cæcum ascending colon and terminal portion of the ileum had been excised for carcinoma of ileocolic junction eight weeks ago, at which time the ovaries were normal, but to-day both were found to be the site of carcinomatous growths six inches in diameter. Some of these tumors are very malignant, much more so than those occurring in the sigmoid. There is a low malignancy in carcinoma arising in the appendix which lowers the general mortality of right-sided carcinomata. Doctor Blake said he had generally done the end-to-side anastomosis.