

TRANSACTIONS OF THE NEW YORK SURGICAL SOCIETY
AND THE PHILADELPHIA ACADEMY OF SURGERY

JOINT MEETING HELD FEBRUARY 13, 1929

DR. FRANK S. MATHEWS in the Chair

TUBERCULOSIS OF THE THYROID GLAND WITH SECONDARY
LYMPH NODE INVOLVEMENT

DR. CARL EGGERS, of New York, presented a woman, thirty years of age, who was admitted to the Lenox Hill Hospital, June 7, 1926, complaining of swellings in the neck associated with pain. She had been well until a year before when she developed occasional sharp pain in the right side of neck which did not yield to treatment. About six months later the thyroid gland began to enlarge and soon after enlarged lymph nodes began to appear on the right side of the neck. The pain had become worse, was constantly present, and radiated to the teeth and right ear. There were no other symptoms of constitutional disease. She was married and had one healthy child. Her menstruation was normal.

The patient was a well-developed, fairly healthy-looking woman. She weighed 122 pounds. The general examination showed nothing grossly abnormal. The outstanding feature was an enlarged thyroid and a chain of enlarged lymph nodes on the right side of the neck. Both lateral lobes of the thyroid were enlarged, they were nodular and unusually hard, and quite tender to touch. The pulse rate was increased to ninety, and there was tremor of the hands, but there were no other symptoms or signs of hyperthyroidism. The posterior chain of lymph nodes on the right side of the neck was enlarged, the glands felt very hard and were not adherent to the skin. The basal metabolism rate was +23. The blood count showed 4,032,000 red blood cells with 81 per cent. hæmoglobin; leucocytes 8200 with 61 per cent. polymorphonuclears. The urine was negative. The nasopharynx was negative.

At operation the affected lymph nodes were removed first through a four-inch incision along the posterior border of the sternocleidomastoid muscle. The entire chain of nodes was removed in one mass, beginning the dissection below the mastoid.

A subtotal thyroidectomy was then done, leaving only a small portion of soft thyroid tissue posteriorly. There was very little bleeding. The gland tissue on section looked pale and rather fibrous. It was very hard.

The convalescence was uneventful and both wounds healed by primary union.

The pathological examination showed chronic tuberculous lymph adenitis and chronic tuberculosis of the thyroid gland. The following is a detailed microscopic report submitted by Dr. F. D. Bullock:

Sections of several of the nodes show discrete and confluent tubercles in a good state of preservation, and large caseous areas surrounded by epithelioid cells and scattered tubercles. There is considerable fibrosis of the nodes and fibrous thickening of the capsules.

Sections of the thyroid show the thyroid tissue to be divided up into lobules of different sizes by bands of dense fibrous tissue. The interlobular stroma is increased in amount and the parenchyma is mostly atrophic. Both the interlobular and intralobular fibrous tissue show an infiltration of many small round cells. Scattered here and there through the gland are giant cells and collections of epithelioid cells which sometimes surround multinucleated giant cells. There is no evidence of malignant disease.

HÆMORRHAGE FOLLOWING GASTRO-ENTEROSTOMY

The patient subsequently developed enlarged lymph nodes in the right supraclavicular fossa which were removed, May 21, 1928, and were also reported to be tuberculous. Except for this she has remained well. At no time have there been symptoms or signs of tuberculous involvement of the lungs or any other organ.

Tuberculosis of the thyroid gland is a rather rare condition. The more acute form is usually found in general systemic tuberculosis and appears as miliary tubercles throughout the gland. It is of little interest to the surgeon.

The more chronic type may appear in an otherwise normal gland or in a gland showing other pathological changes such as adenomata. One may find tuberculous granulation tissue, caseation, abscess formation or fibrosis, depending on the severity of the infection, the length of time it has existed and the resistance of the patient to the infection. Surrounding structures may become involved, and frequently the lymph nodes draining the gland become affected. The presence of tuberculosis in the gland usually tends to hyposecretion from pressure on the normal tissue rather than to hypersecretion. Subtotal thyroidectomy performed before the disease has spread to surrounding structures offers a good prognosis.

GASTROTOMY FOR HÆMORRHAGE FOLLOWING GASTRO-ENTEROSTOMY

DOCTOR EGGERS presented a man, twenty-nine years of age, first seen by him October 16, 1928. He had symptoms of duodenal ulcer on and off for ten years, and for the last four years had been under competent medical care. In spite of this the condition recurred every few months. Each attack lasted three or four weeks. His chief complaint was pain, coming on either before or after meals. Sometimes it was relieved by eating. He also complained of nausea, but there was no vomiting. Lately he had been failing, and he had lost eight pounds during the preceding month. Gastric analysis and X-ray examinations had repeatedly been done corroborating the diagnosis of duodenal ulcer.

After admission to the hospital his gastro-intestinal series was repeated, and showed constant deformity of the duodenum without retention. A test meal showed high acidity. Blood examination and Wassermann were negative.

Operation was performed October 26, 1928. The stomach was about normal size. Its prepyloric region was red in color. About half an inch below the pylorus a chronic ulcer was visible on the anterior surface of the duodenum. It was not particularly infiltrated, but had produced decided narrowing of the lumen with dilatation of the duodenum above, suggestive of a diverticulum. A short loop posterior gastro-enterostomy was done, using chromic catgut for the inner and silk for the outer suture. Special care was used to ligate the small vessels on the stomach and gut before incising the mucosa. The operation was smooth and satisfactory. There was no bleeding. The stomach was fastened into the slit in the transverse mesocolon and the abdomen then closed. Patient left the table in very good condition.

About two and a half hours later he vomited a small quantity of blood which was attributed to oozing from the suture line. No special attention was paid to it, and a hypodermic of morphine ordered. After that he vomited several times, each time a large quantity of blood, both fluid and clotted, amounting to approximately 1600 cubic centimetres in all. He failed rapidly, looked shocked, perspired profusely, and his pulse was small and thready, 130-140 per minute. The abdomen was again opened seven hours after the gastro-enterostomy. A transfusion had been ordered in the meantime but there was difficulty finding a donor. Though several donors of the same blood group were brought to the hospital, the blood of none of them matched and it was not until the next day that a transfusion from the patient's brother could be given.

A hypodermoclysis of Ringer's Solution was started before the operation was begun. When the wound was reopened, the abdomen looked clean and the organs were in normal position. The stomach was not dilated and showed good tone. (He had vomited just before operation.) A gastrotomy was done by a vertical incision through the anterior wall of the stomach, directly opposite the gastro-enterostomy. The blood within the stomach was removed by suction and the stoma was then inspected by everting its margins. At first no bleeding point was noted, but after allowing the tissue to relax, active bleeding was found along the posterior margin of the stoma. The blood was bright red, evidently arterial in character, but there was no spurting, perhaps due to an overlying fold of mucosa. Several mosquito clamps were quickly applied and six or seven fine chromic catgut sutures were inserted until the field was completely dry. The gastrotomy wound was then closed and the stomach replaced. Abdomen closed without drainage.

During the operation an infusion of 550 cubic centimetres of Ringer's Solution was given. The patient was badly shocked and active stimulation was resorted to. When it was impossible to get a donor another infusion of glucose solution was given later.

The progress during the first few days after operation was slow, but with stimulation and subcutaneous administration of Ringer's Solution he gradually improved until a few days later he again began to vomit, had sunken eyes and a distended abdomen. Acute dilatation of the stomach was diagnosed and after a gastric lavage with the evacuation of enormous quantities of greenish-brown fluid definite improvement set in. He gained rapidly and was discharged four weeks after operation. He has remained well and his pre-operative gastric symptoms have cleared up. Röntgen-ray examination shows good function with emptying through the stoma complete after two hours.

Vomiting of a small quantity of blood or blood-stained fluid after a gastro-enterostomy is not uncommon and is no doubt usually due to oozing from the suture line. It may at times be due to oozing from the ulcer resulting from manipulation at the time of operation. It usually stops spontaneously. Real hæmorrhage is uncommon. The speaker had seen it only twice. In his very first case of gastro-enterostomy it came on about twenty-four hours after operation. The second case was the one now reported. In the former the bleeding was controlled by gastric lavage, with hot saline solution containing adrenalin, and the administration of medication aimed at favoring clotting of blood. By keeping the stomach empty and allowing it to contract the bleeding ceased and he made a good recovery.

In the present case administration of coagulen had no effect, and transfusion could not be used for its blood clotting properties because of the inability to find a proper donor. Moreover the bleeding was so active and the patient failed so rapidly that it seems his life was saved only by the direct attack on the bleeding point.

DR. ARTHUR E. BILLINGS, of Philadelphia, remarked that Doctor Schwartz had reported eight instances of hæmorrhage in a series of 398 cases following simple gastro-enterostomy, an incidence of nearly 2 per cent. Three of these cases died giving a mortality of slightly less than 1 per cent. In the April, 1928, issue of *Surgery, Gynecology and Obstetrics*, Dr. William L. Estes, Jr., of Bethlehem, Penna., reported two cases similar to Doctor Eggers' case. Active bleeding occurred a few hours after operation. He operated on both of them, invaginating the line of anastomosis through the stoma into the stomach and suturing with chromic catgut. Both cases recovered.

PYONEPHROSIS WITH SUPERNUMERARY KIDNEY

In cases where frank hæmorrhage of several ounces of bright red blood occurs a few hours after operation, surgical intervention is demanded. The use of clamps as a routine procedure has been sacrificed by a number of surgeons for simple traction and suture whereby the active bleeding points in the line of anastomosis can be treated by direct ligation. The speaker emphasized the value of one point in the technic of gastrotomy and that was the use of the Cameron light. It is of distinct advantage in some cases where the stomach is to be explored for a bleeding point.

PYONEPHROSIS, LEFT, WITH SUPERNUMERARY KIDNEY AND URETER

DR. JAMES I. RUSSELL presented a woman, twenty-four years of age, who was admitted to hospital with a ten-day history of pain in the upper lumbar and left costo-vertebral region, of rather sudden onset, increasing in severity the first few days. For several days prior to admission symptoms had somewhat subsided. She had previously felt perfectly well; past history entirely negative, no boils, no carbuncles, nor tonsillitis.

On admission Temp. 102.8°, white blood count 12,400; polymorphonuclears 69 per cent., and a moderate degree of secondary anæmia.

There was a firm, large and comparatively fixed mass in the left upper quadrant of the abdomen, extending down to the iliac crest. It was not particularly tender. It was dull on percussion, the dullness extending upward to the left nipple. The tympanitic colon was in front of the mass.

Voided specimens of urine contained large quantities of pus, but this was apparently largely contamination, as, with one exception, catheterized specimens rarely showed many pus cells. The patient, however, had not previously noted any purulent vaginal discharge.

She was kept under observation for some time, temperature ranging from 100 to 103 degrees, during which time a thorough search for tubercle bacilli in the urine was being made. On two separate cystoscopic examinations clear urine was obtained from both kidneys and was sterile when cultured. The left ureter was obstructed by partial angulation opposite the fourth lumbar vertebra. Pyelogram showed point of obstruction near the kidney pelvis with marked dilatation of the proximal half of the ureter.

The second pyelogram showed a massive dilatation of the upper half of the left ureter and the left kidney pelvis with a marked ptosis of the pelvis.

Blood culture, Widal and Wassermann were all negative. Blood chemistry was essentially normal. No tubercle bacilli could be found.

She was given a blood transfusion and operated upon during the second week in the hospital (December 17, 1928), with a temperature slightly higher than previously.

Through an oblique lumbar incision a large cystic mass was encountered, apparently within the parenchyma of the kidney, containing about one and one-half quarts of thick yellow pus. There was a veil-like tissue in the lower portion of this which shut it off from a large dilated ureter which extended down posteriorly over what proved to be a normal kidney. After evacuating the contents and dividing the large dilated ureter the cyst wall was dissected out. The lower portion of this was attached to the upper pole of an apparently normal kidney, which had its own vessels and separate ureter, and which was removed with the cyst wall.

Convalescence was normal. Vaginal examination failed to disclose any evidence of aberrant opening of the ureter.

Microscopically.—The renal tissue removed from the intact lower kidney showed normal picture. All the sections of the dilated upper sac showed its walls to be composed of a mass of chronic inflammatory tissue in which could be detected renal tubules. The section of ureter enabled one to detect all of its layers, throughout which there had been a dense invasion by lymphocytes and plasma cells.

The patient was discharged from the hospital on the twenty-seventh post-operative day entirely free from symptoms. She has gained weight and strength; and is now in good health.

DR. LEON HERMAN, of Philadelphia, considered Doctor Russell's case to be an instance of incomplete reduplication of the ureter, commonly called double pelvis. In these cases there is rarely external evidence of the reduplication in the form of grooves or depressions in the parenchyma dividing the organ incompletely into two segments. Rarer still is there complete separation, in which event the smaller segment constitutes a supernumerary or accessory kidney.

The minor degrees of incomplete reduplication of the upper ureter and pelvis are commonly encountered by the cystoscopist and offer several problems in diagnosis. First, in the event that the catheter tip is introduced into the healthy portion of a double pelvis, the other portion being diseased, it is possible on this account to be misled by the normality of the urine obtained, and to overlook the disease. Furthermore, one may be misled concerning renal function, the catheter draining only one-half or less of the kidney.

In more advanced states of reduplication, there is likely to be more decided separation of the segments of the kidney drained by each ureter, and while rarely performed successfully the operation of heminephrectomy must be considered. The failures with the operation are attributable in some instances to disease, such as tuberculosis, but more often to technical difficulties among which the impossibility of isolating the ureters due to their residence in a common sheath, or an impossibility of preserving the blood-vascular supply to the healthy segment, is important.

Among a series of more or less complete ureteral reduplications, only one was heminephrectomized successfully. This patient, a girl eighteen years of age, had complete reduplication of the left ureter, normal upper segment and pyonephrotic lower segment of the left kidney, and a ptosed hydronephrotic right kidney. The latter showed less function to phtalein than the upper normal segment of the left kidney and seemed unable to support life unaided. For this reason, operation on the left kidney was feared lest nephrectomy should prove necessary. This became imperative, however, and heminephrectomy was successfully performed. The remaining segment of the left kidney is now a better functioning organ than the right kidney. The operation was quite easy owing to the fact that the main vessels were attached to the healthy segment and the ureters widely separated. This is one of the rare exceptions to the usual practice. As conditions encountered in Doctor Russell's case show, total nephrectomy is necessary in most instances.

CARCINOMA OF CÆCUM

CARCINOMA OF CÆCUM—INTUSSUSCEPTION

DOCTOR RUSSELL presented a man, forty-six years of age, who was admitted to hospital, January 2, 1926, with a complaint of irregular, cramp-like pains in the right lower quadrant of the abdomen of eight months' duration, coming on following a herniotomy. He had been considerably constipated since the onset of his symptoms, but otherwise he felt well. There was no nausea or vomiting. He had lost thirty-eight pounds in weight during the past eight months. He had taken large amounts of morphine to keep free from pain.

An indefinite mass could be palpated beneath the recti muscles in the centre of the abdomen. It was fairly well fixed and somewhat tender.

He was suffering from a moderately advanced degree of secondary anaemia. White blood count 11,200; polymorphonuclears 86 per cent. Blood chemistry was essentially normal. He had no fever. Urine was negative.

Barium enema showed partial obstruction in the proximal portion of the transverse colon and the edge of a moderately enlarged liver. Character of obstruction was not determined.

Exploratory laparotomy was performed January 7, 1926. This revealed a chronic intussusception of the cæcum and ileocæcal junction into the transverse colon, apex being nearly over to the splenic flexure. The intussusception was reduced by manipulation without injury to the gut wall. An intra-intestinal tumor could then be felt in the cæcum. The cæcum was brought up into the wound and anchored with stitches.

Four days later the cæcum was incised. A pedunculated tumor was found projecting into its lumen: its pedicle was divided and the tumor removed and the defect in the cæcal wall closed by sutures. The attachment of the pedicle was found to be below the level of the ileocæcal valve.

The pathological specimen consisted of a very firm, ovoid mass 4x3x3 cubic centimetres in size, roughened on its surface. Cut section showed a hard, whitish, fibrous-looking mass, covered on the surface by softer grayish tissue, infolded in areas.

Microscopic examination showed areas of normal-looking glandular mucosa, considerable fibrous tissue stroma; in places typical solid masses and cords of invading epithelial cells; definitely carcinomatous in nature. No mitotic figures were seen. Two weeks later a third operation was performed consisting of an enterocolectomy, lateral anastomosis. Four centimetres of terminal ileum and fifteen centimetres of the cæcum, ascending colon, were removed and showed no evidence of malignancy in either gross or microscopic examination. Lateral anastomosis was effected between the terminal ileum and the ascending colon.

The patient was discharged on February 19, twenty-five days post-operative, with the wound well healed after very moderate suppuration. There was no faecal leakage. Bowels are now normal without catharsis. He has gained weight, digestion is good.

DR. JOHN H. JOYSON, of Philadelphia, said that polypoid tumor of the intestine is a well-recognized factor in intussusception. In one of the speaker's cases, an infant, the starting point of an ordinary ileocæcal type was in Meckel's diverticulum which intussuscepted, and by traction on the small intestine started up an ordinary type of intussusception. As to the technic, he understood that Doctor Russell first did an enterostomy, and then removed the malignant tumor, a two-stage operation. On the right side the speaker was in the habit of doing a one-stage operation for carcinoma, except in the presence

of acute obstruction. Where obstruction is present the technic of course is different. In left-sided cases he still practiced resection and anastomosis in two or three stages by the Mikulicz procedure, whether obstruction was present or not; and with much satisfaction as regards operative mortality.

CARCINOMA OF THE TONSIL AND ADJACENT TISSUES

DR. FRANZ TOREK, of New York, premised the presentation of two patients by saying that so much had been said about radium in the treatment of carcinoma of the oral cavity that a presentation of the subject from a purely surgical standpoint seems to be in order, especially as surgeons are learning to appreciate the dangers connected with the use of radium. His remarks would be confined to one phase of the subject, carcinoma of the tonsil, because its operative removal presents not only all the difficulties met in other parts of the oral cavity but probably some additional ones. Thus far it had not been his good fortune to meet with a case of carcinoma of the tonsil in which the affection was confined to that organ, hence the heading "Carcinoma of the Tonsil and Adjacent Tissues". Thus, in the case of the two patients whom he had selected for demonstration, one recent case and one nearly four years old, the carcinoma had extended from the tonsil to the tongue, the soft palate, the pharynx, and the soft parts covering the lower jaw. In one of the two, the recent case, the resection of the soft palate extended beyond the uvula, and not only the glossopalatine arch but also the pharyngopalatine arch on the affected side had to be resected.

The lesion usually presents itself as a superficial carcinomatous ulcer with an exceptionally firm and immovable substructure. As a rule the deep jugular lymph nodes are involved, especially those at the confluence of the common facial vein and the internal jugular. They represent the first station for receiving the lymph from the mucous membrane of the base of the tongue and the anterior and lateral parts of the pharynx. Though enlarged, they are not always carcinomatous, the pathologist occasionally reporting only a hyperplasia. Then there is a group at the lateral side of the internal jugular vein, which receives the lymph from the mucous membrane of the lateral and posterior parts of the pharynx. A third group is a chain along the jugular vein from the point where it receives the facial vein down to the place where the omohyoid muscle crosses its course. This chain is sometimes very sparse, sometimes denser; it usually receives the lymph from the preceding groups but sometimes directly from the lymph sources mentioned before, without first going through the other groups. From this chain the lymph passes into the venous system at the junction of the jugular and subclavian veins. A group of lateral deep nodes in the region of the scaleni and the trapezius and, finally, the supraclavicular group are not involved directly, but may be involved secondarily from one of the preceding groups. If the lesion extends to the floor of the mouth, the submaxillary and submental lymph nodes may also be involved.

The removal of the deep jugular lymphatic nodes at the confluence of the facial and internal jugular veins and the group of nodes to the outer side of

CARCINOMA OF TONSIL

the internal jugular vein higher up is imperative, and it is advisable to remove also the chain along the jugular vein down to the point where it is crossed by the omohyoid muscle. In cases where the lesion encroaches on the floor of the mouth the submaxillary and submental nodes should be removed if they are enlarged. This was done in the two cases shown.

The operation begins with the lymph-node dissection, after which the external carotid artery is tied beyond its first branch, the superior thyroid, thus cutting off the lingual, ascending pharyngeal, and ascending palatine arteries, all of which supply the new growth. The removal of the tumor may be done at the same sitting or may be postponed for a week or two, when the neck wounds will have healed. The supposed danger of spreading the new growth, when the lymph nodes, the normal barriers, have been removed, appears to be theoretical rather than actual, for after ligation of the external carotid one may usually observe a slight shrinkage of the new growth; its vital energy has temporarily abated.

Apparently hopeless cases sometimes turn out to be operable after good access is procured by proper exposure, a requirement which is met by bisection of the lower jaw, either median or lateral. The lateral bisection opens the oral cavity in closer proximity to the new growth, but the central cut through the jaw also gives very satisfactory access and has the advantage of being less likely to impair the function of deglutition, a rather important factor in guarding against aspiration pneumonia. Furthermore, if a lateral division is made, the muscles of mastication will tend to draw the shorter arm of the jaw up higher than the longer one which, in addition, is held down by the geniohyoid muscles. This tendency to displacement by the lateral division is met by making the cut through the jaw in an oblique direction, from above downward and forward, so that, when the short arm is drawn up, it will force the long arm to move with it. The speaker preferred the median incision and had practiced it regularly, with but a few exceptions.

The simplest form of anæsthesia is the colonic, but, to render it reasonably safe, the patient should never be deeply anæsthetized, as the preservation of the reflexes at the larynx helps to serve as a safeguard against aspiration, which is a frequent cause of pneumonia. He gave four ounces of ether, no paraldehyde and no chloretone, preferring to support an insufficient narcosis by the occasional inhalation of a little chloroform, that drug being selected, if the cautery is to be used.

The procedure is as follows: The patient is placed in a position with the head hanging from the edge of the table, so that blood and secretions may run away from the larynx into the nasopharynx whence they are removed by a suction apparatus. The lip is divided in the centre and the incision carried down in the median line to the middle of the hyoid bone. At the chin the incision goes down to the bone, in the submental space only through the skin and superficial fascia. The vessels are secured. The soft parts covering the chin are held apart but are left attached to the bone. Before the jaw is divided, one or two pairs of drill holes are made, to serve for subsequent rewiring of the man-

dible. The intact mandible affords a better support for the drill and better opportunity to estimate the correct alignment of the drill holes. The site of these drill holes is always obscured later on by the overlying soft tissues, therefore it may be of advantage to mark the site in some way, for instance by the insertion of a piece of sterilized toothpick which, after the bone has been sawed through, may be replaced by a thread. If the thread is inserted so as to form a loop on the inner side, it will serve subsequently for drawing the wire through the drill hole. The mandible may be divided either exactly in the middle or between the first and second incisors on the affected side, in which case the spine of the mandible with the insertion of the geniohyoglossus and geniohyoid muscles remains intact. The jaw is divided with a Gigli saw. A suture through the tongue serves to draw it in any given direction. The two halves of the mandible are held apart by retractors. The mylohyoid and digastric muscles on the affected side are divided near their insertion at the jaw. While the tongue is being drawn toward the healthy side, the mucous membrane covering the floor of the mouth is divided well back to the vicinity of the lesion. Now retraction of the jaw affords perfect access. For excision of the new growth the knife may be used or the cautery. He preferred the cautery, as the ensuing eschar insures against accidental implantation of tumor tissue into the wound. If the base of the tongue is involved, the resection begins at that organ, because, after the healthy part of the tongue has been released from the affected, infiltrated portion, it can be drawn out of the way much better than while it was still attached. The rest of the affected part is then circumscribed by the cautery at a distance of at least one centimetre from the new growth, and the entire mass is removed in one piece. Although the external carotid artery has been tied, it is necessary to watch for vessels, and these are secured promptly. The operation being completed the jaw is wired, and the soft parts are sutured.

The question of drainage has to be decided in each individual case. If the lateral approach was selected, the suggestion of establishing a pharyngeal fistula by attaching the pharyngeal mucous membrane to the skin deserves consideration, for it offers the best safeguard against aspiration of secretions. Later on, the fistula either closes spontaneously or is closed by the surgeon. In cases attacked by the median approach the drains are placed at the posterior end of the submental wound, provided one drains at all. He scarcely ever drained in these cases but depended upon natural drainage either forward through the open mouth or downward through the pharynx and œsophagus. The patient is carefully watched after the operation till he is well out of the anæsthesia, and he is placed with his mouth directed more or less downward. To guard against closure of the glottis due to sinking back of the tongue, the suture is allowed to remain in the tongue till the patient is well awake, so that the attendant may have a ready means to draw it forward, if necessary. The function of deglutition is trained as early as possible, water being given. The patient is also kept busy rinsing his mouth with permanganate of potash.

When the wounds have healed, the resulting defect appears surprisingly

MYCOTIC CYSTS OF THE LIVER

small, as may be seen in the two cases presented. In both cases the lesion was prickle-cell epithelioma; in both cases it involved the entire tonsil and portions of the tongue, soft palate, pillars of the fauces, and mucous membrane of the lower jaw. In the more recent case the involvement of the palate and of the pharynx was quite extensive. In the older case the lymph nodes were carcinomatous; in the more recent case they were merely hyperplastic. In the older case, about one and one-half years after the operation, there developed a lymph-node metastasis on the opposite side, beneath the parotid gland. A packet of superficial lymph nodes was removed and, somewhat later, a deeper packet which had probably been overlooked at the previous operation. Although both of these were carcinomatous, no metastasis has occurred since then. At the site of bisection of the bone there occurs a superficial necrosis, in which case the spicules of bone usually find their way out. In the older case presented the necrosis was rather more extensive than usual, and the scar at the chin is depressed where the sequestrum was shed; moreover, the union between the two halves is ligamentous, not bony, but, nevertheless, firm and immovable. In the recent case the union appears to be bony. In some cases the wire has to be removed, if a fistula leading down to it persists; in other cases it becomes imbedded without any reaction.

MYCOTIC CYSTS OF THE LIVER

DR. ALLEN O. WHIPPLE, of New York, presented a girl, eleven years of age, who was admitted to the Presbyterian Hospital with an enlarged abdomen. The child complained of no symptoms, but one year ago it was noted by her mother that her upper abdomen was increasing in size. This gradually increased and for past three months there had been noted a very distinct bulge in the upper abdomen. She had gained eleven pounds in the past year. There has been no definite pain but in the past three months there has been a distinct feeling of fullness in the upper abdomen after eating which has made her hesitate to eat full-sized meals. There has been no tenderness, no nausea or vomiting. There has been no urticaria or jaundice.

She was a rather thin, sallow, anæmic girl of eleven, shy but intelligent. There is some pallor of mucous membranes. The striking finding is the visible enlargement of the upper abdomen as shown by a marked bulge with three elevations or bosses in the epigastrium and right and left upper quadrants. There is no peristaltic wave, nor visible pulsation. On palpation no tenderness is elicited, but there is a definite fluid wave made out between the bosses in the right and left upper quadrants. These appear to be in an enlarged liver, the lower border of which comes well below the umbilicus on the right and to the level of the umbilicus on the left. The liver moves on respiration. On tapping the boss in the epigastrium a distinct hydatid thrill is noted by several observers. No fluid wave or shifting dullness is made out. Spine and extremities are normal. No œdema or urticaria is noted. Laboratory findings normal.

Flat abdominal film does not show either of the kidney outlines distinctly (due to enlarged liver). No shadows are present suggesting calcified nodes or calcified cyst wall.

October 4, 1928, she was operated upon with a diagnosis of hydatid cyst of the liver. When the peritoneum was opened, situated in the right and left lobes of the liver was a large cystic mass, the pearly white-colored wall of which could be seen through a thin layer of liver tissue. On incising through this the wall of a cyst was easily defined and was separated from the liver tissue

easily. After plunging the trochar into the cyst some 1500 to 1800 cubic centimetres of a brownish-yellow, grumous fluid, of a thick purée consistency, was aspirated. But this contained no hooklets or daughter cysts.

With the collapse of the contents by aspiration, using the technic of Alessandri, of Rome, it was possible to separate the first half of the cyst wall from the outlying liver tissue as easily as one does in hydatid cyst removal. But then the cyst wall appeared to merge more intimately into liver tissue so that soon it became impossible to draw out more of the cyst wall without much bleeding and tearing of liver tissue.

The cyst appeared to have two main compartments, one in the right, one in the left lobe, the former being the larger. On looking into the cyst cavity its anterior half, corresponding to the part that easily separated from living tissue, was smooth and of a pearly-white color, the cyst wall in this part measuring one to 0.5 centimetre in thickness. The deeper portion of the cyst appeared to have a lining of shaggy, broken-down liver tissue. There was no bleeding or flow of bile from the inside of the cyst cavity. The portion which merged with liver parenchyma bled easily, however, when attempts were made to separate it from the liver tissue. There was no evidence of ascites or portal obstruction. The gall-bladder and bile passages appeared normal. No evidence of other cysts in the abdomen was made out. The margins of the cyst wall were sutured to the abdominal wall and weak iodoform packing loosely applied to the subcutaneous tissue around the marsupialized cyst wall.

Three weeks later the patient was subjected to cystoscopy of the cyst cavity. It was possible by first irrigating the cavity and then filling it with normal saline to insert the cystoscope and get a very good view of the interior arrangement of the cavity.

It was made up of several pockets opening into the main cavity which had collapsed to a great extent. These side pockets had the appearance of diverticula as one sees them in the bladder. But the lining of the main cavity and its side pockets was made up of a variable amount of shaggy, fragmented pieces of necrotic liver tissue waving in the fluid very much as seaweed on the floor of the sea. No evidence of bleeding or bile-stained fluid was made out in the examination.

Pathological Report of October 8, 1928. Gross.—Specimen is a piece of tissue removed from the wall of a liver cyst. It is roughly triangular in shape and measures two centimetres along its base and two centimetres along the other two sides. The wall is four millimetres in thickness. One surface is dark brown in color and covered by fibrous tabs. The reverse surface is gray in color and likewise covered by tiny fibrous shreds. On section, the tissue cuts with some difficulty and seems to be composed of dense, grayish, fibrous tissue.

Microscopic.—A relatively anuclear fibrous connective tissue forms the major portion of the cyst wall. Many small lymphocytes are found in the interstices between the fibres. Covering one surface is a dense network of fibrin and enmeshed within it may be seen numerous polymorphonuclear leucocytes and a few small lymphocytes. Within the wall proper, a small amount of hemosiderin is found.

Diagnosis.—Cyst of liver (infected).

The studies of the cyst fluid proved most interesting and the study of the mycology in this case, together with that of a cyst of the pancreas in a second patient and that of a very remarkable cystic condition of the pleura in a third patient, with animal experiments now under way, will be reported in full at a later date by Doctor O'Connor.

At present it may be stated that the cyst fluids have all been sterile to ordinary culture media for bacteria. They contained a vegetable or yeast-like

MYCOTIC CYSTS OF THE LIVER

organism, having some of the characteristics of the saccharomyces. But they appear to be a distinctive variety hitherto undescribed as a pathogen in man.

The patient continued to pour out large amounts of the glairy colorless fluid for some six weeks, when the sinus had narrowed down to a track. This on injection with sodium iodide was reported as follows:

X-ray Examination of the Abdomen, October 30, 1928.—Stereoscopic films of the abdomen with the patient supine, after the injection of sodium iodide into a sinus, shows the opaque material extending upward and to the right, apparently to a point beneath the anterior surface of the liver, relatively near the lateral abdominal wall. It is extremely difficult to tell whether the material goes into the liver or not. Assuming that the anterior margin of the liver is lower than the posterior it apparently does enter the liver itself. The margins of the shadow of the opaque material are very irregular. It seems to send projections off from the main channel upward and to the left. It is much wider about half-way from the sinus opening to the distal end of the channel than elsewhere. The channel seems to lie anterior to the hepatic flexure. A lateral view seems to show the channel extending straight backward, and its tip overlies the shadow of the liver. I still am not absolutely sure whether the opening enters the liver itself.

Because of the effect of iodides on blastomyces and actinomyces she was given large doses of potassium iodide and the cyst cavity was irrigated with weak iodine solution. Smears from the exudate showed that the vegetable organisms had largely disappeared, although they could be grown on Sabouraud's culture medium even when the cyst had decreased to a sinus tract. The child was discharged afebrile on the fifty-eighth day with a small sinus track.

Nine days later she returned complaining of pain and tenderness in her right upper quadrant and fever of two days' duration. She had felt well for a week after leaving the hospital. On admission her temperature was 104, pulse 140, and respirations 22. The child was evidently sick and in pain. She showed no jaundice or rash. Examination was negative save for the abdomen which was distended. The patient tends to tip body to the right as she lies in bed, and this gives a prominent bulge over the entire left side of the abdomen. In the right upper quadrant is a granulating wound three by six centimetres with a narrow sinus track about three millimetres in diameter, and which extends down into the liver substance about eight centimetres. A small amount of discharge of a cloudy, reddened nature comes from this with a few small, whitish particles that look like fibrin. The abdomen bulges slightly to the right and just above this granulating area, and is markedly tender just lateral to it. Liver percusses down to level of umbilicus. Marked tympany over left and lower abdomen. Liver felt at level of umbilicus. No other organs or masses felt. No herniæ.

Laboratory Findings.—Red blood cells 3,600,000, hæmoglobin 60 per cent., white blood cells 14,000, polymorphonuclear leucocytes 72, lymphocytes 28. Blood culture—no growth.

She was observed for four days with elevated temperature and because of bulging right flank and right upper quadrant she was reoperated upon December 15, 1928. The findings proved most interesting in the light of the previous findings and the pathology of these peculiar mycotic lesions.

Situated in the anterior aspect of the enlarged right lobe of the liver, but below and to the outer side of the site of the previously evacuated cyst, was found a small cyst about one centimetre below the liver surface and about three centimetres in diameter. This cavity contained several cubic centimetres of a yellowish, thick fluid resembling pus. Situated beneath and posterior to this cavity was a second much larger cavity containing about 800 cubic centimetres of thin, turbid fluid.

Both these cavities had a distinct membrane or cyst-like wall which had much the same characteristics of the thick wall encountered at the first operation. So firm and thick were these walls that they offered a very real resistance to the insertion of the exploring needle. No bleeding and no bile was encountered in either one of these cavities. No free cysts or scolices were found in either cavity.

Procedure.—An eight-centimetre incision was made one centimetre below and parallel to the right costal margin down through the peritoneum and to the free liver surface. The peritoneum was walled off by iodoform gauze, leaving a free surface of liver. This was punctured in an upward and backward direction for a distance of one centimetre when the pus-like fluid was evacuated. This cavity was then opened, a portion of wall removed for biopsy, and the exploring needle was then passed through the bed of this first cavity into the second larger one with the evacuation of the clear fluid mentioned. A large rubber tube was then inserted into the deeper larger cavity and this with the packing were brought out through the wound. The tube was sutured into the skin edges. Dry dressing.

The pathological examination of the cyst walls and the contents showed the same findings as at the first operation.

The large cavity decreased in size again, narrowing down to a track, but on her twenty-fourth day, after some temperature, she discharged a large amount of the same glairy fluid. After injection of this tract with sodium iodide X-ray examination of abdomen was reported as follows:

X-ray Examination of Abdomen, February 1, 1929.—Films of the abdomen taken in the lateral position, and stereoscopic films in the anteroposterior position, shows the opaque solution to be situated in the medial and anterior aspect of the liver region. A portion of the opaque solution extends upward through a narrow channel into the anterior central portion of the liver. The outer cavity measures about eight centimetres across, and five centimetres in the anteroposterior plane. Under the fluoroscope the solution injected into the lower sinus was seen to fill another cavity, which was situated somewhat below and posterior to this upper larger one. No communication was found between them.

The child is still draining and the prognosis is problematical.

This case is reported to call attention to the cysts occurring in the solid organs and in the serous cavities that on ordinary culture prove sterile. We feel sure that many of these so-called sterile cysts or abscesses are of mycotic origin and that if the contents are carefully examined microscopically mycotic bodies will be found. A full report on this case and the cases with pancreatic and thoracic cysts from the standpoint of their mycology, animal inoculations and clinical features will appear at a later date.

DR. WALTER M. BRICKNER, of New York, said that at the last meeting of the New York Surgical Society he had presented a woman with mycotic ulcers of the leg and mycotic pyarthrosis of the knee which later recovered promptly after irrigation of the joint.

DR. JOHN SPEESE, of Philadelphia, said that Doctor Whipple's case called attention to the necessity for more careful and thorough cultural and microscopic studies in cases in which the focus of infection is difficult to demonstrate. Every surgeon has seen abscesses and other conditions in which some type of infection has seemed almost a certainty, and the laboratory report is returned as negative. This suggests, in some instances, that types of infection similar to the one reported by Doctor Whipple may have existed. While the echino-

SAFETY IN RESECTION OF THE STOMACH

coccus produces the most common form of parasitic cyst found in the liver in the human, other intestinal parasites may gain access to the liver and form cysts. In some of these cases, degeneration of the parasite had made it difficult to ascertain its exact nature, but this is not the case in the echinococcic cysts. The age of Doctor Whipple's patient suggests the possibility of congenital cystic disease which may involve the liver, pancreas or kidneys. In the cystic diathesis, however, the cysts are multiple and comparatively small in size.

DOCTOR WHIPPLE, in closing the discussion, said that because of the effect of iodine on mycoses this child was put on heavy doses of potassium iodide and the cyst had been irrigated with a weak iodide solution. In some cultures subsequently the organisms had disappeared, but later on they reappeared which makes the prognosis problematical.

FACTORS OF SAFETY IN RESECTION OF THE STOMACH FOR GASTRODUODENAL ULCERS

DR. RICHARD LEWISOHN read a paper with the above title, for which see page 69.

DR. GEORGE P. MULLER, of Philadelphia, noted that Doctor Lewisohn did not lay stress upon gastrectomy as a treatment for duodenal ulcer. Doctor Muller feels that in view of the fact that at least 80 per cent. of patients with gastro-enterostomy for duodenal ulcer enjoy good health and freedom from symptoms, the major operation should not be attempted routinely unless the surgeons are in a position to do a great many of these operations and thus operate with a mortality as low as that of gastro-enterostomy. Except for the complete cutting off of food traffic through the pylorus, the operation does not seem to have a good physiological basis.

The speaker prefers to subject a small percentage of patients to second operation rather than to perform gastrectomies upon the entire group. In several patients who have had recurrence of hæmorrhage from duodenal ulcer after gastro-enterostomy, he has had excellent results by completing a Billroth No. 2 operation at a second stage.

On the other hand, this figure agrees with Doctor Lewisohn's, in showing that pyloric ulcers and those involving the lesser curvature and antrum are proper subjects for primary resection. As a matter of fact, the speaker believes that all cases of gastric ulcer should be subjected to radical excision because no one clinically, röntgenly, or at operation can definitely exclude cancer in the case supposedly suffering from ulcer.

The speaker finds the greatest difficulty in attempting gastrectomy in cases of ulcer high up on the posterior curvature and frequently he must be satisfied with an excision, followed by a gastro-enterostomy.

All of these operations are dependent upon attention to the factors of safety for a low mortality. In the case of duodenal ulcer a correct diagnosis is a most essential factor. In the case of ulcer in the region of the pylorus, recognition of retention or obstruction is essential because such patients should be properly treated for a number of days before operation in order to lessen the effect of starvation, loss of chlorides and anæmia. Hence, gastric lavage, free use of salt solution with glucose and blood transfusion are essential.

RECONSTRUCTION OF COMMON DUCT. NEW PROCEDURE

DR. EUGENE H. POOL, of New York, said that the numerous operations which have been attempted for the correction of a stenosed common duct are

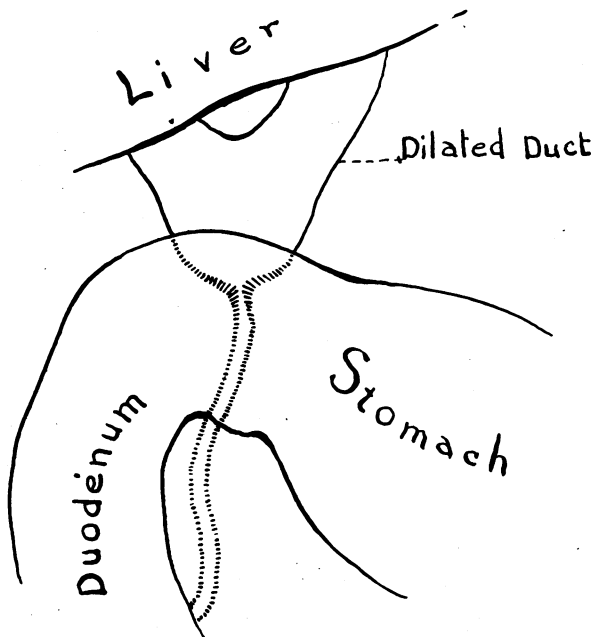


FIG. 1.—Diagrammatic representation of dilated duct or bile reservoir above obstruction of common duct and its relation to the duodenum.

all very serious procedures attended by high mortality and a large percentage of functional failures. It is unnecessary to review these procedures. The method which is to be described is the result of an attempt to find a simple and safe means of reestablishing a stenosed common duct, in cases where the gall-bladder has been removed.

The anatomical conditions in such cases are as follows:

First.—The common and hepatic ducts above the obstruction are enormously dilated forming a real bile reservoir.

Second.—The duodenum is usually high, close to the liver and close to the dilated duct above the stricture.

Third.—These structures are buried and united in a mass of solid adhesions.

The usual operations demand extensive dissection of the adhesions so as to expose the bile reservoir and displace the duodenum. After this prolonged dissection an anastomosis is made, the parts being brought together in much the same position in which they had been, and, to protect against leakage, an effort is made to reproduce the protective adhesions by apposition of omentum, etc.

His suggestion is to leave the structures in proximity and to leave the protective adhesions, to open the duodenum and do an internal choledocho-enterostomy. Such an operation should be simple, and short, with little danger of leakage. This is intended as a suggestion only; the technical details have not been worked out and perfected. Perhaps it will be impossible to do so. Yet in the one case in which the procedure has been attempted the results are promising. He therefore presented it for discussion.

A colored housewife, thirty-two years of age, entered the New York Hospital January 9, 1928, for relief of jaundice. Since 1911 she had been subject

RECONSTRUCTION OF COMMON DUCT

to frequent attacks of epigastric pain associated with jaundice. In 1927 the gall-bladder had been removed. After operation the pain and jaundice were relieved for five weeks. A swelling then appeared near the scar and jaundice recurred. The swelling burst, and bile was discharged, causing disappearance of the jaundice. Then the sinus closed and jaundice once more returned.

In October, 1927, the patient was operated upon for these symptoms. The operator reports that he found a severed common bile duct which he drained. A biliary sinus developed and the jaundice persisted. With this history the patient was admitted to the New York Hospital, January, 1928. She was a thin, colored woman, looking chronically sick and deeply jaundiced. The abdomen showed a sinus in the right upper quadrant from which bile was discharging. The icterus index was 39.0. Blood Wassermann negative. The urine showed much bile. Stools were light in color.

January 16, 1928, choledocho-enterostomy was performed. Anæsthesia—Ethylene-ether. *Incision.*—Right epigastric mesial to the former scar. Duodenum identified but not dissected free. One and one-quarter inches from pylorus a transverse incision was

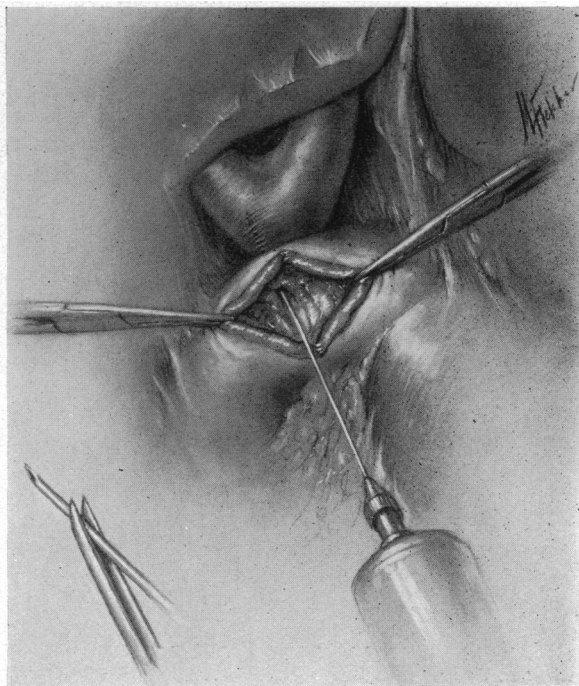


FIG. 2.—Aspirating needle introduced through duodenal wall into bile reservoir.

made in duodenum. A small aspirating needle was introduced upward through upper wall of duodenum, and blood was obtained. The needle was then passed upward and slightly outward and bile was obtained. (Fig. 2.) Methylene blue was injected and a clamp was passed along the needle and the orifice stretched, methylene blue coming out through the opening into the duodenum. Duodenal incision closed from above downward with three rows of chromic. Omentum sutured over this. Wound closed in layers without drainage.

The post-operative course was uneventful. The wound healed by primary union and the sinus remained closed.

She felt well for six months following discharge. Then afternoon temperature began, accompanied by increasing jaundice and occasional clay-colored stools; also loss of weight and gastric distress.

In spite of the ultimate failure of this operation Doctor Pool felt somewhat encouraged. In the first place, the fistula closed, and although there was at first no pressure of bile from above on account of the fistula, the stoma functioned for some months. Second, the operation was too conservative. As in any new procedure one is apt to feel one's way uncertainly and as a result the new opening was not made sufficiently large.

She was readmitted to the New York Hospital November 13, 1928, deeply jaundiced. The urine contained bile, while the stool showed only a trace. Icterus index was 62.0.

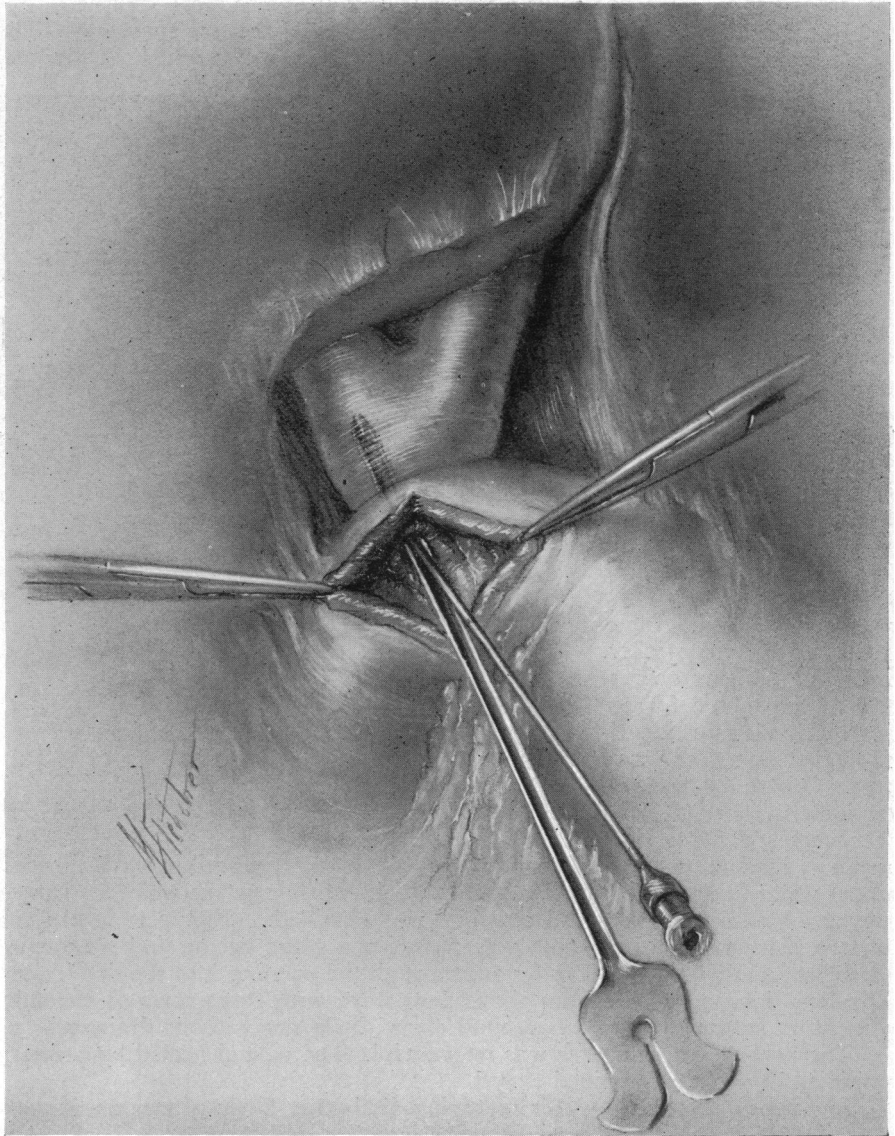


FIG. 3.—Grooved director passed along needle.

Operation November 26, 1928. Anæsthesia—Ethylene-ether. *Incision.*—Right upper rectus excising the old scar. The duodenum was found to be closely adherent to the inferior surface of the liver. The adhesions were not detached. A vertical incision was made in the anterior aspect of the first portion of the duodenum. An aspirating needle was inserted through the superior

RECONSTRUCTION OF COMMON DUCT

wall of the duodenum toward the liver. At first blood only was obtained. The needle was withdrawn and directed upward and slightly outward. This time pale greenish-colored fluid was obtained. Leaving the needle in place a specially prepared grooved director was introduced along the aspirating needle

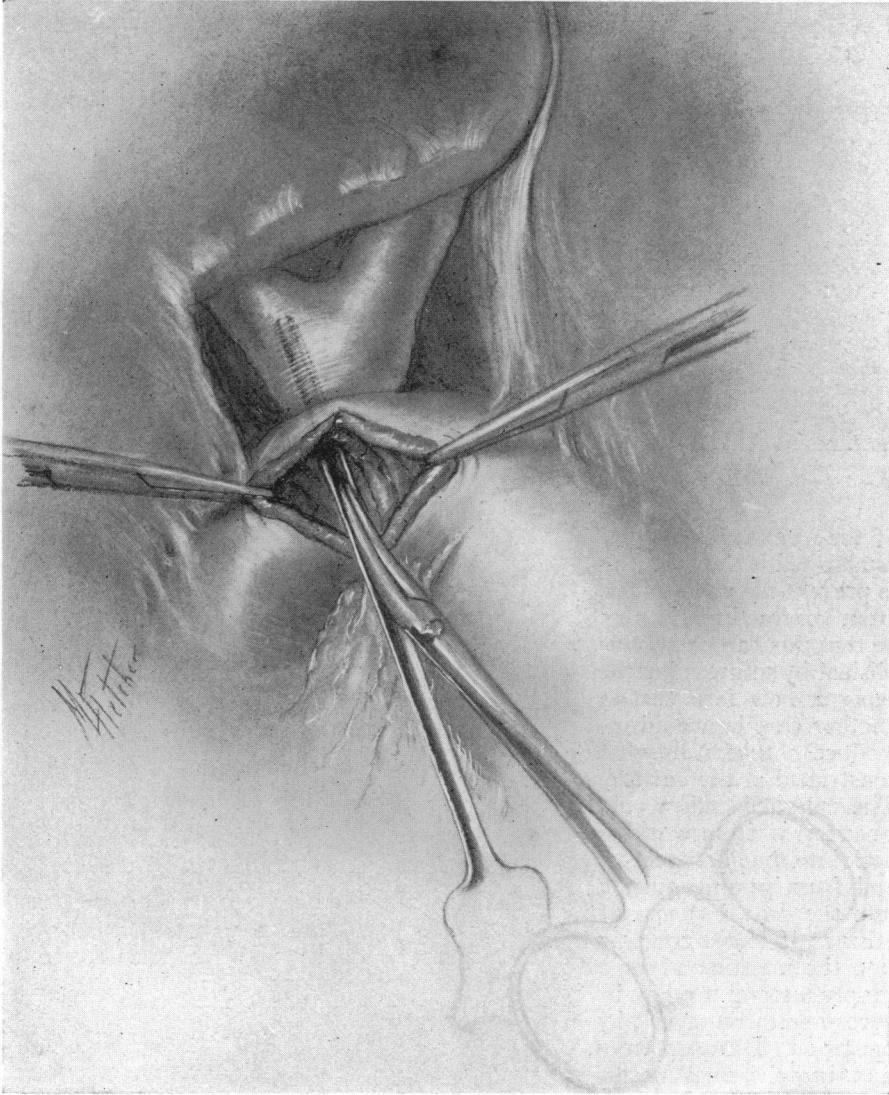


FIG. 4.—Artery clamp passed along grooved director.

through the superior wall of the duodenum into the bile reservoir. (Fig. 3.) There was a gush of bile and some purulent fluid. An artery clamp was passed along the grooved director and the orifice stretched. (Fig. 4.) A No. 26 French catheter four centimetres in length was introduced through the opening in the duodenum into the bile reservoir. (Fig. 5.) This was fixed with one catgut suture. The opening in the duodenum was then carefully repaired with two layers of catgut. The wound was closed. (Fig. 6.)

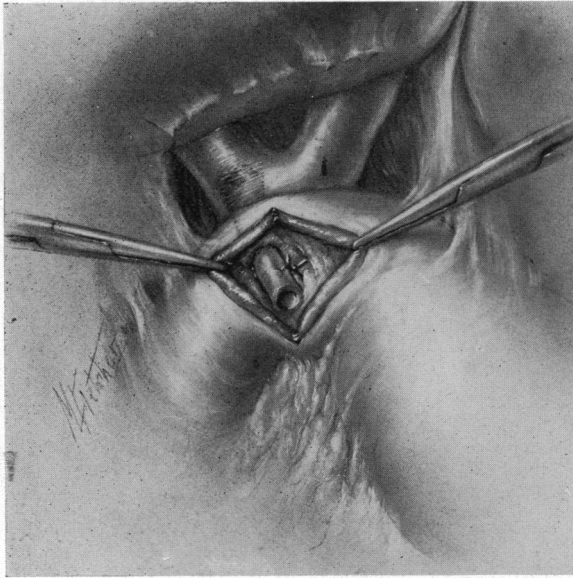


FIG. 5.—Tube in place.

The post-operative course was smooth. The wound healed by primary union. The jaundice disappeared and by the time of discharge the urine was free of bile, the stools were normal in color and the icterus index had fallen to 16.0. The tube was passed per rectum on the eighth day. The general condition of the patient was rendered quite normal. She was discharged on the sixteenth day. At present, about three months after operation, her condition is normal, weight has increased twenty pounds, icterus index 11.

The technical feature

of the operation not yet established is the best way to prevent the anastomosis from contracting. It may be that this can be accomplished by sutures; but the reporter now feels that in another case he would introduce a tube somewhat constricted at the centre. The enlarged ends would prevent it from working back into the bile reservoir and from passing quickly into the duodenum. Of course if it did not pass into the intestine after a proper interval it might be necessary to remove it by operation. Danger from passing the small needle into the portal vein seems negligible. Apparently this was done at each operation without harm. Moreover, with the knowledge that the needle must be passed somewhat laterally and not directly upward, this embarrassment can probably be avoided in a subsequent case.

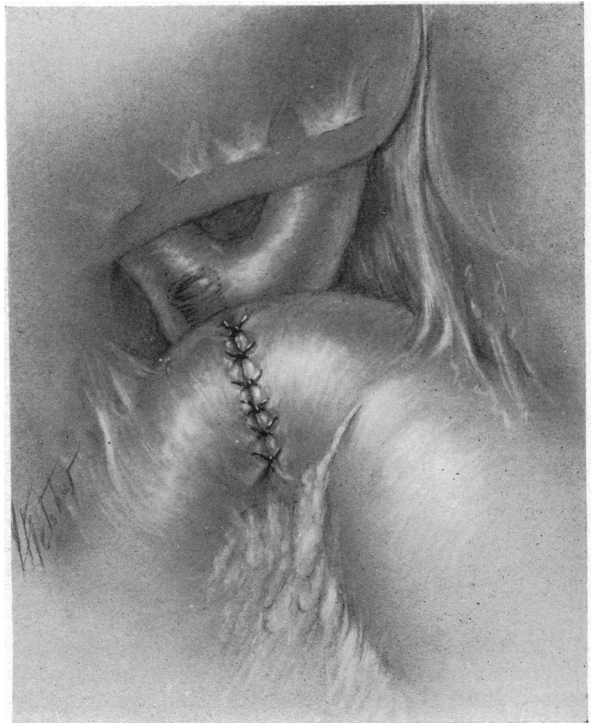


FIG. 6.—Duodenal incision sutured.

RECONSTRUCTION OF COMMON DUCT

DR. EDWARD J. KLOPP, of Philadelphia, said that on one occasion he was obliged to anastomose the common hepatic duct with the duodenum following an operation early in 1925, when the gall-bladder was removed and the operating surgeon injured the common duct causing occlusion of the duct. Two months later he was reoperated and again occlusion of the duct followed. Late in 1925 the man came under Doctor Klopp's observation. He was then markedly jaundiced with enormous swelling in the upper abdomen. An interne made a nick in the skin and evacuated bile. After several weeks an attempt was made to relieve the constriction of the duct. A T-tube was inserted in the common duct extending into the duodenum. The man made a nice recovery and remained free from jaundice for three months, and then becoming jaundiced again returned for relief. At the operation the distal portion of the common duct was found to be replaced by scar tissue. It was impossible to anastomose the duodenum with the proximal portion of the common duct. Fortunately the common duct opening into the duodenum was found and a No. 10 catheter passed through it into the duodenum. Having failed previously to permanently establish the common duct it was decided to implant a larger catheter, whereupon a No. 24 catheter was selected. It was impossible to pass it through the duct opening even after dilatation with a duct forceps. The duodenum was opened following the suggestion of Duval and Richard, the papilla dilated with duct-stone forceps. Even though they were unable to insert a No. 24 catheter the No. 10 was passed. The eye end of the No. 24 catheter was sutured in the funnel end of the No. 10. In that manner the larger catheter was passed without difficulty. The funnel end of the large catheter was placed in the proximal portion of the common duct; approximately four inches of the eye end of the catheter was cut off, and the catheter passed on down into the duodenum and the incision was closed. Omental structure in the vicinity of the duct was sutured over the reconstructed duct. The abdominal wound was closed with a Penrose drain. There was leakage of bile for the first five days following the operation, when it suddenly ceased and the wound promptly closed.

The man is now in fairly good health, working every day. A recent X-ray shows the tube approximately as it was placed in May, 1925. About a year ago he presented this case at the Philadelphia Academy of Surgery. He suggested then that it might be well to consider removal of the tube. Doctor Deaver remarked that he had a patient in whom he had used a short tube in an obstruction of the common duct and allowed it to remain five years when it was passed spontaneously. It is astonishing how long a foreign body can remain in a patient with little discomfort.

DR. CHARLES F. NASSAU, of Philadelphia, said that about seven years ago a patient came under his care who had a gall-bladder removed. The patient had jaundice and fever when he came to the speaker. After an operation which was extremely difficult and prolonged both ends of the common duct were exposed. The scar tissue was removed and the remaining portion of the duct was found to be normal. A piece of catheter was inserted to bridge the

gap between the ends of the duct which were about one inch apart. An omental graft was placed over the tube and the patient had no difficulty or recurrence of jaundice for about six years, at which time he died of carcinoma of the stomach. The operation was never reported but there is in existence an X-ray taken about three years after the operation which showed the tube *in situ*.

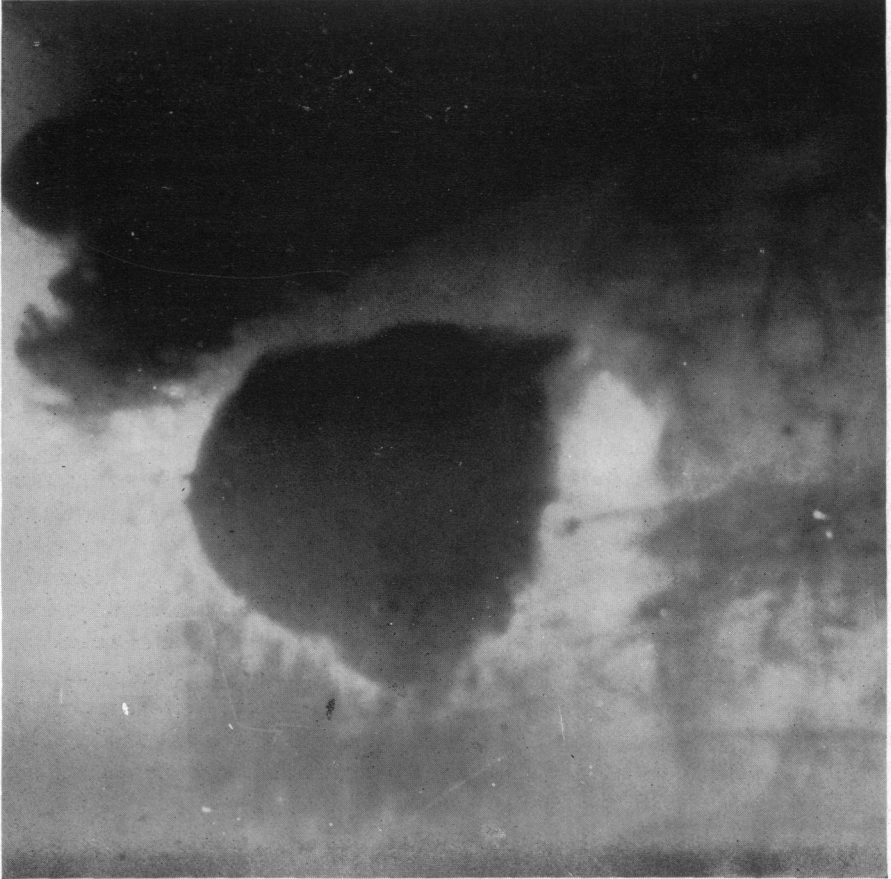


FIG. 7.—Diverticulum of duodenum.

DIVERTICULUM OF DUODENUM

DR. EUGENE H. POOL presented a woman, sixty-two years of age, who was admitted to the New York Hospital, October 23, 1928, because of repeated attacks of vomiting which had occurred for two and one-half years. First attack was in May, 1926. At that time she vomited green mucous material, no blood. Vomiting continued for one week. She had another attack of vomiting four months later lasting for several days and another attack the following month which lasted only one day.

There followed a period during which she was well. She then had three similar attacks in November and December, 1927, and one in June, 1928. Each attack of vomiting was preceded by belching gas and epigastric distress. Following the attacks she lost her appetite and felt exhausted for several weeks.

DIVERTICULUM OF DUODENUM

Dr. Walter Niles, who saw her first in June, 1928, reports that June 14, 1928, her urine contained a large amount of sugar, as well as a marked reaction for acetone. There was no diacetic acid; there was a faint trace of albumin and numerous hyaline and granular casts. On June 15 her blood sugar was 186 milligrams per 100 cubic centimetres of blood; June 16 her blood chemistry was as follows:

Urea Nitrogen	18.		mgms. per 100 c.c. of blood
Non-protein Nitrogen ..	35.6		mgms. per 100 c.c. of blood
Uric Acid	4.4		mgms. per 100 c.c. of blood
Sugar	136.95		mgms. per 100 c.c. of blood
Chlorides	468.75		mgms. per 100 c.c. of blood
Creatinin	1.879		mgms. per 100 c.c. of blood

June 17 and succeeding days there was no glycosuria.

Her next attack began on September 27, 1928. There was again a large amount of sugar in the urine, with considerable acetone and diacetic acid. The sugar persisted for four days, although the acid bodies disappeared in two days. Her blood sugar on September 28, 1928, was 198.

Fæcal examinations made during the attacks showed large amounts of mucus and many undigested starch cells. There were no other evidences of pancreatic insufficiency. Lost twenty-five pounds during past two and one-half years.

February 13, the abdomen was opened. Adhesions were freed between the gall-bladder and the duodenum. The colon was displaced downward and the duodenum mobilized. The duodenum and head of pancreas

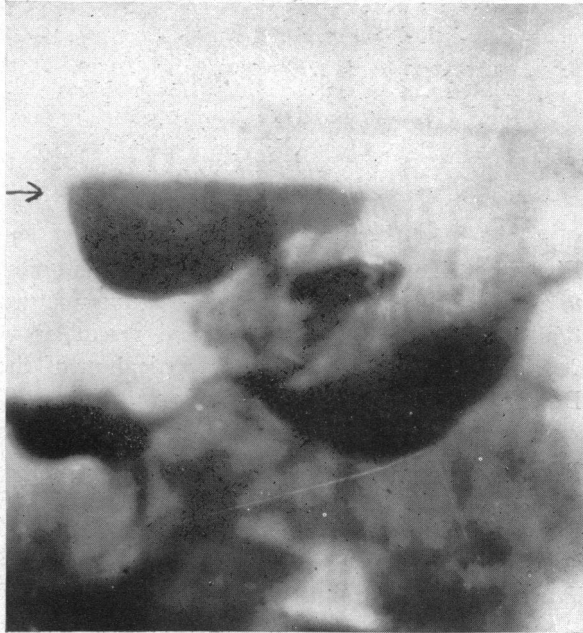

FIG. 8.—Diverticulum of duodenum showing fluid level.

were then lifted mesially like a trapdoor. The diverticulum was then identified closely opposed to the posterior aspect of the head of the pancreas. It was collapsed but measured about two inches in diameter. It was, of course, retroperitoneal. Four or five large thin-walled veins lay on its surface. These were ligated and divided. The sac was then readily dissected free. Its wall was very thin; its neck two centimetres in diameter was situated at the lower part of the mesial aspect of the descending duodenum. The diverticulum was excised a short distance from the duodenum. The orifice was repaired transversely with three rows of chromic gut. Extreme care and thoroughness were necessary on account of the inaccessibility and the retroperitoneal position. When the repair was completed it was felt that the lumen of the duodenum was so

much encroached upon that obstruction might occur. Therefore a posterior gastrojejunostomy was done. The wound was closed without drainage.

Post-operative course entirely smooth. Patient discharged twenty-one days after operation. She has had no further complaints, eats everything, general health good. No sugar has been noted in the urine. February 3, 1929, blood sugar 125 milligrams per 100 cubic centimetres of blood.

DOCTOR POOL thought this case to be of interest, first, on account of the unusual situation of a large diverticulum; it lay posterior to the head of the

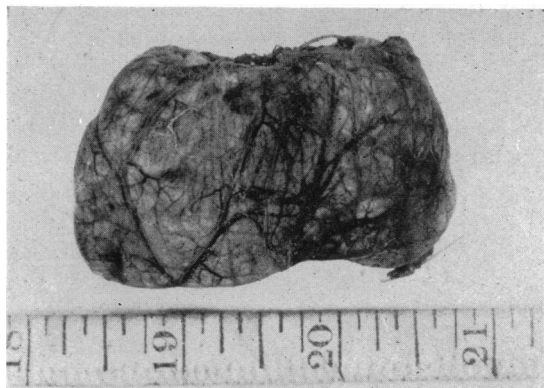

FIG. 9.—Diverticulum of duodenum, excised.

pancreas. Second, because of the peculiar symptoms, notable periodic attacks of vomiting with hyperglycæmia and glycosuria presumably due to pressure by the dilated diverticulum upon the pancreas or its duct. Third, these disturbances were cured by operation.

DR. JOHN H. GIBBON, of Philadelphia, said that there were three types of diverticulum of the œsophagus.

First, that due to perforating ulcer which is quite common. Second, that due to a probable congenital defect in the musculature which results in a herniation of the mucous membrane, and resembles very closely, he thought, in development and pathology, a diverticulum of the œsophagus. To this class Doctor Pool's case belongs. Of this class Doctor Gibbon has seen no case.

The third type resembles the Meckel's diverticulum found usually in other parts of the small intestine. Slides were then shown illustrating an unusual case of the latter type which was operated upon at a meeting of the Clinical Society of Surgery at the Pennsylvania Hospital last fall. The diverticulum in this case was very long, and when filled with barium, changed its shape, indicating a definite musculature. On opening the abdomen the diverticulum, about the size and shape of a thumb, came off from the anterior wall of the duodenum, and the communication between the diverticulum and the bowel corresponded to the width of the former. The extremity of the diverticulum was free, which accounted for the different positions in which it was seen in the X-ray plates. Its removal, of course, was a simple matter. Doctor Pool's case was a very much more serious one, and one in which successful removal was very much more difficult.

DR. FRANK S. MATHEWS referred to a case, somewhat like Doctor Pool's, in which, in advance of operation, he thought he was dealing with a case of common-duct stone. The X-ray showed a shadow to the left of the duodenum which was interpreted as indicating that bismuth entered the common duct. At operation the common duct was drained, but there were no stones. At

SPREAD OF BACTERIA

autopsy the patient was found to have multiple abscesses in the pancreas. A diverticulum of the duodenum, apparently congenital, lay in contact with the pancreas and opening beside the common duct. It was thought that this diverticulum might be related etiologically to the suppurative pancreatitis.

THE SPREAD OF BACTERIA FROM THE GALL-BLADDER TO THE LIVER

DR. WALTON MARTIN read a paper with the above title, for which see page 47.

DR. I. S. RAVDIN, of Philadelphia, said that he was in Edinburgh at the time that Dr. A. L. Wilkie did his work. There were several very interesting factors in connection with it. In the first place, in the majority of instances in which the bile was cultured, it was found to be sterile. When a culture was made of the wall of the gall-bladder with the mucosa intact, it was practically always sterile, but when the mucosa was removed in a large number of instances Doctor Wilkie was able to obtain a positive culture which coincided with the culture he obtained from the cystic lymph gland. The organism which he recovered he believed to be similar to the Rosenau streptococcus which has a "specific affinity" for the gall-bladder. Whether the gall-bladder is primarily infected, or is infected secondary to hepatitis is questionable. It is definitely known that hepatitis may result from cholecystitis and that the reverse process may likewise take place. Whether the mechanism of the infection is lymphatic in its origin is questionable. It is exceedingly difficult to demonstrate a continuation of the gall-bladder lymphatics into the liver substance.

Doctor Ravdin has tried this by three methods—the use of colloids, by air injections of the lymphatics, and by the use of carbon particles. Although the gall-bladder lymphatics fill out exceedingly well, and the material enters the glands around the head of the pancreas, one does not find them passing back into the liver. It appeared to him that although there is no doubt of the relationship between hepatitis and cholecystitis, that it has not been shown beyond any doubt that this connection is lymphogenous.