

TRANSACTIONS
OF THE
PHILADELPHIA ACADEMY OF SURGERY

Stated Meeting, held December 4, 1916

The President, DR. CHARLES H. FRAZIER, in the Chair

SUBPERITONEAL HEMORRHAGE, RESULT OF PURPURA
HÆMORRHAGICA SIMULATING APPENDICITIS

DR. I. M. BOYKIN reported the history of a boy, aged six years, who was admitted to the Episcopal Hospital August 21, 1916, supposedly suffering from an appendiceal abscess. His previous general health had been good up to three days before admission, when he began to complain of severe pain in the abdomen, with vomiting. The child was kept in bed until the third day, when the family physician made the diagnosis of appendicitis and on his recommendation the child was brought to the hospital.

After admission he lay in bed with his right thigh acutely flexed on the abdomen and the member could not be extended without agonizing pain. There was a decided pallor. Just above Poupart's ligament on the right side was a mass, well defined and tender. There was slight rigidity of the right side of the abdomen, the left side seemed normal. In the left anterior tibial region were two ecchymotic spots about the size of a dime, which were presumed to be bruises.

Reflexes normal. Temperature 101°, pulse 100, respirations 28, leucocytes 14,000. The history and the data elicited by examination were in favor of an appendiceal abscess.

The child was taken directly to the operating room and under ether anæsthesia an incision made over the top of the mass. The blood that flowed into the skin incision was very dark. The abdominal muscles were almost black. The peritoneum was opened and the appendix presented in the wound, apparently normal. The peritoneal fluid was in excess and slightly blood tinged. The mass, which was felt through the abdominal wall, was found to be retroperitoneal and to consist of a blood clot. The patient's condition would not permit further investigation, so a cigarette drain was inserted and the abdomen closed. The patient died the same evening without reacting.

Several hours before death it was noticed that, in addition to the two ecchymotic spots on the left tibia, there were many others on the

AVULSION OF LESSER TROCHANTER OF FEMUR

lower extremities and also on the abdomen in the region of the wound.

A postmortem could not be obtained, but the wound was reopened and enlarged. Unsatisfactory as it was, the following important points were noted: Wherever the intestines were touched at time of operation there were ecchymotic spots, almost corresponding to finger prints. There was a retroperitoneal blood clot, extending from Poupart's ligament to the upper pole of the right kidney. The peritoneum was adherent to clot at a point corresponding to that of the patient's pain. The clot was removed and the ruptured vessel looked for but none was found. Both kidneys were taken out and incised. In the cortex and medullary portions of both were found small hemorrhages; a blood clot was found in the pelvis of both.

AVULSION OF THE LESSER TROCHANTER OF THE FEMUR (EPIPHYSIAL SEPARATION)

DR. GEORGE G. ROSS related the history of a boy, fifteen years of age, who, on June 24, 1916, while playing baseball, received an injury to his upper right thigh. He struck a ball and started to run for first base; after the third stride he fell to the ground. The pain, which was in the right groin, was severe and prevented walking, as attempts at flexion of the thigh on the body markedly increased the pain. He could stand with fair comfort and was relieved when the limb was in flexion and adduction. On attempting movement he said it felt as though there was a marble in his groin. Passive motion did not cause pain. There was tenderness on deep pressure both over Scarpa's triangle and on the posterior surface of the thigh. There was no ecchymosis or swelling. Dr. Kelly, of the Germantown Hospital, who brought him to the hospital, found him lying on his left side with the right thigh semiflexed and adducted.

One year prior to the present accident, the patient was butted in the right groin by another boy's head, causing him to fall backward. He had severe pain in the right groin which he said felt like a muscle bruise. He limped for a week and felt a grating sensation for some months and was unable to take exercise due to soreness and inability to lift the thigh. Pain was relieved by recumbency. Later he was able to take exercise and felt no discomfort. He said that the day before his second accident he felt some soreness in the groin with some interference with flexion.

The patient had had measles, chicken-pox, mumps, pertussis, but never had tonsillitis. His family history was negative, except for one uncle who has tuberculosis, but this uncle does not live in the same house with the patient.

PHILADELPHIA ACADEMY OF SURGERY

Dr. Kelly made a diagnosis of tearing of the iliopsoas muscle attachment. X-ray picture showed a separation of the lesser trochanter of the right femur without other fracture.

From the history of this case it is difficult to say whether the separation of the lesser trochanter occurred at the primary traumatism of a year ago from direct violence or at the second accident when the exciting force was applied by the pull of the iliopsoas muscle. It seems probable that the injury followed the first trauma and recurred at the second injury.

The condition was met by placing the limb in a plaster case in a position of semiflexion and extreme adduction. This at once relieved his pain. After three weeks the case was removed and the patient given massage and passive motion. At the present writing the patient uses the limb without discomfort or any limitation of function.

HUTCHINSON (*British Med. Jour.*, December 30, 1893, p. 671) reports a case of Fenwick's in a boy of seventeen, who leaped from a fence and fell backward, breaking off the lesser trochanter, apparently by the pull of the psoas iliacus. This was verified by incision. The patient died of septicæmia on the seventeenth day.

JULLIARD (*Progrès Méd.*, 1879, vii, p. 825) reports a case of a man, eighty-two years of age, who was injured by falling as he rose from bed. He suffered from marked pain, eversion, and disability until death. The autopsy showed a large extravasation of blood in the muscles. The joint and neck of the femur were intact and the lesser trochanter was broken off and adherent only by a strip of periosteum. There was, however, a small area at the upper extremity of the femur which showed sarcomatous degeneration.

ASHHURST (*Surgery, Its Principle and Practice*, 1914, p. 368) mentions eight cases, collected by Binet and Hamant (1911), of isolated fracture of the lesser trochanter, and says that isolated fracture of the great trochanter occurs and may require periosteal suture to maintain reduction.

METCALF (*Jour. of Amer. Med. Asso.*, 1915, lxiv, 1234) collected fifteen cases since 1854. This list includes the eight cases collected by Binet and Hamant in 1911. Metcalf does not include the case of Fenwick's reported by Hutchinson as mentioned above. This would make the total sixteen up to 1914. Metcalf reports two cases from his personal experience. This brings the total up to eighteen cases to 1914. Since that time I have been unable to find any reports of such cases and my own case would bring the total up to nineteen.

Fracture of the lesser trochanter complicating other injuries to the femur is not an uncommon occurrence. Ashhurst (*ANNALS OF SURGERY*, 1913, lviii, 494) mentions six cases admitted to the Episcopal Hospital, Philadelphia, during six months with fracture of the lesser trochanter complicating fracture through the trochanter.

Metcalf's first case in a patient seventeen years of age was due to a bump from a fellow player, causing the right limb to slip suddenly backward. His second case was in a boy of sixteen years, who while running in a football game wheeled quickly to the right to catch a

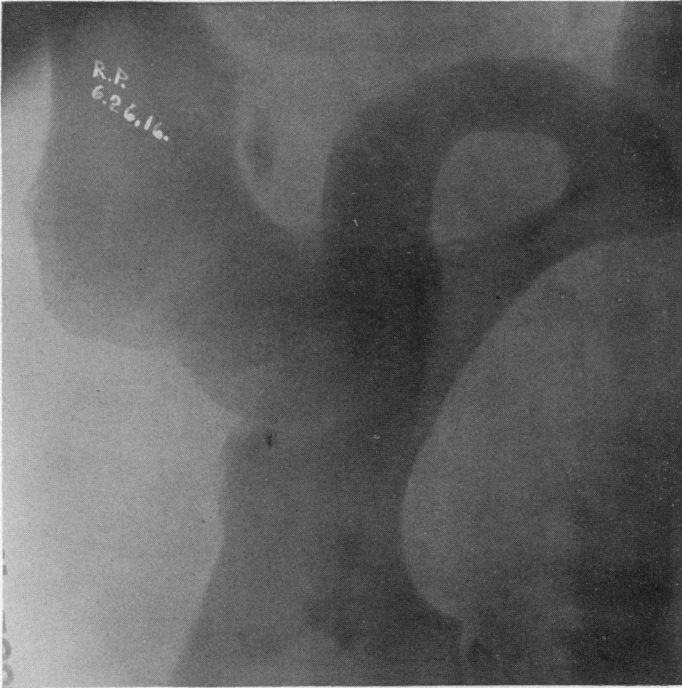

FIG. 1.—Avulsion of lesser trochanter of the femur.

AVULSION OF LESSER TROCHANTER OF FEMUR

forward pass and as he did so his left limb dragged behind in extension and he fell to the ground.

Metcalf gives four symptoms: Pain, slight when quiescent, increased on walking and flexing thigh; other motions little or no effect on pain; tenderness on direct pressure over the lesser trochanter.

In this case flexion was impossible beyond one or two inches. Voluntary flexion caused intense pain. Passive motion did not cause any discomfort. Pain was elicited on pressure over the lesser trochanter, both on the anterior and posterior surface of the thigh.

Loss of function, either partial or complete. Some of the cases were able to walk but stiff-hipped and with discomfort. Loss of function was the observation in most of the cases, although Brunelli's case continued his occupation for a week after the accident. Deformity—Eversion was noted in adults. Chaput's case, aged fifty-two, held his leg in external rotation flexion and abduction. Gray noted external rotation which could, however, be readily overcome. In young persons there seems to be no reported deformity. There certainly was not in this case. The limb was held in adduction and semiflexion to relieve the pain; this was postural and not deformity. In old people there is reported ecchymosis and swelling; here again differing from the younger patient. In Metcalf's cases these signs were absent, as they were in this case. The diagnosis rests therefore on a history of trauma in which the applied force is directed through the iliopsoas muscle to the lesser trochanter and localized pain and tenderness in the groin. Inability to flex the thigh or if flexion is possible it is according to Ludloff's sign. With the patient on the back he can lift his thigh by using the rectus femoris, but is unable to flex the thigh while in a sitting position. Localized swelling and pain may be present or absent according to the age or youth of the patient.

Treatment should be non-operative. As one cannot bring the small fragment down to its normal position on the femur, bring the femur up to meet the fragment and retain in a fixed dressing in semiflexion and adduction.

DR. JOHN H. JOPSON added the history of a boy of sixteen years, whom he saw in consultation with Dr. Girvin, January 9, 1915. On November 10, 1914, while playing football and running after a forward pass, the boy turned to the right and fell with the thighs flexed. He experienced slight pain and a sensation of something giving way in the upper inner region of the thigh, sensation being described by him as similar to that of "putting elbow out." Immediately after the accident he could not use the knee well, but was able to walk home. In the evening, while walking, pain became very severe and interfered with

flexion of the thigh. Dr. Metcalf, physician to the school, had an X-ray taken on the following day which showed apparently partial detachment of the epiphysis of the lesser trochanter. The leg was most comfortable when kept slightly flexed. He was treated with a plaster case for nearly three weeks. There was no localized tenderness or swelling. After the plaster case was removed a leather splint was applied which embraced the thigh and pelvis. When seen January 9, 1915, he had been walking with the splint but without crutches since December 21, 1914. Examination at this time showed nothing except slight atrophy of the thigh muscles. X-ray was taken by Newcomet, which confirmed diagnosis of fracture or avulsion of the lesser trochanter of the femur.

Patient states that a similar case occurred in the same school within a year or two, the boy being injured while playing hockey. This patient also was able to walk around for a few hours after the accident.

DR. HENRY R. WHARTON said that some years ago, before the days of the X-ray, he had a patient admitted to the Children's Hospital, of about ten years of age, who had fallen downstairs and struck at the foot of the stairs with violent separation of the thighs. There was great tenderness on the anterior of the thigh and of the pelvis posteriorly. He imagined there was a muscular lesion. A few days later there was high temperature and an abscess developed in the right groin which was incised. There was found to be separation of the epiphysis of the lesser trochanter. The patient finally made a recovery. Looking up the literature at the time he found the condition to be comparatively rare, and that septic infection was not uncommon.

DR. P. G. SKILLERN, JR., remarked that owing to the low, sessile nature of the lesser trochanter, actual fracture of this process in the adult must be much rarer than its disjunction as an epiphysis during the period of adolescence, or between the ages of eight and nineteen years, the epiphysis appearing at about the eighth year and uniting with the shaft at the nineteenth year. A case has been recorded in which this epiphysis was torn off in a boy of fourteen, as the result of the strain on the iliopsoas in a fall backward on the feet. Death from pyæmia followed. The majority of cases occur in this epiphysial age. Roberts and Kelly cite three cases which occurred in men beyond middle life, in which the injury was due to muscular pull in falling. In one case the patient was run over by an omnibus. The injury is due to the pull of the iliopsoas muscle.

Dr. Ross stated that he dressed the limb in the position of flexion with adduction. It is surprising how much tension may be taken off of the lesser trochanter and relaxation obtained by the manœuvre of

INDICATIONS FOR MOSETIG-MOORHOF BONE-FILLING

external rotation of the limb. This brings the lesser trochanter well forward, and it should be added to Dr. Ross's flexion with adduction, superlative relaxation thus being obtained by flexion, adduction, and external rotation of the thigh.

In the presence of great separation of the lesser trochanter it may be necessary to cut down, overcome the displacement and retain the lesser trochanter or epiphysis *in situ* by means of a bone-peg. Operative access to the lesser trochanter may be had through the inner portion of the floor of Scarpa's triangle, in the interval between the adductor brevis muscle internally and the pectineus externally, the limb being flexed and rotated outward. The incision should be made along the outer border of the adductor longus muscle as a guide. This interval is free from any important vessels, and the only structure of consequence liable to be injured is the obturator nerve, which may be pushed upward with the handle of the scalpel.

INDICATIONS FOR THE USE OF MOSETIG-MOORHOF'S IODOFORM WAX BONE-FILLING

DR. ASTLEY P. C. ASHHURST read a paper with the above title, for which see page 227.

DR. GWILYM G. DAVIS thought that many people had been deterred from using this bone wax because of the difficulty of having it retained, and heal in by primary healing. His experience had been the same as that of Dr. Ashhurst, that in cases in which it does not heal in entirely or in which there has been a certain amount of suppuration, it still seems to have a distinctly good effect in hastening the healing process. In many cases it is practically impossible to close the cavity by depressing the skin from the sides and it is especially useful in this class of cases.

DR. EDWARD B. HODGE had used the wax a good deal and had also felt that while it does not always give a primary cure it has never done any harm, and has always helped in a measure. He had also had success in using the bone wax as a secondary dressing, so to speak. If he could not get the cavity dry at the time of the primary operation he would pack the wound, and when at a subsequent dressing it was found dry, fill the bone cavity with the wax.

DR. ASHHURST, in closing, said that he had tried to sterilize the cavity in various ways—hot air blast, radiations from the actual cautery, carbolic acid, iodine. With none of them can one get perfect sterilization when the cavity was primarily infected. Mosestig-Moorhof laid great stress on having the cavity dry. He would use the hot air blast until the shine of the moisture had vanished.

PHILADELPHIA ACADEMY OF SURGERY

PYLORIC AND DUODENAL ULCER

DR. JOHN B. DEEVER presented a series of lantern slides (see Figs. 2-11). He said his purpose was to elicit views upon the surgical technic in the treatment of these ulcers. Taking up first ulcers of the stomach; we know their most common site is on the posterior wall along the lesser curvature, near the pylorus; next most common site lesser curvature distant to the pylorus and the anterior and posterior walls. The least common site, in the fundus and to the side of the entrance of the œsophagus. When possible all ulcers of the stomach should be excised; this is practically always possible where they occupy either the anterior or posterior wall of the stomach. When the ulcer is on the posterior wall the excision is made transgastrically. When the ulcer is small and on the lesser curvature it can be excised and the stomach walls repaired without interference with its mechanics. Where the ulcer is large and on the lesser curvature, and particularly when of the saddle-back type, involving both walls, central resection with end-to-end union is the operation of choice, a gastro-enterostomy not being necessary, at least he had not found it so. In pyloric ulcer with considerable induration he believed the better practice is to do pylorotomy, at least this is the technic he practised. Ulcers in the fundus and around the œsophageal entrance are practically inoperable, at least those that have come under his observation have been. He believed, however, if these were diagnosed very early by making a gastrotomy in doubtful cases, much can be accomplished.

It is a well recognized fact that duodenal ulcer is more frequent than gastric ulcer. Duodenal ulcer is most often located upon the anterior and lateral wall of the first portion of the duodenum. The next most common site is the posterior wall of this portion of the intestine, and the least common site the inner pancreatic wall of the second portion of the duodenum.

Where the ulcer is small and located upon the anterior wall of the first portion of the duodenum it is his practice to excise it, close the opening in the intestine, plicate the duodenum and make a posterior gastro-enterostomy. When an ulcer in this portion of the intestine is large, but extending short of the head of the pancreas, he amputated the duodenum below the lesion, purse-string it, invert, excise the pylorus, and make a posterior gastro-enterostomy. When the ulcer is on the posterior wall of the first portion of the duodenum and not too adherent to the posterior abdominal wall to permit of freeing the duodenum, he practises the same technic as in large ulcers upon the anterior wall.

When the amputation of the duodenum is made so close to the head

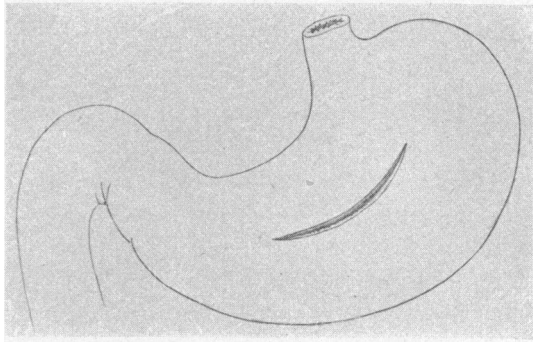


FIG. 2.

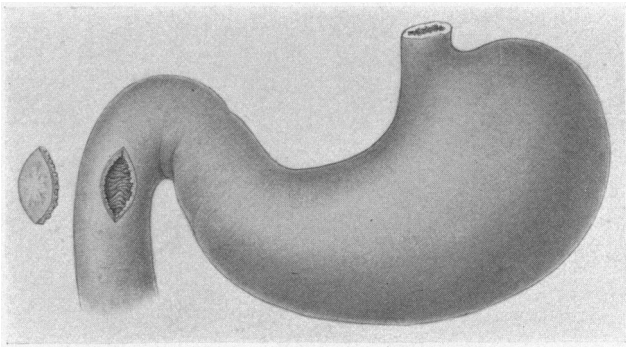


FIG. 3.

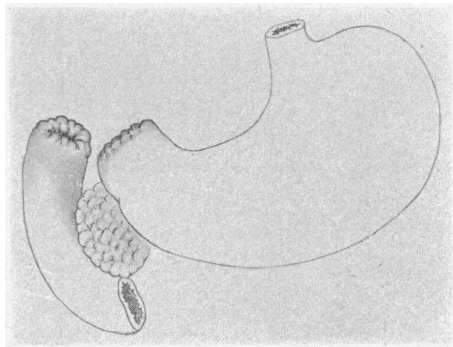


FIG. 4.

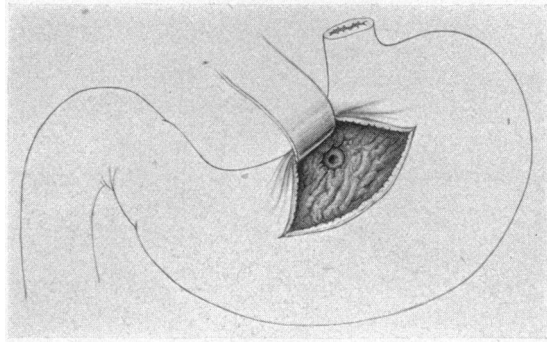


FIG. 5.

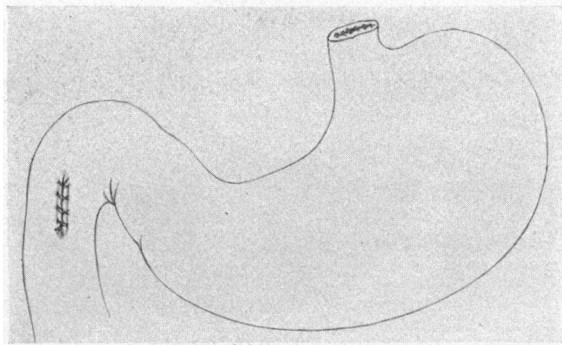


FIG. 6.

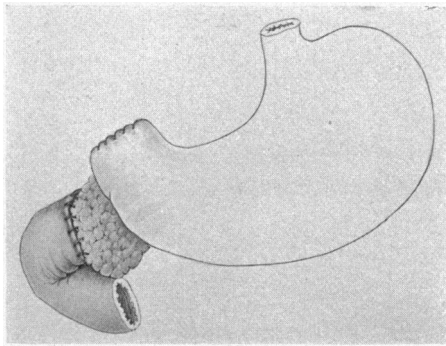


FIG. 7.

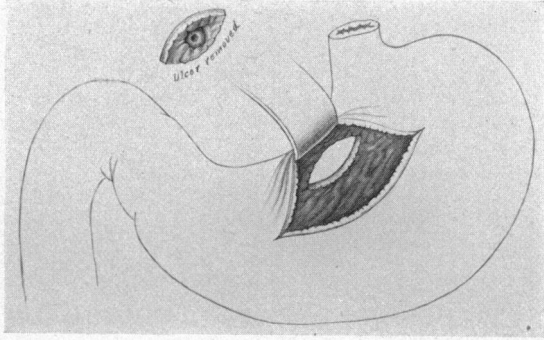


FIG. 8.

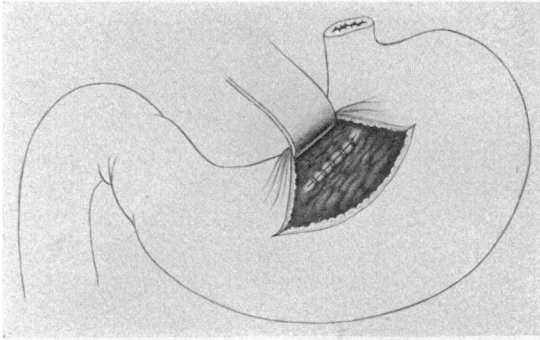


FIG. 9.




FIG. 10.

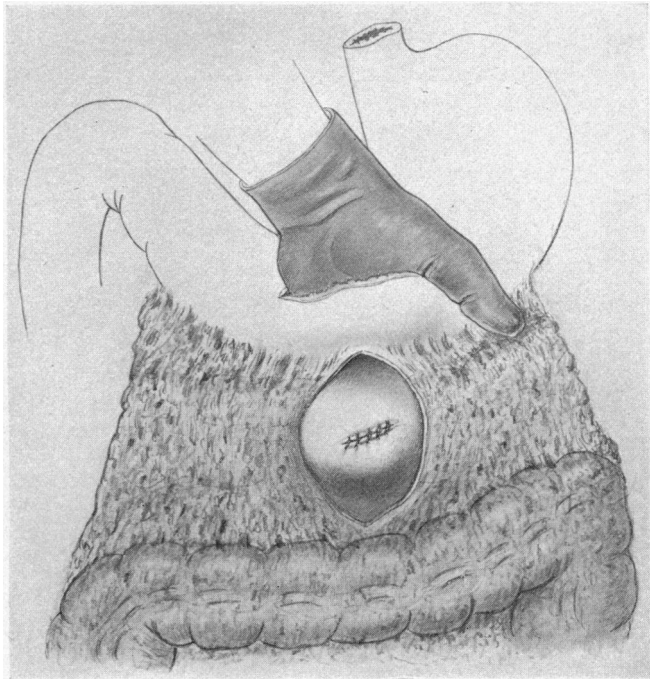


FIG. 11.

THE TECHNIC OF PELVIC FLOOR REPAIR

of the pancreas as to preclude the use of the purse-string suture and inversion, he adopted one of two procedures, namely: (1) Dissect the inner wall of the duodenum free from the pancreas (taking care not to injure the common bile-duct), purse-string it, invert and reinforce line of duodenal stump with great omentum, or if this cannot be safely done, (2) close the end of the duodenum with a continuous chromic catgut, stitch and sew the head of the pancreas over the duodenal stump. This he had done in many cases with good results up to the present, except in one instance. The chief point for discussion in the latter technic is the effect that the pancreatic ferments may have upon the transplanted duodenal stump, or, per contra, the possibility that the infection from the duodenal stump may be communicated to the pancreas.

In acute perforation of a duodenal ulcer it is his practice to make a posterior gastro-enterostomy at the primary operation. He had now operated upon forty-six patients in this manner with but one death. His reasons for advocating this procedure are, first, in order to place the ulcerated area immediately at rest; second, to secure the ultimate advantage of the operation which is curative in many cases, and third, because his experience with it has been so satisfactory as to entirely outweigh any theoretical objections that may be made against it.

Posterior gastro-enterostomy when the ulcer is located other than at the pylorus does but little, if any, good, therefore it is a useless procedure from the standpoint of cure. If posterior gastro-enterostomy does any good in this condition, it is only by allowing bile and pancreatic juice to enter the stomach, thus producing a neutralizing effect upon the acid contents of the stomach. That this operation accomplishes good by drainage alone he thought doubtful. The operation accomplishes most good where there is pyloric obstruction and where the ulcer has been excised.

THE TECHNIC OF PELVIC FLOOR REPAIR

DR. BARTON COOKE HIRST presented a series of drawings, remarking that the poorest work seen in surgical and gynæcological clinics to-day is the repair of the injuries of childbirth in the female genital canal. It is curious that this should be so, for of all the women who consult a physician for something peculiar to their sex, more than half suffer from these injuries and the most frequent of them is the laceration of the pelvic floor.

There are several reasons for this condition of affairs. First and foremost comes the foolish practice of immediate repair. This cannot be done successfully and no surgeon of experience, with the right sort

of surgical instinct, would attempt such operative work on bruised and distorted tissue, with a profuse blood discharge obscuring the field of operation, the operation being done probably in the middle of the night without proper assistance, implements or light and on the patient's bed. Nevertheless, the majority of the professors of obstetrics in this country advocate the immediate repair of lacerations of the birth canal.

This brought him to another reason for lack of progress in this work. The American specialist in obstetrics is usually the victim of the provincialism, peculiar to this country, of separating the surgical treatment of the diseases of women from obstetrics, so that the teachers of a branch requiring an expert's ability in surgery, have often had no surgical opportunities, training or experience. Consequently, their view on any surgical subject is not authoritative. Finally the surgeons and the so-called though misnamed gynæcologists, who see only the smaller part of the physiology and pathology of womankind, have no knowledge of the nature of the injuries experienced in child-birth and no experience with the result of their surgical repair on subsequent labors.

There are three principles that must govern this work: *First*, the anatomy of the region must be understood; *second*, the operator must know what happens to a woman who is injured in labor, and, *third*, each damaged structure should be restored to its original condition.

It is unnecessary to dwell on the anatomy of the pelvic floor—all are supposed to be familiar with it. It is very necessary in an association like this to point out what happens to the pelvic floor when it is lacerated in parturition. The following is a list of the damage done: (1) The levators are torn loose from their attachments to the pubic and ischiac rami, the tear running obliquely inward and downward and not usually involving the whole thickness of the muscle, which is therefore spread out, as it were, and much increased in length and tenuity. (2) The perineal centre is torn through, as a rule, separating the junctions of the superficial and deep transverse perineal muscles and the constrictor vaginæ. (3) The layers of the triangular ligament are torn where they fuse with the perineal centre, leaving a gap through which the rectocele protrudes.

Colles's fascia is naturally torn if the perineal centre is injured. The illustrations presented herewith show each step of the operation for the separate repair of all these structures. By cutting through both layers of the triangular ligament the levator is made accessible above the superior layer, the deep transversus perinæi is exposed between the two. The latter is always retracted and must be fished out of the cavity in which it lies. The posterior column of the

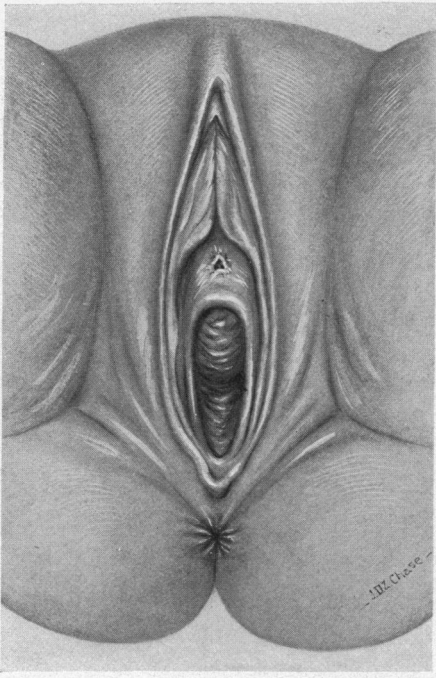


FIG. 12.—The result of laceration of the levatores ani, deep transversus perinei, fused layers of the triangular ligament, perineal centre, junction of superficial transversus perinei and bulbocavernosus muscles and of Colles's fascia. Note the low situation of the anus.

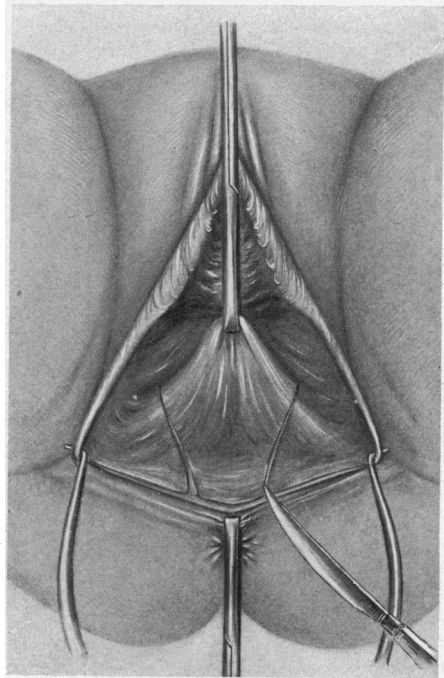


FIG. 13.—A convenient incision for the denudation to expose the injured muscles and fascia.

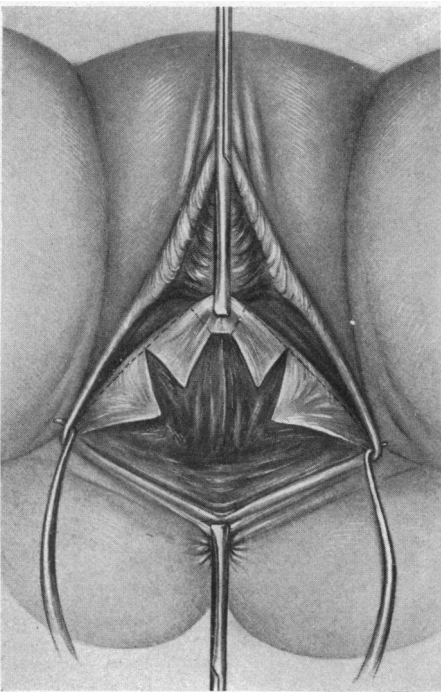


FIG. 14.—The denudation practically accomplished—to be completed by removing the mucous membrane within the dotted lines.

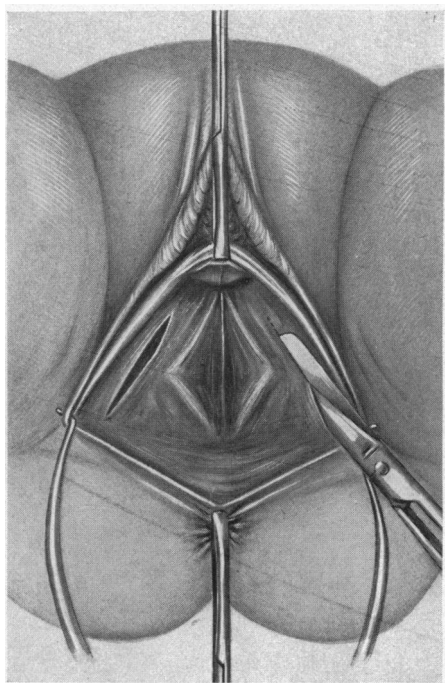


FIG. 15.—The incision through both layers of the triangular ligament to expose the levatores and the transversus perinei profundus.

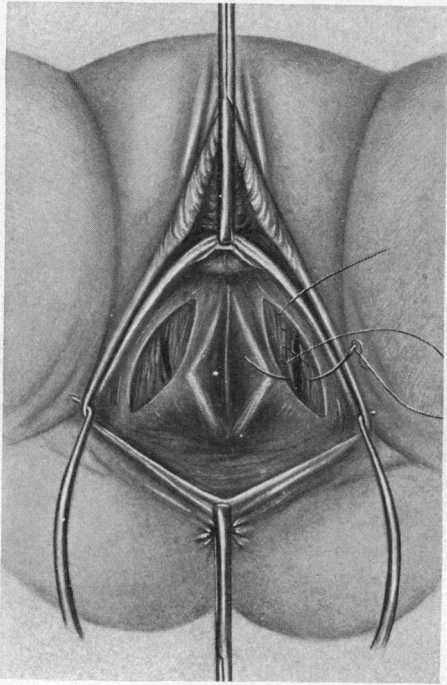


FIG. 16.—The levatores exposed and the cleft in them united by a two-tier suture.

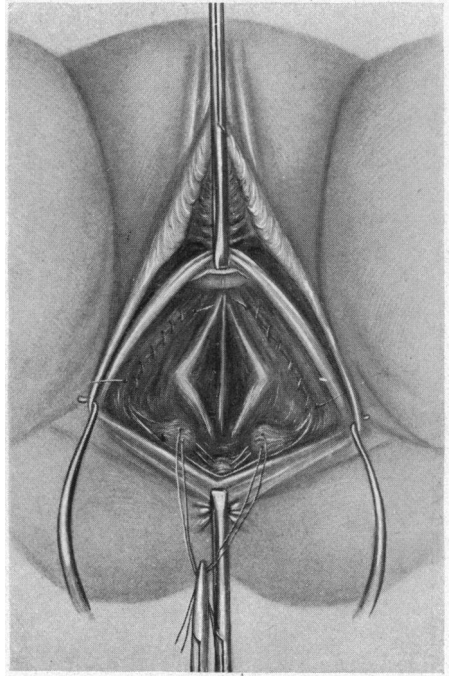


FIG. 17.—The levatores repaired and the deep transversus caught by two sutures and united at the base of the perineal body to give this muscle its original triangular shape and to restore its lifting power on the perineum.

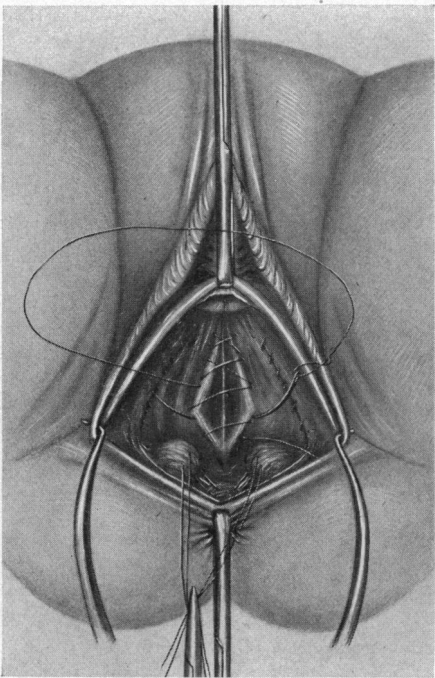


FIG. 18.—The cleft in the central fascia and the fused layers of the triangular ligament closed. It is through this cleft that the rectocele protrudes.

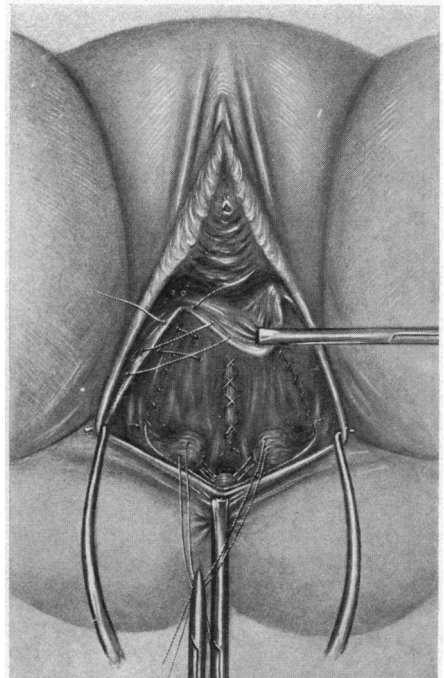


FIG. 19.—The triangular extensions of the denudation in the sulci closed.

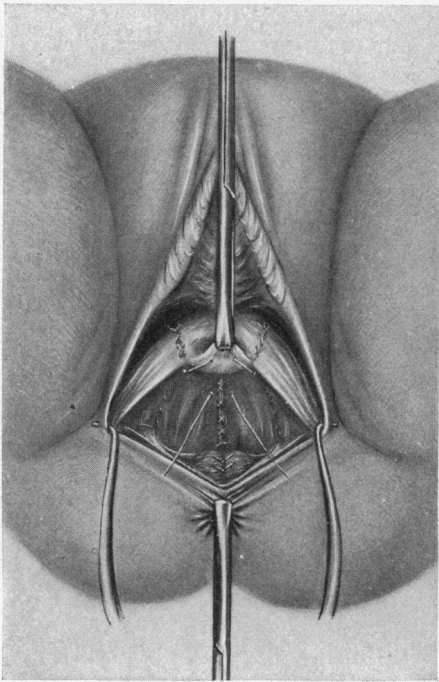


FIG. 20.—The posterior column of the vagina fixed in its normal position.

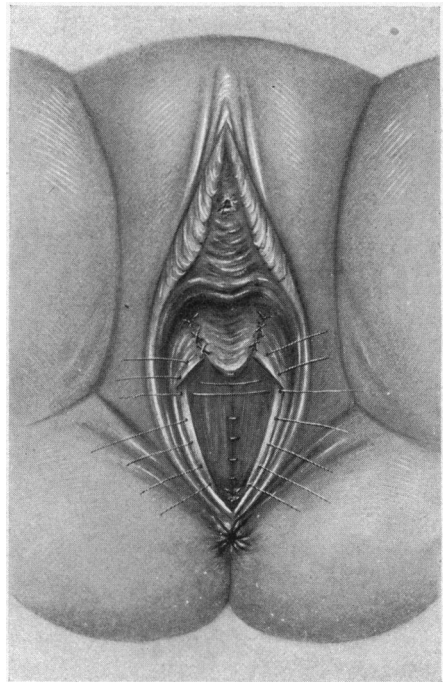


FIG. 21.—The perineal centre and Colles's fascia closed by interrupted sutures.

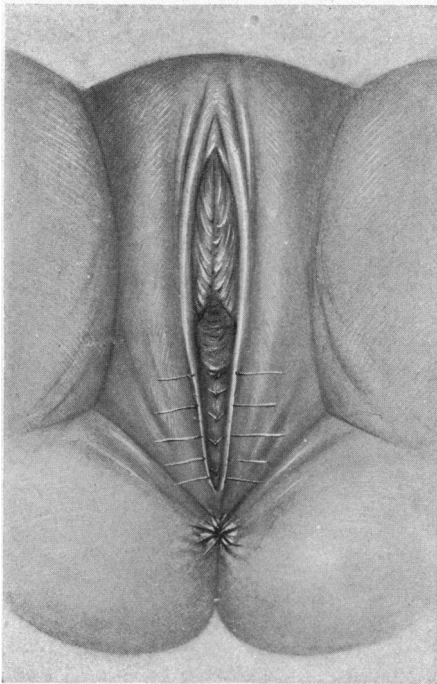


FIG. 22.—The skin of the perineum closed separately, burying all other sutures.

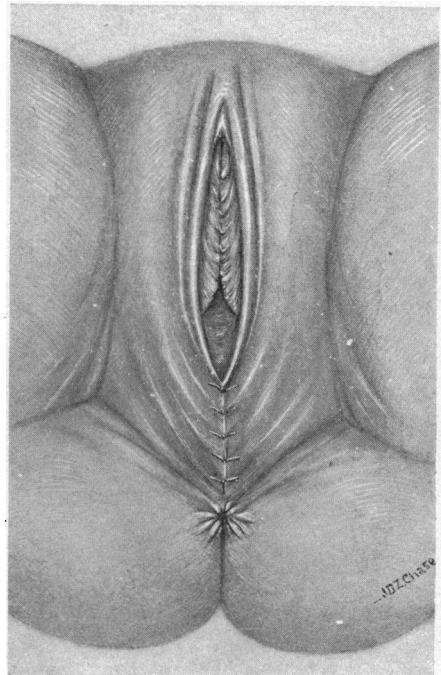


FIG. 23.—The operation concluded. The skin stitches are No. 1 extra hard chromic gut. All the other sutures are No. 1 chromic gut.

THE TECHNIC OF PELVIC FLOOR REPAIR

vagina is fixed in its normal position. The same stitches unite the perineal centre and Colles's fascia. The skin is united separately.

DR. RICHARD C. NORRIS said that any one doing much obstetric work will find that in many instances of pelvic floor injury the levator muscles and fascia are separated from their bony attachments. There are, however, many more cases in which the injury is confined to the more central portions of the pelvic floor, the levators being separated from the rectum, and in which separation from the bone has not occurred and which can be primarily repaired with success. It is his practice to do immediate repair of the perineum and the pelvic floor because in a large majority of instances the injury is of the latter type. By careful examination immediately after labor, if the injuries do not extend to the bony attachments, a good result follows from the primary operation. Furthermore, in private practice it is a serious disadvantage to allow an open wound to remain in the vagina for a week or ten days and then to suggest that the patient should undergo an operation with its entailed anxieties, just when the household has recovered its equilibrium and is ready to enjoy the baby's arrival in the home. Practically always one can have the patient do as advised, but sometimes patients resent this to such an extent that they will go to another obstetrician in a second labor. This, of course, is not a justification for doing the wrong thing. The cervix, moreover, when not a source of hemorrhage, if left alone, will often repair itself spontaneously. If repaired too early there may be interference with the discharge from the uterus. Excessive lacerations should be repaired early. His practice was not to delay more than six or eight weeks—at the end of the involution period—and the patient is better satisfied to have this slight operation at this time. The essential point in Dr. Hirst's paper was the need of careful study of the kind of injuries the woman has received. If in these extensive lacerations there has been separation of the fascia from the bony attachments an operation must be devised to meet the conditions. This requires skilled obstetric and gynæcologic service. In these excessive lacerations, however skilful the repair, one never can wholly restore the vaginal floor to its original anatomical conditions, and recurrent pregnancies and labors will undo the handiwork of the most skilful gynæcologist. In primiparæ with rigid infantile types of vaginas, in which one can foretell these destructive injuries, an extensive so-called episiotomy, in reality a deep incision through the levator muscles and fascia, alongside the rectum, will prevent injuries reaching to bony attachments, and the incision can be satisfactorily repaired immediately after labor.