

TRANSACTIONS  
OF THE  
PHILADELPHIA ACADEMY OF SURGERY

*Stated Meeting, held December 12, 1918*

The Second Vice-President, DR. HARRY C. DEAVER, in the Chair

CHARCOT KNEES COMPLICATED BY FRACTURED LEG

DR. JOHN B. ROBERTS presented a man with Charcot knee-joints who had been under treatment for lues by Dr. B. A. Thomas at the Polyclinic Hospital prior to and subsequent to coming under Doctor Roberts's care for syphilitic fracture of the tibia and fibula of the right leg just above the ankle. This occurred about two years ago while the man was walking in the street. No undue force had been applied to the bones which simply gave way under him as he walked. There seemed to be nothing special in the X-ray appearances to suggest a bone dyscrasia. Doctor Roberts treated the fracture in a swung fracture box in the usual manner. Union took place and the man was discharged with what appeared to be a well-united fracture of the tibia and fibula. It was the opinion of Doctor Roberts at that time that the fracture was not due to syphilitic bone softening and the man was expected to have no further difficulty if he postponed weight bearing for the usual period after fractures at the ankle. A number of months afterward he came under Doctor Roberts's observation again and said that he had been walking without any special support to the fractured bones. The leg showed a large mass of bone and callus at the ankle with lateral and backward displacement at the seat of fracture. The appearances still exist but he has been wearing now a brace to prevent further deformity and disability. The Charcot knees are characteristic and the man has been under constant treatment for about four years, taking large amounts of potassium iodide and mercury and many injections of salvarsan and arsenobenzol. The long-continued treatment with the support given by the orthopædic surgeons to his knee-joints and to his fractured leg has brought this man to a condition which enables him to make a living, though when first seen by Doctor Thomas he could scarcely move the limbs which were supposed to be the seat of paralysis of doubtful origin. The man's indomitable courage and the wisdom of Doctor Thomas, his first attendant, have reconstructed his legs to an extraordinary extent.

ERRONEOUS INTERPRETATION OF X-RAY PLATES

DR. JOHN B. ROBERTS showed a boy who had sustained a fracture of the lower end of the humerus which under ether was determined to be a fracture

or diastasis of the external condyle of the humerus without displacement. The X-ray seemed to show considerable displacement of the fragment at variance with what the clinical examination suggested. He also presented the X-ray plates of an old man who had had a dislocation of the right shoulder-joint of the subcoracoid variety. Dr. Morris Booth Miller and Doctor Roberts reduced the luxation under ether and felt sure from the anatomical appearances and the surgical examination that the head of the humerus had been properly replaced. X-ray examination by a röntgenologist of experience was made. The report that came to the surgeon was that the bone was not completely replaced. The subsequent history of the case showed that reduction had been complete and the interpretation of the X-ray plate was erroneous. These cases are indications that the surgeon and the röntgenologist should work together in order to get the true meaning of X-ray results as shown in photographic plates. This statement, of course, corresponds exactly with what we all know is also necessary in pathological and surgical consultations; namely, that neither the surgeon nor the microscopist, nor the röntgenologist can depend entirely upon his own findings. Each special method of examination needs at times to be checked up and correlated with the clinical or pathological or radiological examination, as the case may be.

#### POST-OPERATIVE INFECTIONS OF THE PAROTID GLAND

DR. JOHN B. DEAVER read a paper with the above title for which see page 128.

DR. MOSES BEHREND said that two months ago he operated on a case, removing the gall-bladder and the appendix. Two days later the parotid gland on one side became inflamed. The following day the gland on the opposite side was affected. The pain was intense and both glands had to be incised. The man had double facial paralysis which, however, entirely disappeared. He believed the paralysis was due not to the incisions but to the enormous pressure upon the facial nerves. The man had complete control of lips, corners of mouth and cheeks before he left the hospital. The case seemed of special interest because both sides became involved. In one other case following a minor operation the man developed an infection and later a severe parotitis. Numerous incisions were necessary to get rid of all the pockets of pus, the patient making a complete recovery without facial paralysis.

DR. J. TORRANCE RUGH remarked that the mouth presents the most profuse bacterial flora of almost any of the cavities of the whole body. If mucin acts to limit the development of bacteria, why then should there be such great number and variety of bacteria in the mouth?

DOCTOR DEAVER, in closing, said that the case to which Doctor Behrend refers he saw. The source of the infection in that case was probably the tonsils. The patient had a cardiac lesion. There was an acute infection of the parotid gland with deep suppuration. An incision was made into the gland

## RENAL CALCULI

by Doctor Behrend. Doctor Deaver regarded this case as an instance of hæmatogenous infection. He frequently had this type of infection in suppurative appendicitis and other infectious conditions. He had seen abscess of the pancreas result from infection elsewhere in the abdomen.

## RENAL CALCULI

DR. F. A. MANTZ (by invitation) read a paper with the above title. He said: The predisposing causes of renal calculi are sedentary habits, high living, and poor hygienic surroundings. The formation of these calculi is dependent upon the condition of the excreted urine, rather than upon an inflammatory process of the renal mucosa. However, there are exceptional cases; as pyelitis has been followed by extensive and massive stone formation in the kidney.

In order that these concretions may form, there must be of necessity an excess of certain of the solid constituents of the urine, which are most frequently urates, phosphates and oxalates. An excess of any of these salts favors a coagulation necrosis of the renal cells, thus forming a good nucleus for the deposit of any of the excessive salts that are present.

The symptoms depend more upon the position of the calculus than upon its size or shape. A calculus in the parenchyma or in a calyx, not infected and non-motile, may give rise to no symptoms at all. This fact has been proved by the X-ray examinations of patients suffering with other conditions than renal calculi, the calculi present being discovered accidentally in this way. The principal symptom is pain, radiating in a line to the bladder, scrotum and meatus, together with a desire to micturate. The urinalysis reveals red and white blood cells, pus and hyaline casts. Anuria is a symptom of bilateral lesions, but may be present when the lesion is unilateral, and is then caused by reflex action upon the other kidney.

To establish a positive diagnosis and to determine the proper treatment, we must call to our aid the cystoscope and the X-ray. The cystoscope reveals alterations in the flow of the urine from the ureter of the affected side; and catheterization of the ureters and examination of the two urines separately with the use of the phthalein test will determine whether or not the other kidney functionates sufficiently to carry on the necessary renal elimination, in case a nephrectomy is deemed expedient. Likewise, a wax-tipped ureteral catheter, as employed by Dr. H. A. Kelly, may be passed, to corroborate the presence of a suspected calculus when the X-rays fail to show a shadow. The X-ray examinations must be entrusted to the most experienced röntgenologist available—one who is able to interpret properly the skiagram and to differentiate the different shadows; since the uric acid and phosphatic calculi hardly cast any shadow, while the oxalate *stones* cast a strong shadow. The röntgenologist is often able definitely to locate the calculus, and thus facilitate its removal.

Having definitely diagnosed the presence of a renal calculus, its size and location, and whether the lesion is unilateral or bilateral, we must further

analyze the patient's physical condition, so as to determine the safest and best method of effecting *the desired cure*. The principles of renal-calculi surgery are to-day so scientifically sane and sound that, by adhering to them, the mortality due to these operations may be kept very low. By making such a thorough analysis of the case, we can nearly always determine before operation whether a nephrolithotomy is required, or a pyelotomy or a nephrectomy.

We should do a nephrolithotomy only when it is utterly impossible to remove the calculus by doing a pyelotomy. As a rule, all renal calculi are friable and easily crushed. Hence, most of the larger stones that fill the renal pelvis and calices may be crushed with an ordinary Kocher hæmostat or other forceps, and removed piece-meal, by way of the pyelotomy. Afterwards, the cavity should be thoroughly flushed with a normal saline solution or a mild antiseptic, to wash out the small remaining fragments or sand.

The risk of having a severe secondary hemorrhage following a nephrolithotomy far overbalances the probability of a permanent urinary fistula as the result of a pyelotomy. These secondary hemorrhages, which usually occur from the eighth to the tenth day after a nephrolithotomy, are always severe, and constitute a great source of annoyance and embarrassment to the surgeon who is fearful of being obliged to do a nephrectomy, which would have very serious consequences in a case in which the other kidney did not functionate sufficiently to carry on the required elimination.

A nephrectomy should be attempted only when there are many stones within the kidney, or when there is one large stone with an associated infection and destruction of the parenchyma.

The nonoperative cases include those in which a renal calculus is found in an extensive X-ray examination for some other condition, and in which the stone gives rise to no symptoms; especially so, when the patient is a poor surgical risk. On the other hand, all cases with an associated complication, such as extensive pyelitis, hydronephrosis or anuria, should be operated upon as soon as possible, even though the risk may be great; also cases in which the calculus has passed from the renal pelvis into the ureter and has there remained lodged, if, within a reasonable time, it does not find its way into the bladder. A calculus within the renal pelvis or in the parenchyma, giving rise to the symptoms of renal calculi, in a patient who is a good surgical risk, should be removed immediately, to avoid possible complications and sequelæ.

There is no drug that will dissolve a renal calculus within the human body. However, it is essential to treat the patient systematically after the operation, in order to prevent further stone formation. Diluents, such as distilled water in large quantities, to dilute the solid constituents of the urine, should be given; and a limited diet should be employed. No red meats should be allowed; but cereals and vegetables of all kinds, except rhubarb, tomatoes, asparagus and strawberries. Sugars, malt liquors and wines are interdicted, especially in the cases of those patients who are of a gouty diathesis. The free use of saline purgatives is imperative.

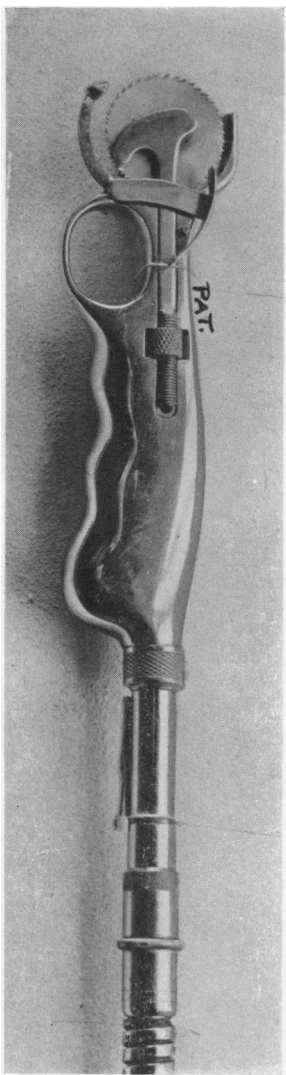


FIG. 1.

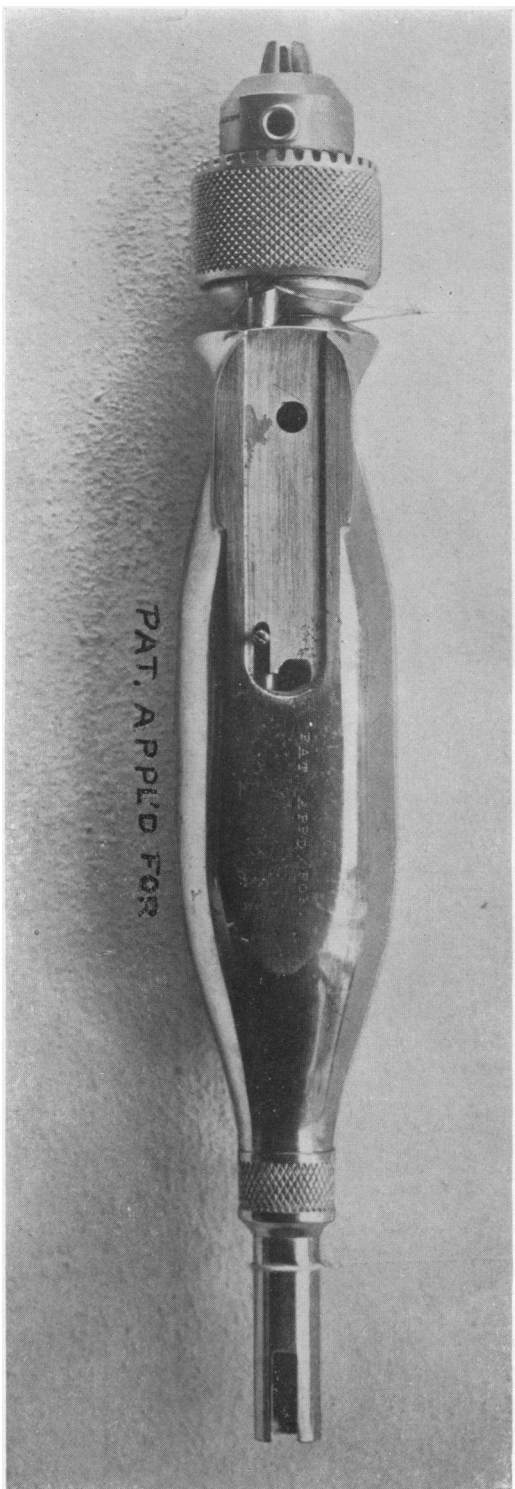


FIG. 2.—The tool-holder.

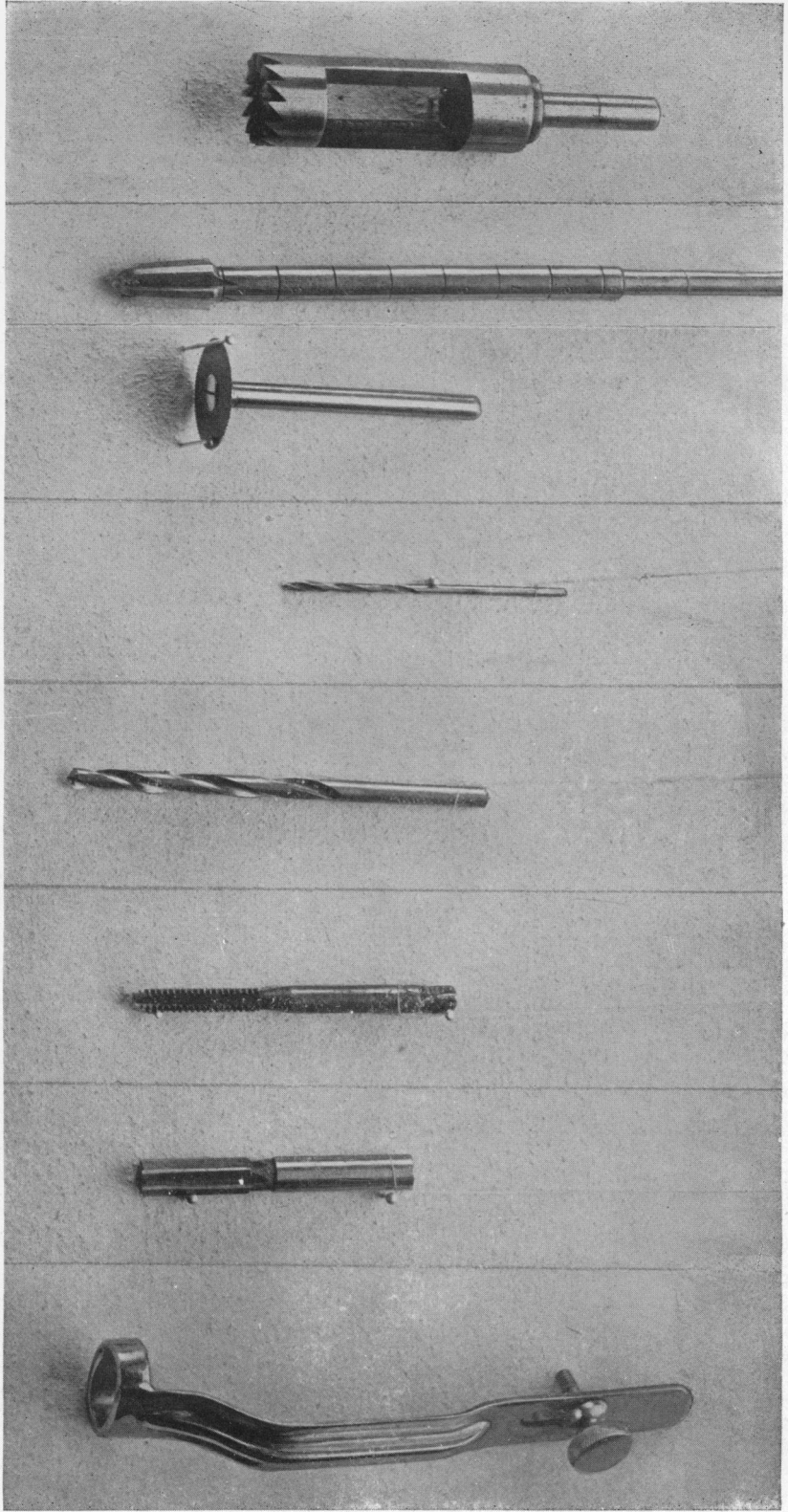


FIG. 3.—Drills, burrs and trephine.

## NEW BONE SAW EQUIPMENT

Post-operative anuria is reflexly caused by the rough handling of the kidney and the effect of the anæsthetic. Personally, however, I believe that this complication can, in a great measure, be prevented by giving the patient large amounts of distilled water with potassium citrate, a few days before the operation, in order to render the urine bland and stimulate its flow. Morphine sulphate, one-quarter to three-eighths of a grain, with 1/150 of a grain of atropine sulphate, should be administered half an hour prior to operating, for its anoci-association effect; but no morphine or atropine should be given after the operation.

Following the surgical procedure, normal saline solution as per the Murphy drip, should be administered, and plenty of water by mouth, as soon as the patient is able to retain it. Occasionally, also a mild diuretic may be given. These remedies constitute about all the medication necessary after the operation.

DR. JOHN B. DEEVER said with reference to the passage of stones that failed to show a shadow, to which Doctor Mantz had called attention: They are difficult cases, and he recalled a number. One case seen recently was that of a man from the South. He had the symptoms of bloody urine, renal colic, pain, etc. He was referred to the röntgenologist. The report came back that the man did not have a stone, but that there was a tubercular area in the kidney. Another good röntgenologist said that the X-ray examination of the kidney was negative. The man was then cystoscoped and the operator said he did not know what the man had but that the blood all came from one kidney. Doctor Deaver made an exploratory exposure of the kidney and the result was the finding of a stone one-third the size of the fist in the kidney. He then called up the first röntgenologist who said he would like to have the stone. He put it in water and could not get a shadow. The case was one of those impossible of diagnosis because of the quality of the stone. No doubt there occur many such cases which slip through our hands.

## NEW BONE SAW EQUIPMENT

DR. H. C. MASLAND (by invitation) demonstrated the new bone saw equipment devised by him. It consists of two major instruments quickly adjustable to a flexible shaft of ample strength, driven by an electric motor.

One instrument is a circular saw mounted in a very convenient handle. The saw has a gauge immediately adjustable to cut any depth desired. This can be drawn back and an inside guard attached which protects the dura in cutting the skull or any other underlying soft tissue when the saw is used elsewhere. The nose of the instrument is about one inch wide, so that the saw can be used on deep-lying bones for either a vertical or a bevel cut.

The other instrument is a universal tool holder having a construction to facilitate the performance of various other operative procedures. Drills from the size of catgut up. Burrs of various types and sizes, a special trephine for opening the skull safely, hollow mills for bone pins, side cutting

## PHILADELPHIA ACADEMY OF SURGERY

mills to make level floored gutters for inlay work, a small circular saw, taps for threading holes and dies for bone pins.

This tool may be power driven or immediately detached and used as a hand instrument.

The doctor drives his instruments at low speed and thereby eliminates burning and does not need the water drip. The equipment meets rigid aseptic requirements.

DR. J. TORRANCE RUGH said that he had always felt that the difficulty in this type of operating device was in the cable, and this problem Doctor Masland seems to have solved. The majority of these cable-operated machines keep jamming and bending, but Doctor Masland has a cable which is powerful enough to drive the instrument evenly. It has the advantage also of being of a size convenient to handle in the field of operation. Doctor Masland tells us that the cable may be boiled, but it must have oil, and the speaker would feel a little doubtful about boiling it. He suggested a device such as may be used on the Albee machine. For the supply cord there is a long tube or muslin casing running up to the handle of the motor. Some have a motor of the same type as Doctor Masland's and wrap the whole thing in a sterilized casing when using it and have no trouble about asepsis.

Another feature which commends this machine is that it is a low speed motor. He had never felt favorably inclined toward a high speed motor in bone work. It will burn the bone unless water is used, and many other inconveniences attend its employment which are eliminated by the low speed machine.

DR. MOSES BEHREND said that with the Albee instrument one must hold a rather heavy motor; but with this the toolholder of Doctor Masland can be held with one hand. The Albee motor will often jam, as has been said. Doctor Masland's does not do this on account of his slow speed motor. The chuck is almost perfect; it will hold a hair. The smallest kind of a drill can be used which is a distinct advantage. Also the chuck is commendable because one can put in almost any sized instrument.

DOCTOR MASLAND, in closing, said that his first sleeve was of the usual dental composition type, covered with a sterilizable muslin sleeve. This did not appeal to him as thorough asepsis. His present cable and tubing are metal throughout, save for the asbestos packing in the crease of the spiral of the tubing to make it water-tight. The sleeve is brass, nickel-plated, and of the same construction as gas or speedometer tubing. A little heavy grease is used for lubrication. This will not run out through the accurately fitted ends. If it did it could be prevented by elevating the ends of the flexible shaft in the sterilizer.

### THE SEGMENT TREPHINE

DR. JOHN B. ROBERTS remarked upon the evident efficiency of this saw of Doctor Masland. Those who have worked in bone surgery of the skull have realized the trouble with ordinary saws and trephines. Years ago he



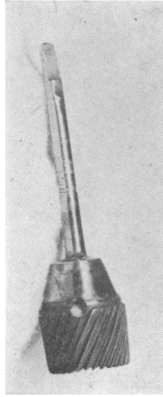


FIG. 4.—Roberts's cranial trephine, made in 1882, to be driven with Bonwill dental engine.

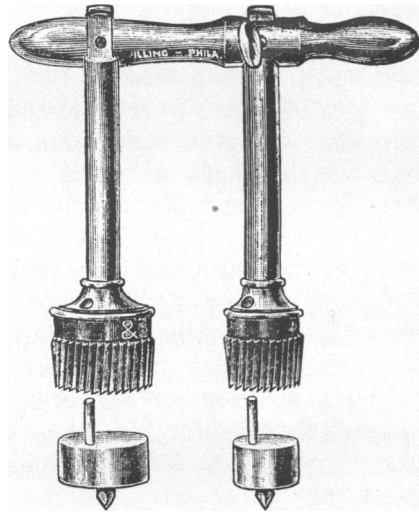


FIG. 5.—Roberts's aseptic trephine, late model.

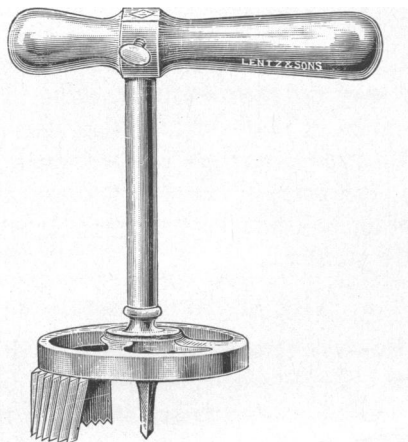


FIG. 6.—Roberts's aseptic segment trephine for making trefoil-shape flaps of bone in resecting the cranium.

## THE SEGMENT TREPHINE

undertook to use the Bonwill surgical engine for driving burrs for bone work on the extremities and head, but found it difficult to keep in order in surgical operating rooms. The little cranial trephine, which Doctor Masland has adopted to use with his outfit, Doctor Roberts had made for cranial use about thirty-five years ago, when he demonstrated that one could safely trephine the cranium by boring holes with a flat fissure burr. An entrance could thus be made into the cranium without damaging the dura. This little trephine (Fig. 4) with its conical shape and spiral cutting surface has a way of jamming itself when the saw edge of the crown cuts through the bone to the dural surface. Doctor Masland's experimental work with him, in the laboratory and on patients with his new saw, has revived the use of this instrument. The electric motor and cable which Doctor Masland uses in connection with his saw drives the trephine very satisfactorily. The instrument is easily sterilized and has a small hole through which it may be cleaned and the button of bone pushed out if it remains caught within the trephine. It needs no centre pin, or a drain with a centering point, though the latter could be fitted to it. Through small holes made by this instrument the Gigli saw may be used, if the Masland saw is not at hand, to make the osteoplastic flap to be turned down for access to the brain surface. Some years ago Doctor Roberts devised an aseptic trephine without the old-fashioned centre pin, which is familiar to many of the Fellows. He now showed a new model (Fig. 5) recently made for the army by Pilling. It is in some respects not as satisfactory as the original made by hand at the time when surgeons began to do operations for the removal of brain tumors, twenty or more year ago, but large numbers of the present form can be made by machinery and therefore at a much lower price. It does not need the stem which the instrument maker has put upon the drum which carries the centre pin. He also showed (Fig. 6) the aseptic segment trephine which does well in making clover-shaped flaps in resection of the skull for entrance to the cranial cavity when special saws like the Masland saw are not at hand. It and the various methods used to do osteoplastic sections are valuable now that surgeons always try to have bony closure of the gap made in the cranial wall. The methods which depend upon cutting away with gnawing forceps the bone and leaving great openings to be closed only by fibrous tissue have become antiquated and are to some extent looked upon as survivals of pre-Listerian surgery.