

TRANSACTIONS
OF THE
PHILADELPHIA ACADEMY OF SURGERY

Stated Meeting, held January 7, 1918

The President, DR. CHARLES H. FRAZIER, in the Chair

**THE DANGER OF THE PERNICIOUS BOND SPLINT IN CARPAL
FRACTURES OF THE RADIUS**

DR. JOHN B. ROBERTS said that successful treatment of the usual fractures near the carpal end of the radius demands: (1) Free separation of the basal from the shaft fragment, whether impacted or entangled. (2) Forcible reduction until the normal arch of the palmar surface of the radius near the wrist is restored. (3) Retention of this concave anterior surface of the carpal fifth of the radius. (4) A flexed wrist-joint during convalescence and abstinence from the use of a flat splint for support, on the palmar aspect of the forearm and hand, aid greatly in preventing displacement of the carpal piece after its reduction. This is particularly the case in comminution of the lower fragment.

In his opinion "Bond's splint," so much used in Philadelphia, is an anachronism and should be discarded from use as a dressing for these fractures.

(a) Some of them need no other dressing after reduction than flexion of the wrist-joint maintained by a rigid material.

(b) Others require a straight strip of wood or metal on the dorsal surface from mid-forearm to metacarpal-phalangeal joint or a convex incompressible splint of cork, wood, metal, or hardened plastic material to support the arch in the anterior surface of the lower fifth of the radius.

(c) Still others, because of severity of the vulnerating force or brittleness of bone, do better by being encased in a Levis splint of swedged copper on the palmar surface of the forearm and palm of hand, or else a molded gypsum gauze splint covering the dorsum of the forearm and hand, applied before the plaster of Paris is set. Both of these dressings should keep the wrist flexed during their use because the extensor tendons have a tendency to hold the fragments in place. These conformed dressings usually are not needed for more than three or four weeks, even in severe injuries.

In illustration of these statements he described a case in which the original fracture, not originally under his care, had been apparently a comminuted and backward displaced fracture of the lower end of the bone. A Bond splint had been applied with a pad of gauze under the lower end of the radius with the idea of holding the fracture in adjustment. When seen by him three weeks after injury, there was marked prominence of the head of the

IMPASSABLE TRAUMATIC STRICTURE OF THE DEEP URETHRA

ulna at the back of the wrist and some displacement of the carpal fragment forward. The patient was suffering great pain until he removed the dressing and substituted a gypsum gauze retentive apparatus until he could persuade her to take ether and allow him to reconstruct the lower end of the bone. She delayed this operation for about three weeks. He then, under ether, pushed the lower fragment upward so as to bring it into proper apposition with the shaft. The deformity due to the apparent dislocation of the head of the ulna disappeared.

This confirmed his opinion that the lower fragment of the radius, because of the use of the Bond splint and a possible mal-adjustment during the first three weeks after injury, had been displaced forward without rupture of the radio-ulnar ligaments. This gave the appearance of a radio-ulnar dislocation.

He had seen fractures with backward displacement treated with the Bond splint in which the displacement had apparently been reproduced by the support not being properly obtained under the arch on the palmar surface of the lower part of the shaft. He thought that in the case now reported the pad of the Bond splint, which goes in the palm of the hand, probably caused the secondary deformity by reason of causing motion at the seat of fracture instead of at the wrist-joint. This is his explanation of the change during the Bond splint treatment from a backward displacement to an anterior displacement of the carpal fragment. He believed the Bond splint to be a dangerous form of splint for fractures of the base of the radius. It should be discarded from the surgeon's outfit.

DR. JOSEPH M. SPELLISSY thought that the Bond splint, which Doctor Roberts condemned, could be used with great advantage if it were properly padded. The arch of the wrist needs to be preserved. Of course, if the Bond splint is used without building up, the hand is thrown into the wrong position, aggravating the deformity. Oakum can be used to advantage for padding, since it is soft but can be molded into shape and is better than gauze. If the fracture be reduced over the knee and the hand put in the proper position, it has the grasp needed, the oakum fills up the space and if necessary repeated dressings can be inserted under the lint used to cover the oakum. The splint takes up very much less room and is less expensive than the more elaborate forms.

IMPASSABLE TRAUMATIC STRICTURE OF THE DEEP URETHRA

DR. T. TURNER THOMAS gave the history of a man, thirty-eight years old, who was admitted to the University Hospital October 29, 1917. Has always been strong and healthy. January 19, 1917, while at work in the mines, was squeezed in the pelvic region between two cars. After being in a hospital for thirteen days following the injury, he was operated on but does not know the purpose of this operation, except that a rubber drainage tube was passed from one groin to the other, evidently above and in front of the bladder. He says that he could void urine before the operation by the normal

PHILADELPHIA ACADEMY OF SURGERY

route fairly well. The tube was removed a week after operation, but on the following day urine escaped from both openings in the groins and ceased to pass by the urethra. The opening in the right groin closed and has remained closed since, but that in the left groin has drained urine periodically since but has not in the last two weeks.

A second operation was performed March 1st, its purpose being to cause closure of the urinary sinus in the left groin and the re-establishment of urination by the urethra. The bladder was opened suprapubically and the urethra through the perineum, a tube being passed from one opening to the other. This was removed eighteen days later under an anæsthetic. Urine passed through the urethra two or three times after this, then ceasing and soon making a new opening for itself in the right buttock. The urine afterward escaped by this opening and that in the left groin.

In July a third operation was performed for the purpose of re-establishing normal urination, only a median perineal incision being made. This attempt also met with failure. At the time of admission to the University Hospital he had for some time been urinating only through the opening in the right buttock and seemed to have good control. He did not soil his clothing and could get to the toilet in time, although he sometimes had to hurry. He voided about every two hours.

Operation was performed at the University Hospital, December 6, 1917. A suprapubic incision was first made, considerable difficulty being experienced in deciding that the bladder had been opened because of its small size, its displacement to the right, and the fact that no prostate or urethral orifice could be detected. A probe passed into the urinary sinus in the right buttock failed to reach far enough to be felt by the finger in the bladder and probably did not get to the bladder or urethra. A No. 26 F. sound introduced by the meatus passed to about the anterior layer of the triangular ligament, a No. 20 a little farther, but it could not be felt by the finger in the bladder. An incision about an inch long was then made in the midline of the perineum to the end of the sound, thus opening the urethra. There seemed to be at least an inch between the end of the sound and the finger in the bladder which was trying to feel the sound through the intervening tissues. With no guide on the inside to indicate the former position of the internal urethral orifice, now probably replaced or closed by cicatricial tissue, the re-establishment of the obliterated portion of the urethra presented difficulty. It was decided to force the end of the sound onward into the bladder and later to maintain the track thus made if possible. For a small distance the sound seemed to be opening up a contracted urethra but for the greater part seemed to be making a new path for itself. The finger could not reach to where the sound came through the mucous membrane, but at this stage and in passing other instruments afterward an assistant by his finger in the rectum determined that the rectal wall had not been penetrated. The sound was then withdrawn and a grooved staff introduced into the bladder, on which as a guide a long-bladed bistoury, with its edge turned downward and

BILATERAL RENAL CALCULI WITH ENTEROVESICAL FISTULA

to the right, was passed along into the bladder, thus increasing the calibre of the new opening. A No. 26 metal catheter was then passed and its outer end fastened to the penis, to preserve as far as possible the normal shape and curve of the urethra. The lower part of the suprapubic opening was closed by two silkworm-gut sutures, in the upper part a rubber tube being introduced and fixed by suture. The considerable oozing was controlled by gauze packing, and the perineal opening was also thus packed.

The patient had one chill with a moderate rise in temperature after operation, but aside from this did remarkably well. The suprapubic drainage tube was removed in one week and the urine ceased to escape from it in about two weeks and from the perineal wound in about three weeks. The metal catheter was removed twenty-nine days after operation. It was immediately afterward reintroduced and this was followed by a No. 28 F. and a No. 29 F. sound, showing that the new urethra was easy to follow with such instruments. On the next day Nos. 26, 28 and 30 were passed, the last with considerable distress. These were passed daily for about two weeks and then every two days until the patient was discharged from the hospital December 26, 1917. He left the city soon afterwards and has not been seen since, but he promised to have the No. 30 F. sound passed regularly, twice a week for a time and less frequently later.

BILATERAL RENAL CALCULI WITH ENTEROVESICAL FISTULA

DR. ARTHUR E. BILLINGS recited the history of a man, aged forty years, who, since 1906, has had occasional pain in his back, at times with frequent micturition. Since childhood he has complained of an "irritable bladder." In the autumn of 1909 he had a severe kidney attack and, after being confined to bed for three or four days, developed severe abdominal pain, persistent vomiting, and absolute constipation, which was diagnosed as intestinal obstruction by his physician and consulting surgeon. He was relieved of this without operation. Soon after this he expelled gas and he thought a slight amount of fecal matter from his bladder. In 1913 he had another renal attack and was in bed for several weeks; after this he had a cystoscopic examination by his physician and was told that he had ulcers in the bladder, which were probably tuberculous and that one of the ulcers communicated with the bowel. He was admitted to the Pennsylvania Hospital September 25, 1916, with a temperature varying between 101 and normal, for six days, and a moderate leucocytosis. In the meantime he was skia-graphed and large stones were revealed in both kidneys with the bladder and ureters negative. At this time there was tenderness over both kidneys, both were palpable, and the left seemed definitely enlarged, where his pain and tenderness were greatest. A phenolphthalein elimination test showed 13 per cent. for the first hour and 12 per cent. for the second hour. Cultures of his urine showed colon bacilli and *Bacillus pyocyaneus*. A cystoscopic examination and ureteral catheterization was not done because it did not seem wise under the condition. Wassermann examination was negative. Elimination was

PHILADELPHIA ACADEMY OF SURGERY

encouraged and favored in every way. Supportive and local treatment, consisting of irrigation, etc., was instituted, and benzoic acid was given as a urinary antiseptic, because his urine was persistently alkaline and loaded with phosphates and urates. His lowest point in urinary elimination was 20 ounces in twenty-four hours. On November 16th, his general condition had greatly improved, temperature had been normal for three weeks, leucocytes had dropped from about 24,000 to normal, and his average urinary output was above 60 ounces for twenty-four hours, with considerably less pyuria.

Operation.—Under morphia and atropine and nitrous oxide-oxygen anæsthesia the left kidney was exposed through the usual costo-iliac incision. It was very adherent, but was delivered and the cortex split longitudinally, the stones were removed and the wound in the kidney was closed with catgut mattress sutures. The kidney pouch was drained. There was a moderate amount of urinary drainage for the first fifteen or eighteen days. He made an uneventful recovery and was discharged December 12, 1916. He was re-admitted January 26, 1917, after having gained considerable weight and generally improved.

Second Operation (February 1st).—Under morphia and atropine and nitrous-oxygen anæsthesia the right kidney was exposed in the same manner as the left and it also was very adherent and there was considerable bleeding both from the adhesions and the incision of the kidney, which was also longitudinal through the cortex. The stones were removed, the kidney was closed and the bleeding controlled with catgut mattress sutures. The pouch was drained as on the left side with a rubber covered gauze drain. On the fourth day after operation his abdomen became greatly distended, with persistent vomiting, and evidences of a mass in the right lower quadrant and the suprapubic region were discovered. At the end of twenty-four hours he had expelled gas and was a little improved. During this twenty-four hours his urinary output was about 50 ounces. On the sixth day he was much improved, the mass disappeared and the situation cleared up with the several bowel movements. On the eighth day he had quite a discharge (2 or 3 ounces) of fæces with a lot of gas from his bladder. This persisted for two or three days, his bladder was irrigated sixth hourly and a continuous catheter kept just within the bladder for a few days and 5 per cent. silver iodide emulsion instilled twice daily. Aside from this his recovery was uneventful and he was discharged March 23, 1917, both wounds having healed and being in good condition.

There was no gross clinical evidence at the time of operation of tuberculosis in either kidney. At this writing he has a slight pyuria, but has not had any further fecal discharge from his bladder, although he thought shortly after leaving the hospital, while acutely constipated, that he passed gas from the bladder. His general health is greatly improved and he has added considerable weight (about 20 pounds).

DR. B. A. THOMAS, supplementing what Doctor Billings had said, re-

BULLET REMOVED FROM LEFT LUNG

ported another case of bilateral renal calculi with also bilateral urethral calculi. The case is that of a boy aged twenty-three years, who, his mother said, had passed two stones from the urethra at the age of two years and during his early life he had two attacks of illness which were diagnosed appendicitis. The immediate history of the case is that eight weeks prior to the time he was seen by Doctor Thomas, which was last summer, after having joined the Army, he was seized with a violent attack of left-sided renal colic. That is the side which shows one stone in the lower left ureter. This attack lasted for four weeks, after which he was entirely free from pain until five days prior to the time he saw him when again he had an attack and was admitted to the Polyclinic Hospital. At that time he had considerable suppression of urine; he was extremely toxic. Cystoscopic examination was made and indigocarmine was found to be eliminated on the right side, not until twenty-five minutes. This is the side in which there were the three or four stones. On the left side there was no elimination for that length of time. A urethral catheter was obstructed on the left side at a distance of 10 cm. The patient was losing ground, and was very toxic. It was decided to do only a nephrotomy on the left side which was the side in which there was no function. This was done, but four days later, although for two days there seemed to be improvement, he died, apparently from suppression of the urine. The stones removed were stuck so tightly to the kidney tissue that it seemed almost as if they would break in removing them. Possibly this boy had had renal calculi from the time he was two years of age.

BULLET REMOVED FROM LEFT LUNG

DR. GEORGE P. MÜLLER reported the history of a man, aged thirty years, who was admitted to the Polyclinic Hospital October 23, 1917, suffering from a gunshot wound of the left lung. There was a wound of entrance but not of exit. There was some dyspnoea, but no other symptoms, and the physical signs were those of moderate hæmothorax. The patient was not very much shocked, and was rather under the influence of alcohol.

On the following day the X-ray examination revealed the bullet to be in the lower lobe of the right lung. On the same day he developed delirium tremens and was quite ill for about one week, by which time he was suffering from dyspnoea from the increasing effusion in the chest. There was also marked aphonia, but this could not have been caused by any injury from the bullet. There was also a great deal of pain at the suprasternal notch.

Operation was done under ether anæsthesia (open method), October 31, 1917. A long incision was made over the fourth rib and about four inches of this resected. After cutting through the intercostal membrane the pleura was separated up and down for a little distance and then opened, and then the cavity was found to contain 600 c.c. of bloody and serous fluid. The lung was adherent to the diaphragm and was separated from this adhesion with difficulty. The bullet was felt in the lower lobe and the lung was

PHILADELPHIA ACADEMY OF SURGERY

brought up into the wound and, by squeezing, the bullet made prominent. A small incision over it allowed it to be popped out. The lung was dropped back into the cavity and the pleura, muscles, and skin sutured.

A beginning was made to dry out the cavity, but, as the patient did not do well, this was abandoned. It was not possible to entirely suture the pleura. The patient stood the operation well and, although at times was rather dyspnoëic, this was controlled by drawing the lung into the wound and steadying the mediastinum. The patient made an excellent recovery and six days after operation was up and about the ward.

A FAT-FASCIA-BONE TRANSPLANT FOR DEFECT OF SKULL

DR. PENN G. SKILLERN, JR., reported the following case:

J. V., male, white, aged thirty-two, tiler, was admitted to Polyclinic Hospital (Case Record No. 32216—service of Dr. George P. Müller) on October 26, 1917. Discharged improved on January 15, 1918.

History of Present Condition.—Eighteen months ago—on May 7, 1916—the patient suffered a gunshot wound of head. Immediately upon being shot he had convulsions on left side, involving arm and leg; he then fell upon the floor. The bullet entered the right frontoparietal region and passed backward and downward toward the right occipital bone, against which it lodged: it had not been removed. Three months after the injury—in August, 1916—the first operation was performed: the wound was “cleaned out.” The paralysis did not improve after this operation and convulsions continued. Three months after the first operation (six months after the injury)—in November, 1916—the second operation was performed: “a piece of bone was removed.” After this operation the convulsions disappeared and the patient began to move the left leg.

Physical examination reveals a trephine opening in the right frontoparietal region, which opening is partially filled in around the edge. There is hemiplegia of the left side, excluding the face. There is an intention tremor—the limbs can be moved if the patient contracts other muscles first, and when the limbs move they exhibit marked tremor. The reflexes are exaggerated, including the deltoid, biceps and wrists, knee-jerks and Babinski: ankle-clonus is present. The flexors of the fingers are somewhat contracted.

The skiagram (Fig. 1) showed the bullet to right of and just above the external occipital protuberance and very close to it, resting upon the tentorium cerebelli. The wound of entrance is revealed as an irregularly circular defect in the right frontoparietal region, over the upper portion of the fissure of Rolando: seen through this defect is a cluster of spicules of bone, apparently carried into the brain by the bullet.

The patient wanted something done in an operative way for the following reasons: Up to the time of the receipt of the injury he had been a vigorous, able-bodied man who worked hard at his trade (tiler). With the exception of the left-sided hemiplegia he still retained these pristine physical qualities and brooded over his inability to work. He therefore wanted an attempt

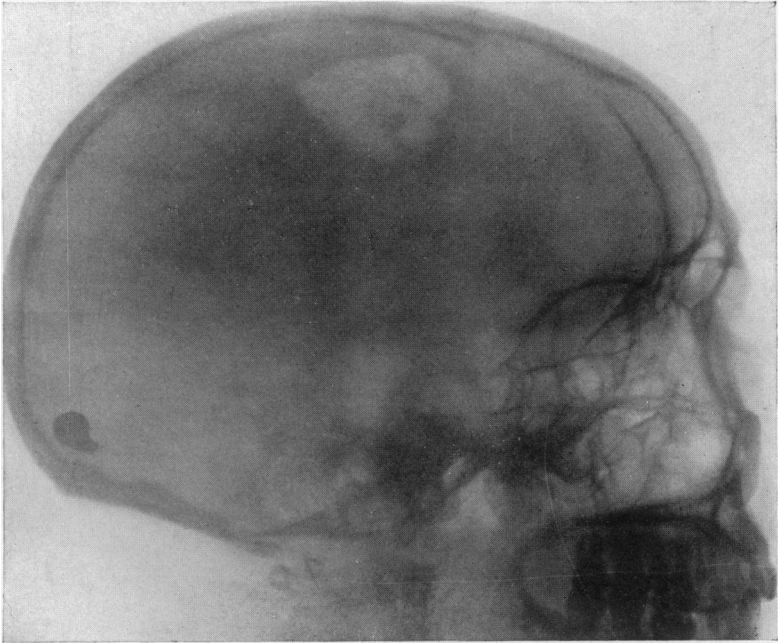


FIG. 1.—Preoperative skiagram orientating bullet in posterior cranial fossa and showing defect in frontoparietal region. Note spicules of bone in brain as seen through the defect—these spicules were carried into the brain by the bullet in its course.

A FAT-FASCIA-BONE TRANSPLANT FOR DEFECT OF SKULL

made to restore the usefulness of his limbs. He also complained that every time he moved his head he experienced in the back of his neck a creaking sensation, as of two pieces of leather being rubbed together. So, too, the defect in the skull, which he could plainly feel, preyed upon his mind and gave him a sense of insecurity.

A study of these propositions from a surgical standpoint did not offer, in the first instance, much hope in the restoration of the usefulness of the limbs. The hemiplegia was doubtless due to destruction of motor cells in the precentral gyrus with subsequent cicatrix formation in the path of the bullet. The only hope in this direction lay in freeing the brain from scar-tension, by removing the dural scar and as much as feasible of the scar-tissue formation that had filled in the path of the bullet. As to the removal of the bullet, such a procedure from a practical surgical standpoint had no indication: it was merely to gratify the patient's wish and relieve him of the paræsthesia of which he complained that this step was contemplated. As to closure of the skull defect, no objections could be found why this should not be accomplished.

Accordingly, the bullet was removed on November 13, 1917, through an osteoplastic flap. The wound healed uneventfully, and the patient no longer complained of his "leather" paræsthesia. Examination of O.S. after operation showed the vision the same as that in O.D.: the patient did not lose the sight in his left eye, as was predicted by an eminent neurologist in case the bullet were removed.

The second operation was performed twenty-four days after the first—December 7, 1917. As this operation is believed to present a more or less original method of closing a skull defect—original in the preservation of the connection of the deep fascia and fat with the bonegraft—the following details have been extracted from the history sheet.

Horseshoe flap of scalp with base below raised, exposing trephine skull defect and adjacent bone. Scar-tissue raised from brain and freed from edge of skull defect. Brain opposite latter more or less disorganized—surface flattened, no convolutions visible. A dense body was palpated in the brain: this was removed and proved a fragment of bone twice the size of a grain of rice. There was some bleeding—arterial spurts and venous oozing—from the median portion of the wound, but this was controlled by packing. The superior sagittal sinus was not opened. The wound was now packed and temporarily closed with a silkworm-gut suture, preparatory to removing the graft from the tibia.

The upper broad subcutaneous surface of the left tibia close to the tibial tubercle was exposed and cleansed with iodine. A goblet-shaped incision was made over this area, and the skin with a thin layer of subcutaneous fat was reflected. The fat, still attached to the deep fascia and periosteum (including tendinous insertions of sartorius and gracilis muscles), was cut wider than the button of bone to be removed, the excess of soft tissue was gathered into the mouth of a 1½-inch trephine, and the button of bone was re-

moved. The medullary tissue and endosteum were scraped away from the graft. The leg wound was closed.

Going back to the skull, the silkworm-gut suture was removed, as well as the packing. The fat-fascia-bone graft was inverted, so that its medullary surface lay uppermost (*i.e.*, toward the scalp) and its fat surface most deeply (*i.e.*, against the brain). Six interrupted sutures of chromic gut No. 00 were applied so as to secure the edge of deep fascia and periosteum to that of the dura: these sutures were left long. The edge of the skull defect was freshened and drilled in two places at opposite poles, and the graft was drilled in similar manner: sutures of No. 2 chromic gut were threaded in these holes. The gauze packing inserted to control hemorrhage was now removed, and the graft inserted with fat resting against the brain. The retention dural sutures were tied first, and the two retention bone sutures were tied next. The graft fitted snugly in position, there being left a small slit between the graft and the skull defect anteriorly and a smaller one between the graft and the skull defect posteriorly. The scalp flap was now replaced and sutured with interrupted sutures of silkworm-gut. At the close of the operation the patient's pupils were contracted (1-16-inch) and reacted to light; they were of equal size.

Postoperative Note (January 15, 1918).—It is now nearly six weeks after the second operation. The bone graft has incorporated itself with the skull. As to motor improvement the patient can move his left arm through a wider range, and the intention tremor has disappeared. The finer movements of the fingers have not returned yet. He is able to move his left leg to limited extent and can walk with a cane.

The advantages of the combined fat-fascia-bone graft in this case are obvious. Fat is the tissue best adapted for contacting with the brain substance and serves the double purpose of controlling hemorrhage from the latter primarily and later of preventing adhesions between the cortex of the brain and the sutured duraplasty area. The deep fascia and periosteum are tissues homologous with the dura in structure and in function. The endosteum and medullary substance were removed from the graft to prevent bone formation beneath the scalp. By maintaining these three layers of tissue still connected and in normal relationship with one another favorable conditions of nutrition could be early and readily established.

The following extract, culled from the literature of war surgery, is of interest in connection with this case:

C. Villandre, writing upon the repair of cranial defects (*Presse méd.*, 1917, 300), has, during ten months, personally operated upon 106 cases of loss of cranial substance. The procedures employed were: (1) cartilaginous cranioplasty; (2) osteoperiosteal grafts taken from the tibia; (3) sterilized bone plaques; (4) paste composed of carbonate and phosphate of lime for small breaches.

The statistical results of the four procedures are as follows: Osteoperiosteal grafts, 32 successes in 32 cases, or 100 per cent.; cartilaginous cranio-

A FAT-FASCIA-BONE TRANSPLANT FOR DEFECT OF SKULL

plasty, 46 successes in 48 cases, or 96.8 per cent.; sterilized bone plaques, 18 successes in 22 cases, or 81.8 per cent.; lime paste, 2 successes in 4 cases, or 50 per cent.

A graft of living substance—bone or cartilage—removed from the patient himself and at a distance from the site of the loss of substance, is therefore the most practical and the surest method of repairing a loss of cranial substance.

As regards the question of ablating portions of the altered cerebral cortex we cite from the following not dissimilar case of Kalb (*Deutsche med. Wchnschr.*, 1917, No. 5), which was that of a boy fourteen years old who for ten years had been epileptic. There was a history of infantile cerebral paralysis. In the pre- and postcentral gyri there were numerous brown-red patches of infiltration containing in certain parts small cysts.

“As complete extirpation of the altered zone would have resulted almost certainly in total paralysis of the right limb, I dissected out from the altered parts small islets varying in size from a lentil to a pea and for a depth of 5 mm. About a dozen such were removed, constituting about two-thirds of the altered parts of the grey matter. Islets of normal cortex remained. There was some language disturbance following operation, but after a week this as well as the limb paralysis improved. After four weeks the patient could walk with the aid of a cane. After one year and a half psychic phenomena have disappeared; the general intelligence is better and the patient can walk for some hours.”

DR. CHARLES H. FRAZIER remarked that cranioplasty was one of the most popular topics of discussion in the surgery of the war zone. Many articles are to be found in literature bearing upon this subject. The points which are of principal interest to the surgeons of the war zone to-day seem to be (1) as to whether the defect should be repaired; (2) when it should be repaired; (3) how it should be repaired.

Whether the defect should be repaired depends to a large measure upon its size. Apparently there is a unanimity of opinion that if the defect be large it should be repaired. Many patients so afflicted have a great many subjective phenomena, as in the case just reported by Skillern, which they attribute to the presence of the defect. There are a few surgeons and a few neurologists who are disposed to believe that in epilepsy it is wiser to leave the defect alone, on the ground that anything which tends to increase intracranial pressure acts as a predisposing factor. This phase of the subject is too large to dwell upon here. Suffice it to say that there are two schools, one which believes that epilepsy is due to increased intracranial pressure, the other that increased intracranial pressure is an accompaniment but not the cause of the seizures.

Regarding the time at which defects should be repaired, there seems to be an almost unanimity of opinion that operation should not be done until at least eight weeks after the wound has entirely healed. In the speaker's opinion, it should not be done for six or eight months after the accident because the incidence of infection is too great when the operation is per-

formed sooner, that is in case of gunshot wounds that were, as most of them are, the seat of infection.

As to how it should be done—this is a matter of comparative simplicity. The repair of defects with bone or cartilaginous grafts is one of the simplest of surgical procedures. He had had a number of cases in his clinic at the University Hospital, and in these he had practised a modification of the technic of the so-called König-Müller operation. The graft is removed from the parieto-occipital region and is composed of the pericranium and outer table of the skull—not the entire thickness of the skull nor the pericranium alone; it is necessary to remove only a thin shell of bone. The graft is transferred to the defect, the margins of which have been previously freshened, dura freed from the margins and in some instances removed. In the course of six or eight weeks one finds consolidation at the site of the defect complete.

With regard to the technic which seems to be popular in the war zone, particularly with the French surgeons, cartilage is used rather than bone. Cartilage does not become absorbed, it does not shrink, it maintains its vitality and merely changes its residence from one part of the body to another. The supply is secured from the cartilage of the ribs. Some surgeons have taken bone grafts from the tibia or scapula, some from the scapula of the lower animals; some have used the König-Müller operation, some of the skulls of those that have been killed in action, others foreign material such as ivory and silver plates.

The points that have been emphasized in the technic are the following: In the first place the graft should be autoplasmic rather than homoplasmic or heteroplasmic. His results with the bone graft justify the employment of bone, although cartilage may be more readily obtained and answers the purpose quite as well. The defect must be carefully prepared—this includes freshening of the margins, the freeing of the dura from its adherence to these margins. When the dura is incorporated in a thick scar and the latter is adherent to the cortex, he excises it, scar and dura together. The graft should be laid in the defect with its smooth surface toward the brain. Usually he has fixed it in place with a few interrupted sutures through the pericranium. Some surgeons place the margins of the graft between the dura and the bony margins of the defect, some make a trellis-work with catgut sutures passing across the defect. Hæmostasis is regarded as a *sine qua non*, and if it is not possible to control bleeding from all sources, a drainage tube should be used. Some surgeons recommend the exposure of the defect with a crucial incision, although he prefers a horseshoe-shaped flap.

The results of cranioplasty, from the standpoint of the repair of the defect, are almost universally good. He had seen reports of cases where, in removing the graft from the tibia, the latter has been broken or the wound became infected, but these are complications that should have been avoided. Insofar as the operation affects the relief of such symptoms as headache, dizziness and the like, possibly more than half of them are successful. Statistics vary as to the influence of the operation as a prophylactic or in relieving epilepsy. On the whole, reports more than justify the undertaking.