

# TRANSACTIONS OF THE PHILADELPHIA ACADEMY OF SURGERY

*Stated Meeting Held November 6, 1922*

The President, DR. JOHN H. JOPSON, in the Chair

## CHRONIC EMPYEMA

DR. NORMAN S. ROTHSCHILD presented a woman, aged twenty-four years, who was admitted to the Medico-Chirurgical Hospital, service of Dr. John H. Jopson, January 21, 1922, with the following history:

Had lobar pneumonia three and one-half years ago. Three days after onset, she began to have pleuritic pain. Two days later pus was aspirated from the chest and a rib resection was performed. Drainage tube was pulled out by the patient the next day. Several months later, there was marked purulent discharge from the wound, which has continued up to the present time. A year and a half before admission chest was reopened and it has been draining since that time. When admitted the lung expansion was limited on the left side. Tactile fremitus is greatly diminished on the entire left side. Percussion note is flat—more marked posteriorly. Breath sounds are distant throughout the posterior surface of the left chest and laterally below the level of the fifth rib. No râles heard. There is a sinus at the level of the sixth and seventh ribs posteriorly in the post-axillary line, which is discharging greenish pus, which on examination contained a Gram-positive diplococcus and diphtheroid bacilli.

X-ray examination revealed the entire lower half of the left chest to be of a density sufficient to consolidation, due largely to the pleural thickening, with some exudate. Injection of the sinus reveals a cavity approximately 7 cm. in depth and about 3 cm. in width.

Operation on February 1, 1922, consisted of a resection of the seventh and eighth ribs on the left side. At this time the exploration of the cavity revealed it to extend to the clavicle above and to the eighth rib below. About one quart of pus was evacuated. Dakin tubes were introduced at the time of operation, 75 c.c. of Dakin's solution being injected every two hours during the day and every four hours at night following operation. Six days after Dakinization, twenty-nine organisms per oil immersion field were found. Eight days after Dakinization, twenty-four organisms per oil immersion field were found. Culture of the Dakinized cavity revealed staphylococcus aureus and few diphtheroid bacilli. Seventeen days after operation, nineteen organisms per field were found. A gradual reduction was obtained and on the fifty-ninth day only two per field were observed. Fifty-eight days after operation patient developed a severe dermatitis and Dakinization had to be stopped. Sixty-three days after operation Dakinization was resumed

as dermatitis had somewhat subsided. Capacity of the cavity was ninety cubic centimetres. Smear count was four to a field. Culture from the depth of the wound was negative. Sixty-eight days after operation three organisms per field were found. During this period patient's general health was improving. Temperature was subnormal in the mornings and normal in the afternoons.

On April 25th, eighty-four days after this operation, patient had a hemorrhage into the pleural cavity, which was evidenced by blood-soaked dressings. This was apparently controlled by horse serum. On May 17th, 106 days after the operation, the first stage of the Keller operation was performed under nitrous oxide and ether anæsthesia. A U-shaped incision was made extending from the fourth rib parallel to and behind vertebral border of the scapula, curving down to the eighth rib and then anteriorly to the sixth rib in the anterior axillary line. The fourth, fifth and sixth ribs were resected. (The seventh and eighth had been resected at our first operation.) Muscles attached to the vertebral border of the scapula were severed near their vertebral attachments and were folded and sutured under the skin. The roof of the cavity was completely exposed. Parietal pleura was removed. The cavity was packed and the upper and lower margins of the wound were sutured. Three days later the packing was removed under nitrous oxide anæsthesia. Dakin tubes were inserted. Dakinization was again resumed. Blood count at this time was 3,150,000 red blood cells, 9400 white blood cells, 50 per cent. hæmoglobin. Differential counts showed 50 per cent. polymorphonuclears, 35 per cent. small lymphocytes, 3 per cent. large lymphocytes, 2 per cent. transitionals and 1 per cent. eosinophils.

On June 20th, thirty-four days after the first stage of the Keller operation, smears showed an occasional bacillus and culture showed bacillus pyocyaneus. On June 28th, forty-two days after the first stage, the second stage operation was performed. An incision was made just outside the margin of the granulation tissue of the old wound. The granulation tissue was removed. The skin which had been folded over the muscles of the outer wall of the chest at the first operation was dissected up uncovering them. The visceral pleura was considerably thickened. The cavity was clean and free from pus. Part of the visceral pleura measuring about three by four inches was dissected from the lung. The remainder was incised in criss-cross incisions. The latissimus and other muscles were loosened from the under surface of the scapula and the resulting flap was sutured to the floor of the cavity. The arm was brought to the side and the edges of the wound at the upper and lower ends were approximated with silkworm-gut sutures. A large perforated sheet of rubber dam was placed into the wound and the opening was then packed with gauze, the whole being forced to the bottom of the wound.

Seven days after this operation the dressings were changed and there was considerable greenish, watery discharge from the wound. Eleven days after this operation Dakin tubes were inserted and Dakinization of the wound was begun. From this time the discharge decreased in

## FRACTURE-DISLOCATION OF LUMBAR VERTEBRÆ

amount. On August 2nd, thirty-five days after this operation, tubes were removed. On August 6th patient was discharged from the hospital with very little drainage. Subsequent examination of the patient revealed that the wound is completely closed and that the movement of her left arm, which following the second operation was considerably impaired, is now returning to normal, although she cannot completely elevate the arm. Her general condition is excellent, and there is surprisingly little deformity of the chest visible, following this extensive resection of its wall. She is stout and the considerable amount of subcutaneous adipose tissue conceals to a certain extent the chest collapse. The result leaves little to be desired. It will be noted that in this case the major part of the wound was left open after the second stage operation and muscle implantation. Colonel Keller, operating step by step, according to indications and the patient's resistance, completes his technic by secondary skin suture, the ideal method. In this case such suture was not done and the wound healed by granulation. At the time of this operation we had not had access to the published reports of Keller's work, giving the full details of his admirable technic.

## FRACTURE-DISLOCATION OF LUMBAR VERTEBRÆ

DR. JOHN B. WOLFE presented a man, thirty years of age, born in Austria, immigrated in 1907; father living and well, age sixty, mother died at thirty-six following childbirth; one brother and three sisters living and well. Patient denies previous disease or injury, is married; five children are living and well, the oldest is ten years of age, the youngest born April 11, 1921. Occupation always that of a laborer. He was a moderate user of beer and wine. He was injured March 18, 1921, while loading a car of coal in the mines by a fall of rock, which struck his back, hurled him to the ground, jamming his head forcibly against the mine car with resultant deep laceration of the scalp in the left frontal region; marked shock, undoubtedly augmented by exposure to cold during the two hours required to extricate him, and motor paralysis, which was total and complete from the waist down. He was transported to the hospital, lacerated scalp was sutured and healed without further complications. Primary treatment was directed to shock, which was extreme for forty-eight hours, which seriously threatened the life of the patient and which precluded all thought of surgical interference. An air mattress was employed and every precaution taken to prevent bed-sores—fortunately none developed.

At the end of the first week there was continued total and persistent motor paralysis with loss of reflexes; sensation was impaired but sphincter control maintained. There was a large hæmatoma overlying the site of injury. A rather unsatisfactory X-ray (taken with portable outfit) showed so much vertebral fracturing that any pressure or manipulation was deemed dangerous. Accordingly a Buck's extension was applied to both legs, as much as thirty pounds being used at times with counter-extension to the head. Extension was maintained for eight weeks in the hope of attaining the maximum of reduction, and after the second week improvement in motor function was apparent almost from

## PHILADELPHIA ACADEMY OF SURGERY

day to day; the right leg and thigh responding first, the left more slowly, the peroneal muscle group in each leg being the last to become normal. Passive movements, electricity and massage were instituted after three weeks and a splint used from the outset which maintained the foot at a right angle and prevented stretching of tendons or contractures of muscle groups.

Röntgenological examination on June 3, 1921, showing a crushing fracture of the third and fourth lumbar vertebræ with displacement of fully one-half the width of the vertebra of the caudal end to the right and with anterior displacement of the third lumbar vertebra upon the fourth the depth of the vertebral body. There are also fractures of the lateral processes of the third, fourth and fifth vertebræ, with extensive callus formation especially upon the left side. (Fig. 1.)

Patient was fitted with a brace and began walking on July 1, 1921, and on the 15th walked from the hospital with the aid of a cane. On October 1st there was recovery of power in both legs with, however, a tendency to fatigue, he had practically dispensed with the brace and walked well, being able to do more than a mile before becoming exhausted. During November, he returned to work as "gate-tender" in the breaker and has worked steadily since. At the time of writing (September 26, 1922) color and musculature are good; gait and posture are normal and there is no evidence of paralysis—he swung himself onto a table three feet high for X-ray examination with less apparent effort than the average. There is rather marked lumbar kypho-scoliosis and the site of fracture can be palpated as a bony prominence. He works daily, walking to and from a point one mile from his home and is not especially fatigued at nightfall. Height 5 feet 6 inches; weight 136 pounds; height before injury 5 feet 8 inches; weight 160 pounds. There is fixation of the third, fourth and fifth lumbar vertebræ, otherwise forward, backward and lateral body movements are normal. The knee jerks are still absent. Comparison of X-ray films made September 25, 1922, with those of June, 1921, show marked increase in callus formation, especially in the lateral aspect. The patient's mental attitude is excellent and he notes continued improvement in his condition.

### VOLKMANN'S CONTRACTURE

DR. JOHN H. JOPSON presented a girl, age nine years, who was brought to the Presbyterian Hospital on September 22, 1922, with a fracture near the elbow-joint. The house surgeon diagnosed it correctly as supra-condyloid, and after an attempted reduction was about to dress it in the Jones' position when he noted that the radial pulse was absent at the wrist in the injured arm. With excellent judgment he admitted her to the ward and applied a Thomas splint, dressing the arm in the straight position with light extension to the forearm and hand. The examination the following day showed moderate swelling of the elbow, the radial pulse still absent, but the circulation in the hand and fingers was good. X-rays showed a supra-condyloid fracture about 1 cm. above the epiphysis, the upper fragment presenting a sharp spine

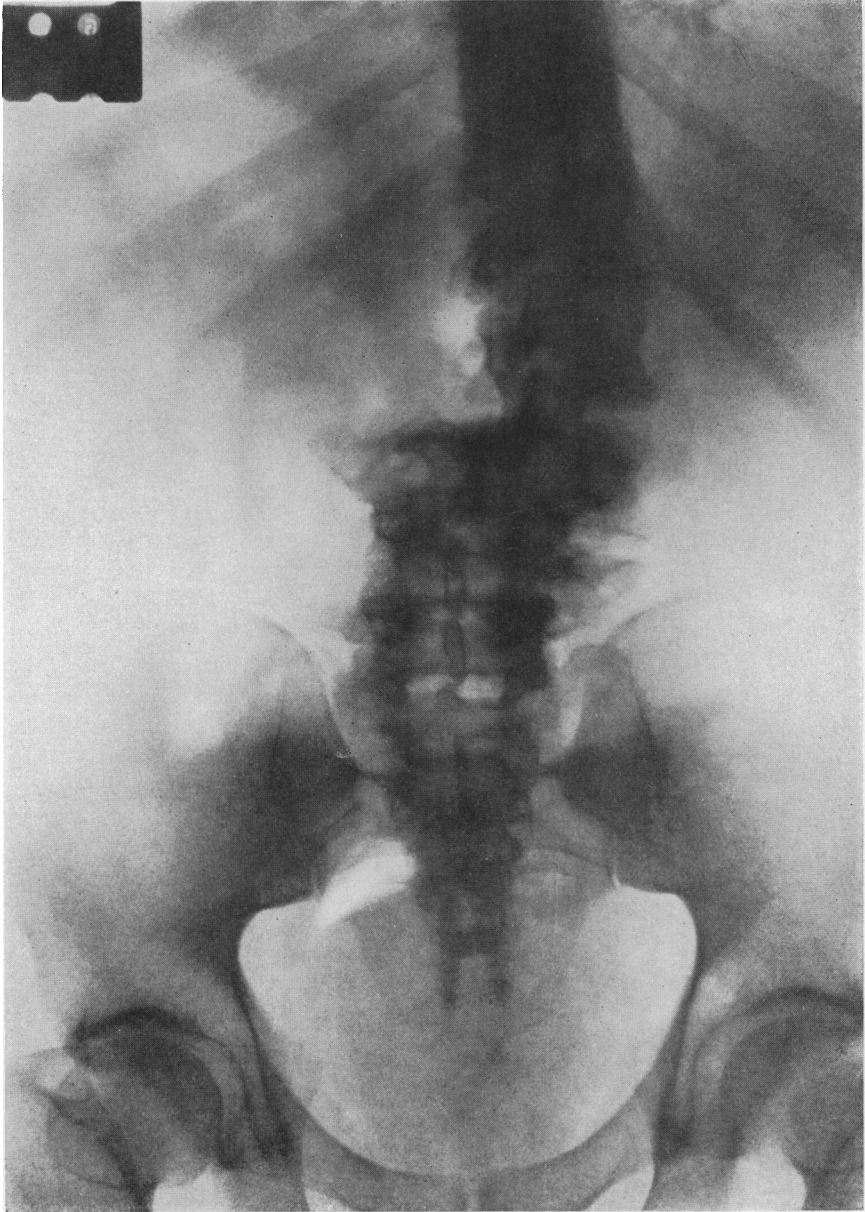


FIG. 1.—Fracture—dislocation of lumbar vertebrae.

## VOLKMANN'S CONTRACTURE

forward, the lower fragment of the joint displaced upward and backward and toward the outer side. Extension was removed and the arm allowed to remain dressed in the suspended Thomas splint. On the second day, circulation still being good in the hand, reduction was attempted under nitrous oxide anæsthesia and the arm dressed on an anterior angular splint. Subsequent X-rays showed no improvement in position. Six days after the accident, the swelling having subsided, open reduction was practiced through an external incision. After reduction the fragments were fixed by one silver wire suture and the arm dressed in flexion in a modified Jones' position. Subsequent X-rays show good correction. About a week after operation it was noted that the wrist and fingers were assuming the characteristic contraction of an ischæmic paralysis. Evidences of nerve injury were lacking, and this was confirmed after careful examination by Dr. Williams Cadwalader, the hospital neurologist. A splint was applied to the hand and forearm, and daily massage was ordered. It is now six weeks since the injury. Union in the fractured bone is complete. There remains some contraction of the flexor muscles of the hand and wrist, which is improving under treatment. The elbow movements are still very limited. There is a firm induration of the muscles on the anterior surface of the forearm and the elbow, which is most pronounced in the flexor and pronator groups in the upper part of the forearm and in the brachialis anticus. The hand and fingers are still supported by a Jones' cock-up splint, and this is removed daily for treatment. The diagnosis is Volkmann's ischæmic paralysis, due to primary brachial artery thrombosis, the result of the injury, and not from the usual cause, namely, tight bandaging. The case is a mild one and the prognosis is favorable for complete recovery.

A very excellent article on this subject by John Jacques Thomas appeared in the *ANNALS OF SURGERY*, March, 1901. Theories advanced up to that time included among its causes arterial obstruction, interference with the return venous circulation, compression, and nerve injury. The last mentioned is regarded by Thomas among others as secondary and contributing, but not a necessary factor. It was present in over one-half of the cases. Tight bandaging is not always a factor. Gibbon has reported one case due to treatment of a fractured elbow in the Jones position. Scudder emphasizes the usual origin of this complication of elbow-joint and forearm fractures as being too great pressure upon the soft parts, causing the characteristic ischæmic myositis. He also admits some cases are due to vessel thrombosis where no splint has been used, and quotes Littlewood to the same effect, the latter including simple extreme swelling of the soft parts and prolonged exposure to severe cold among the exciting factors. As Scudder puts it, "the contracture is the result of prolonged interference with the normal circulation." This is the only case we have seen which was not due to the improper use of splints. It is very clearly due to arterial obstruction, with or without interference, at the same time and from the same cause, with the return venous circulation. The arterial obstruction resulted from the fracture, and not from the after treatment.

## PHILADELPHIA ACADEMY OF SURGERY

### STABILIZATION OF WRIST JOINT BY BONE GRAFT IN SPASTIC PARALYSIS

DR. WILLIAM JACKSON MERRILL exhibited a case of spastic hæmi-plegia involving chiefly the upper left extremity. It is due to a birth injury. The symptoms appeared when the patient first began to use the left arm. The function of this arm has been practically nil and he has carried it in the characteristic position with continuous spasm, increased on any attempt at function. He was subjected to operation January 20, 1920. A graft about two and three-quarters inches in length by about one-quarter to one-half inch in its other dimension was taken from the crest of the tibia to be inserted into the lower end of the radius and into the carpal bones as follows: Incision was made through the skin and subcutaneous tissues in the line of the third metacarpal bone and the mid line of the radius. With a twin saw a groove was cut in the radius and into the carpal bones to receive the graft. The graft was placed in the groove and held in position by a kangaroo tendon. The wrist was dressed in a 45 degree cock-up position and held firmly in that position by a plaster case from the tips of the fingers to the shoulder. The flexor tendons of all of the fingers were completely stretched before the splint was applied. This position was maintained by case for about a year. Substituting the case aluminum metal splints were used for a period of over a year. Subsequently a palmar cock-up splint was worn.

These removable splints were used especially for the purpose of beginning function as well as massage and manipulation. When the arm was carried in its characteristic contracted position the spasm of the flexor muscles of the wrist and fingers seemed to increase the general spasticity of the entire upper extremity, even the deltoid was markedly spastic and the pectorals so markedly contracted that the arm could not be abducted beyond 45 degrees. When the case was removed, the spasticity in the flexor muscles of the fingers was very greatly reduced and the spasticity of the other muscles of the upper extremity was markedly lessened.

Soon after the removal of the splints, after continued massage, manipulation and exercise, the patient began to use the fingers; abduction of the thumb was only about 30 per cent. normal and the extension of the fingers about 80 per cent. of normal.

This range of motion, however, enabled patient to grip objects, tie his tie, lace shoes, hold fork, button coat, and so forth. The stimulus of function seemed to add a great deal to voluntary control also to benefit physically. The improvement continued until function has reached its present range. He now can do practically 70 per cent. of acts in his normal regime, play certain games, even golf, using a left-handed club because of the diminished range of motion of the upper right extremity.

Doctor Merrill said that he had tried arthrodesis on the wrist to stabilize it in the cock-up position but without any great success but with a decided improvement. It occurred to him that if the wrist could be placed in such a position that the extensor muscles of the fingers would have an advantage over the flexor muscles, that they could extend the

## HÆMOLYTIC JAUNDICE

fingers and permit of function and it seems better to gain that function in this manner than to do so by weakening the flexor muscles, thereby diminishing their function. Furthermore, without stabilization of the wrist it was possible again for flexion contracture to take place, which condition seemed to increase the general spasticity. He had also seen marked improvement in spastic contracted wrists and hands after wearing a cock-up splint for several weeks. Naturally when the splint was removed the contracture deformity recurred. The X-ray shows the graft in place and that osteogenesis has been quite active, and the picture indicates that arthrodesis of the wrist and bone graft are capable of holding the hand in its present cock-up position. The wound healed by first intention, the progress of convalescence was unimpaired and the improvement was even more than anticipated.

### HÆMOLYTIC JAUNDICE—TREATED BY BLOOD TRANSFUSIONS

DOCTORS GEORGE M. LAWS AND WILLIAM BATES reported the case of a man, age thirty-six, who, after a series of digestive disturbance extending back some two years, developed severe pleurisy-like pain on the left side. One week later jaundice and weakness began which have steadily progressed, and recently he had had two severe attacks of pain under the right costal margin. Has had an increasing pallor for the past three or four weeks.

The man was a well developed adult who showed some apparent loss of weight, a deep general jaundice, marked scleral jaundice, slight tenderness below each costal margin, and a moderate enlargement of the spleen. Otherwise his physical examination was entirely negative.

On January 31, 1922, he was admitted to the American Hospital for Diseases of the Stomach for observation and treatment. His clinical findings showed a temperature varying from normal to 100° F., a pulse rate varying from 84 to 104, and a respiratory rate of 20. His first blood examination on day after admission showed red blood cells, 1,730,000; white blood cells, 11,200; hæmoglobin, 34 per cent.; a coagulation time of four and three-quarter minutes and a differential of polymorphonuclears 80 per cent., large mononuclears 7 per cent., small mononuclears 12 per cent., and eosinophils 1 per cent.; a negative blood Wassermann and a negative blood culture.

Urine was turbid, yellow, normal odor, specific gravity of 1.015; alkaline reaction; very minute trace of albumen, 0.003 per cent.; absence of glucose, diacetic acid or acetone; a slight excess of indican; a large excess of urosium, and no bile, microscopically there was one hyaline cast, a few squamous epithelial cells, and many shreds with enormous number of triple phosphates.

A gastric analysis—Ewald test meal—36 c.c. removed in one hour, was 50 per cent. solid residue, and was slightly blood tinged. There was a small amount of mucus, a total acidity of 54, a free HCl estimation of 24, and a strongly positive occult blood reaction.

Fæces were also positive for occult blood. X-ray studies were made which showed no pathology of the stomach or duodenum, and no gall-stones.



Dr. O. H. P. Pepper, in consultation, made a diagnosis of hæmolytic jaundice of the acquired or Hayem Widal type as compared with the familial type, and advised blood transfusion at five or six intervals, to be followed by splenectomy if patient's condition improved sufficiently to make the operation reasonably safe.

Eight transfusions were made, seven of them being by the citrate method and by each of these 500 c.c. was injected; the other one was done by the syringe method, and when 30 c.c. had been injected the patient went into shock.

Of the eight donors, all of which were tested by cross-agglutination with the patient's blood, five were direct blood relatives, either brothers or sisters. After none of these five did we have the slightest reaction, and a study of the urine after transfusion showed no erythrocytes, no hæmoglobin, and no bile, except once we had a few red blood cells reported.

Of the other three donors, some reaction followed each transfusion, one of them, previously mentioned, being a severe degree of shock. All three resulted in chills and subsequent rise of temperature. The urine after one of these showed many red blood cells, and after the one leading to shock it showed many red blood cells, considerable hæmoglobin, and some bile for the first time.

The direct result of each one of these transfusions on the cell count was difficult to determine, but at one time the patient was in much better condition than on admission, and the temperature was absolutely normal. At this stage after one more transfusion it was intended to do a splenectomy, but he never again reached a point where it was felt that it could be done with any degree of safety.

During his sojourn in the hospital he had several attacks simulating biliary colic. Repeated examinations of his spleen showed a progressive enlargement during the whole eight weeks. Following one of his transfusions he developed a thrombotic pile, which was exceedingly annoying but apparently not related in any way with his general condition.

On admission there was a complaint of cough which required constant medication, and about twenty-two hours before death he started with an uncontrollable cough which persisted until death.

DR. O. H. PERRY PEPPER said that these cases of hæmolytic anemia merge on the one hand into the familiar group of so-called pernicious anemia, which cases are often not acute or very severe; and on the other hand, into the extremely severe acute hæmolytic anemias which are usually rapidly fatal. It is in this latter group that one especially desires to remove the spleen, for these are the more actively hæmolytic cases. But unfortunately it is in these very cases that transfusion is most likely to be followed by a severe reaction. In other words, the cases which one most wishes to splenectomize are at the same time the cases in which one will have the greatest difficulty with transfusion reactions. The case reported will exemplify this. This case also illustrates the not infrequent occurrence that the early transfusions are followed by no reaction, but after repeated transfusions have been given reactions commence

## EMPYEMA THORACIS

to appear. The blood of the patient reported showed a higher percentage of young cells than in any other case he had observed, and from this it may perhaps be assumed that the hæmolytic process in this patient was extremely active. This suspicion is borne out by the clinical course of the case.

DR. GEORGE M. DORRANCE said that he was accustomed to make the usual grouping test. He also tested blood against blood and believed this to be the proper method. He had had a similar experience where the question came up of using citrated blood or blood direct. He could not find any difference in this particular case. If anything the citrated blood gave less reaction. Lately he had been interested in seeing if it is true that citrated blood gives more reaction than whole blood. If the transfusion is not large he had not found any difference. In cases of a large amount of transfusion citrated blood gives more reaction. Sometimes he gave one transfusion of whole blood and a few days later a transfusion of citrated blood. He never had any tremendous reactions and he believed it to be largely due to the fact that he used old tubes, boiling them over and over again. New rubber tubes will give reactions constantly.

DR. D. L. DESPARD said that he had had a number of very violent reactions from using the citrated methods, very frequently œdema of the lungs, and in one case convulsions and death. For that reason he had not used the citrated blood method for five or six years. He never gave over five or six hundred c.c. by either of these methods. No reaction followed from the direct blood transfusion, and so had abandoned the citrated method.

DR. JOHN H. JOPSON remarked that Doctor Speese had been doing most of his transfusions by the citrate methods, in the Presbyterian Hospital, and he does not get these violent reactions.

DOCTOR LAWS said that this case report might have been entitled: Failure of blood transfusions to prepare a severe case of hæmolytic jaundice for splenectomy.

They were confronted with a patient who was exceedingly ill and they had very little in the literature to help them to gather information as to what was to be expected from transfusions.

### EMPYEMA THORACIS—ANALYSIS OF TWO HUNDRED AND FIFTY CASES TREATED AT THE CHILDREN'S HOSPITAL OF PHILADELPHIA

DR. HENRY P. BROWN, JR., read a paper with the above title.

DR. A. P. C. ASHHURST said that it was his conviction, based largely on the studies of Dr. T. Turner Thomas, that drainage should be made at the most dependent point in the cavity. While he did not go as far as Doctor Thomas does in resecting the eleventh rib invariably, yet he does do so in some cases. Usually he selects the tenth or the ninth, and not in the posterior axillary line, but at a point much nearer the spinal column. The angle of the scapula normally comes down over the eighth rib in the posterior axillary line, and though one may draw the scapula up by elevating the arm during the operation, yet if one drains as high as the eighth rib, the scapula will come down to its normal

site after the operation, and interfere with direct drainage. Moreover, even if the scapula were absent drainage at the level of the eighth rib is not low enough in the pleural cavity.

DR. EDWARD B. HODGE spoke of the various types of infection, for this, he believed, is an important point. The streptococcic cases do much better if aspirated several times, postponing formal drainage until they have recovered from their pneumonia, and until adhesions have had a chance to form, then either intercostal incisions or rib resection may be done, as indicated. The pneumococcic cases are not generally as ill and the adhesions form earlier, so that preliminary aspiration is not as important or necessary, and usually primary rib resection has been the procedure.

He made his incision posteriorly at the angle of the scapula and as low down as the aspirating needle reveals pus, always bearing in mind that the diaphragm comes up higher in children than in adults.

DR. T. TURNER THOMAS, referring to dependent drainage, recalled that years ago, the elder Doctor Ashhurst put in a sound, felt the tip of the sound below and cut down on it. A recent English writer thinks the best place for drainage opening is about the sixth or seventh rib because it is opposite the deepest part of the empyema cavity and therefore the last to be filled in by the expanding lung. Doctor Thomas thought, however, that the lung is driven away from the chest wall and its expansion denied by atmospheric pressure, and that the last portion of the lung to reach full expansion is that opposite the opening in the chest wall because the atmospheric pressure is most effective there. When the drainage opening is down at the bottom and atmospheric pressure acts best there, keeping the lung and the diaphragm away from the opening until it is ready to close.

DR. JOHN B. ROBERTS said that he long ago came to the conclusion that no statistics are worth while if obtained from several operators in a hospital unless they all use the same technic. It is waste of time for good men like Doctor Brown to look up old records; almost every operator lets the after-treatment go to someone else. This invalidates statistics. If one takes 100 cases of operations by one man and has him look after his own patients, the conclusions are worthy of belief. He did not think much of statistics obtained otherwise.

A very large number of empyema cases in adults and children need no serious operation; though the quality and variety of the bacteria make a difference in the disease. He thought that quick incision under local anæsthesia, without resection of the rib, drainage by a tube and good care afterward is the treatment. He uses daily irrigation when the temperature goes up a day or two after the operation. The tube should be gradually shortened and not left in for too long a period.

DR. JOHN H. JOPSON said that Doctor Brown had brought out and emphasized the choice between intercostal incision and rib resection; his statistics distinctly favor the latter operation. While this may seem a trifling difference it is not so. For years Doctor Jopson had followed the work of those of his

## EMPHYEMA THORACIS

colleagues who used an incision only, and he had been impressed by the number of cases requiring secondary operations. He remembered the time when Dr. John Ashhurst, Jr., made two incisions with through-and-through drainage, a different method entirely.

As to the use of Dakin's solution in children, his experience in young children has been that the method is poorly borne. He had found that after the use of Dakin's solution one finds that the child is just "not doing well;" there is a loss of physical strength and a deterioration, the cause of which is difficult to determine. He did not know whether this was due to the repeated irrigation or to some hypersusceptibility to the chlorine solution. Lilienthal mentions having made the same observation.

DR. D. L. DESPARD remarked in regard to the place of incision, one should bear in mind that the object is drainage, and that it should be theoretically at the most dependent point. Most surgeons lose sight of the fact that when the chest is open the diaphragm ascends. He had seen more than one case where the incision had opened up the pleural surfaces which while sealed did not contain pus. He does not think it makes any difference whether one resects or makes an intercostal incision. In the use of Dakin's solution, he had found it very difficult for a nurse with a number of other patients to take care of, to do the Dakinization properly, until a chart was devised which shows in graphic lines the number of bacteria per day, and which also has a space in which the nurse was required to put down the hour in which the irrigation was performed. Since the installation of these charts he had not had any trouble. This was a fairer way to test its use and they have gotten much better results by using it.

DR. J. S. RODMAN emphasized the importance of the bacterial study; the streptococcic cases do better under aspiration, at first, followed by adequate drainage. The pneumococcic cases recovered with almost any type of treatment. As to Dakin's solution, the use of this solution greatly improved the results both as to mortality and morbidity. It is highly important that it be used with the Carrel technic in order that it be brought into contact with all parts of the cavity. In fact in using Dakin's solution anywhere it is essential to remember the necessity of three things—time, concentration and contact. In other words, if a septic cavity is to be sterilized the solution in proper concentration must be brought into contact with all parts of the cavity, at regular intervals. No one who has taken the trouble to use Dakin's solution properly in these cases can fail to be impressed with its rapid bactericidal and solvent properties. With no other method had he seen these cases clear up so quickly, and cases sterilized with Dakin's solution presented almost normally expanding lungs instead of the rigid fixed ones so commonly seen when drainage alone is used.