

TRANSACTIONS
OF THE
PHILADELPHIA ACADEMY OF SURGERY

Stated Meeting Held April 2, 1923

The President, DR. JOHN H. JOYSON, in the Chair

LANE PLATE HEALED IN PLACE

DR. ADDINELL HEWSON presented a bone attached to which was a Lane plate, healed in. The specimen was found on the dissecting table.

SPINA BIFIDA OCCULTA

DR. JOHN SPEESE reported the case of a man, age twenty-eight years, who was admitted to the Presbyterian Hospital, January, 1920, with the following history: Eight years ago while exercising he fell and struck his back. He felt a severe pain and a distinct snapping, which was accompanied by a sensation of lack of support in the lumbar region. The pain was so severe and so continuous that he was confined to bed for several weeks; the distress was relieved by strapping, although a certain amount of pain persisted. X-ray examination showed a defect in the posterior arch of the fifth lumbar vertebra, due to non-fusion of the laminae and spinous processes. The condition was diagnosed as spina bifida occulta and an operation was advised. This was refused, and for the relief of the pain, a brace was made which supported the spine from the shoulders to the hips. A considerable amount of relief was experienced after the application of the brace, but the pain was more or less constant, although not severe in character. For the past eight years he has carried on his profession as a dentist, although the constant standing has caused more or less persistent backache. Any undue exertion increased the amount of discomfort.

On examination a distinct defect (Fig. 1) was felt in the fifth lumbar vertebra, and over this region there was a crescentic growth of hair.

In January, 1920, an operation was performed by Dr. J. E. Sweet and the reporter. An incision over the vertebræ revealed the defect in the fifth lumbar; the ends of the processes were slightly movable and undoubtedly allowed a certain amount of play, which it was thought would account for the pain complained of by the patient. The ends of the defect were freshened, and brought together by kangaroo tendon, the erector spinæ muscle, which had been detached, was then sutured closely to and over the defect, in order to give all possible support to the area. Immediately following the operation, the patient experienced great relief

SPINA BIFIDA OCCULTA

from his pain. He was able to lie on his back with comfort for the first time in many years. Previously, it was necessary for him to sleep on the abdomen, and he was unable to turn in bed on account of the pain which such motion caused. The wound healed by first intention, and in two weeks the patient was up and about. The use of the brace was advised for several months, in order to promote firm union.

Subsequent history: At the end of two months the brace was discarded and the patient was able to resume his profession with very little discomfort. An occasional attack of backache was experienced, however, if he were indiscreet in exercise or exertion; these attacks gradually diminished until after the lapse of a year, he was able to exercise without experiencing any trouble.

DOCTOR SPEESE said that spina bifida occulta may be defined as a congenital cleft or defect in one or more of the spinous processes or laminae of the vertebræ without an external sac being present. The subject was reviewed in 1921 by Christopher (S. G. O., 1921, 33, 1) from whose article the following facts are abstracted: The incidence of spina bifida occulta has been placed

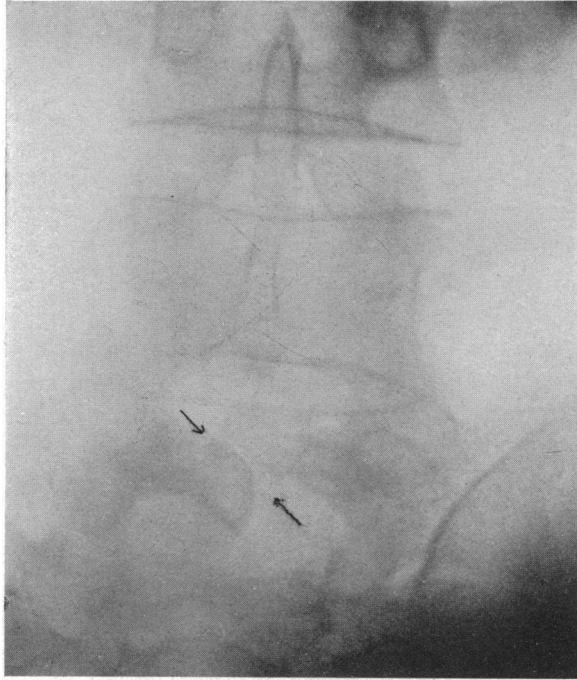


FIG. 1.—Spina bifida occulta.

as high as 5 per cent., but X-ray studies of 1000 consecutive cases disclosed incomplete closure of the vertebral posterior arches in the last lumbar vertebra to be present in 2.3 per cent.

Brickner concludes from his studies that there may be a cleft of varying length or breadth in one or more of the arches accompanied by one of the following conditions:

- (1) A distinct meningocele protruding through the cleft.
- (2) Closure of the cleft by a tough membrane adherent to the overlying skin or non-encapsulated fat and connective tissue.
- (3) Perforation of the membrane by a dense band attached to the subcutaneous tissues externally and compressing the cord structures internally.

PHILADELPHIA ACADEMY OF SURGERY

- (4) Lipomatous tissue within the canal concealed by this membrane.
- (5) Bulging of the dura mater.
- (6) An exostosis within the canal compromising the cord tissues.
- (7) A myofibrolipoma extending through the cleft and into the bony canal, disturbing and compressing the cord and its roots.
- (8) Degeneration of the cord tracts.

Hypertrichiasis over the area of the spine affected is present in the majority of cases, but the defect is not always present in cases of hypertrichiasis. Vesical incontinence has been present in a large per cent. of cases, and enuresis in children is common. Foot deformities are variable, and corns and calluses are frequent.

Pain has been inconstant; it may be present in the region of the defect or even referred to the legs.

A very constant physical sign is the presence of one or two sacral dimples. Congenital lipomata are not uncommon, and scoliosis is frequently encountered.

The treatment is of two general types, symptomatic or palliative, and radical. The symptomatic treatment has been of little use and the palliative results, in many cases, have been unfavorable, owing to the fact that the degenerative and neoplastic processes are unremediable by surgical methods. Brickner believes that the cases in which there is a hernia of the spinal roots probably offer the best chance for a good result. His indications for operation are (1) in infants and children with spina bifida occulta without symptoms, in the hope of obviating symptoms, and (2) in adults with symptoms.

Christopher reports a case which is of interest, in that it seems to show that spina bifida occulta is a potential weakness of the body structure, and that an injury by violence to the sacrum or lower lumbar vertebræ may produce, temporarily at least, such symptoms as are found in some of the well-marked cases of spina bifida occulta with symptoms.

The case now reported resembles Christopher's in that violence caused symptoms to develop in the spine, potentially weakened by a defect previously unrecognized and not causing any disability. In this case, however, there was no loss of control of bladder or rectum. The case is of interest also because a comparatively simple operation relieved the backache apparently by fixing the ends of the processes and thus preventing motion.

SUBASTRAGALOID DISLOCATION

DR. JOHN SPEESE showed an X-ray (Fig. 2) and reported the following case of subastragaloid dislocation which he thought of interest in that the dislocation was unaccompanied by any evidence of fracture. The patient, a woman forty-five years of age, was admitted to the Presbyterian Hospital for an injury sustained in falling down a flight

THORACOPUNCTURE

of steps. The right ankle was much swollen and œdematous on the inner side, the skin was tense and stretched over the external malleolus, the foot being inverted. The astragalus could be felt on the outer side of the dorsum of the foot, and there was great pain on any sort of motion.

Under nitrous oxide anæsthesia the dislocation was reduced with very slight effort. The foot was placed in a fracture box until the marked œdema subsided, and a plaster case later was applied. An X-ray examination at this time showed complete reduction, and nine months after the accident the patient reports that she is able to walk without inconvenience or any degree of disability.

THORACOPUNCTURE FOR REMOVAL FROM LUNG OF PENETRATING FOREIGN BODY

DR. CHEVALIER JACKSON presented a man from whose lung he had removed by thoracopuncture a penetrating foreign body. In connection with the presentation he emphasized the fact that without Doctor Manges and his double plane fluoroscope the procedure would have been very dangerous, if not impossible. With guidance in two dimensions absolute precision obviates unnecessary trauma. He did not regard thoracopuncture as the proper procedure for every aspirated foreign body. Any good bronchoscopist can remove such bodies through the mouth with a bronchoscope; but an unskilled bronchoscopist may need a thoracic surgeon to repair the mediastinum—if the patient survives.

DOCTOR SHALLOW said that the whole question of removing foreign bodies from the lungs had been greatly altered by the War. Previous to that time very little was done in a systematic way. During the period of the War, Duval attacked the problem of the removal of foreign bodies from the lungs by resecting a piece of rib, herniating the lung, isolating the foreign body with the fingers, cutting into the lung and removing the foreign body, controlling the hemorrhage with sutures. Marion suggested suturing the parietal and the visceral pleura if they are not adherent. He penetrated

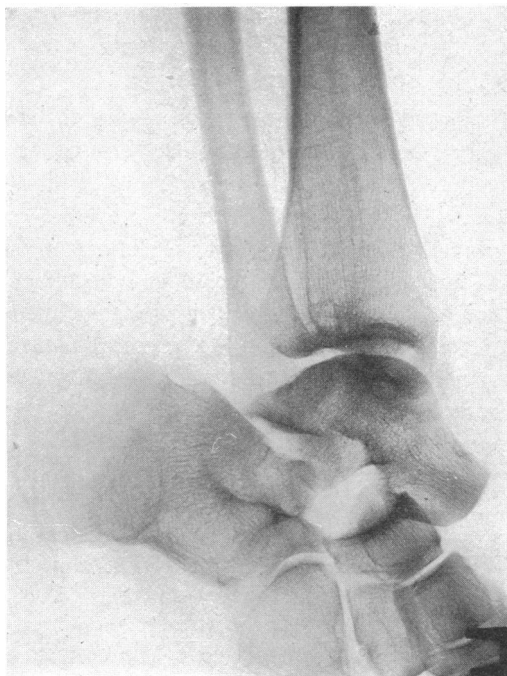


FIG. 2.—Subastragaloid dislocation.

the lung with the finger, isolated the foreign body and passed a clamp along his finger, using the finger as a guide to direct him to the foreign body, and removed it. The bleeding was controlled by a tampon. Mauclair advised the removal of foreign bodies through a small opening. In some cases he resected the rib. He introduced a slender instrument through the chest wall and lung, and, with the aid of a fluoroscope, he removed the foreign body. Marion's technic was modified by Pettit de la Villeon. Under local anæsthesia he penetrated the chest wall and the lung and with the aid of a fluoroscope removed the foreign body. This method is similar to that used by Doctor Jackson in his case.

A case under his own care was associated with a streptococcic empyema. There was a staple in the posterior mediastinum, having been pushed there through the bronchus during an attempt at removal with the bronchoscope. Four ribs over the abscess cavity were resected. After the pus was evacuated it was found that the heart and lung were so adherent to one another that it was impossible to free the lung from adhesions. Under the fluoroscope the foreign body was removed by passing hæmostatic forceps through the lung, after first cutting the thick visceral pleura with scissors. There was not sufficient bleeding in this case to require suture or tampon. The case made a complete recovery.

REPAIR OF LOSS OF BRIDGE OF NOSE AND COLUMELLA DUE TO CONGENITAL SYPHILIS

DR. ROBERT H. IVY reported the case of a boy fourteen years of age who was referred to him by Dr. Benjamin Singer. At various times since birth he had had outbreaks of typical syphilitic lesions. Eight years ago ulceration in the nose resulted in loss of cartilage and bone. He had also been treated for interstitial keratitis. He had active anti-syphilitic treatment until a short time before first seen by the reporter. At this time no active lesions were present and the Wassermann reaction was negative. Examination of the nose showed typical depression of the bridge due to loss of septal cartilage, the skin over the bridge being intact and freely movable. The entire cartilaginous septum, inferior turbinated bones, and columella were gone.

July 7, 1922, under ether at the Polyclinic Hospital, two vertical parallel incisions, 1 cm. apart, were made through the full thickness of the middle of the upper lip, including the mucous membrane. The mucous membrane was removed from the lower end of this flap, and the raw surface sutured to a previously freshened area just beneath the tip of the nose, the columella being thus reconstructed. The divided halves of the lip were then brought together and sutured. Restoration of the columella by this means was first described by Blandin in 1836. No visible deformity of the lip results.

August 25, 1922, the bridge of the nose was restored by a piece of the eighth right costal cartilage inserted beneath the skin through an incision made in the glabellar region.

ANKYLOSIS OF MANDIBULAR JOINT

Healing occurred normally, and the treatment resulted in marked improvement in the appearance of the patient.

DR. JOHN B. ROBERTS mentioned a case in which he used a peg of cartilage, shaped like a nail, to keep the whole of the nose elevated when the columella lacked rigidity.

The point of the seventh or eighth rib cartilage was used and thrust through a slit made in the columella so that the point of the cartilage rested on the upper jaw at the nasal spine.

ANKYLOSIS OF MANDIBULAR JOINT—ARTHROPLASTY

DOCTOR IVY reported the case of a man, aged twenty-two years, who until 1920 never had any trouble with his jaw. In 1920, he had double pneumonia followed by empyema. Complicating this was necrosis of the sternum at the level of the third rib. He had rib resection and drainage on both sides. During this illness there was also a metastatic arthritis of the right mandibular joint, which did not go on to suppuration, but which left him with limited motion of the jaw.

In June, 1921, still unable to open the jaws more than 1 cm., an impacted lower right third molar tooth, regarded as a possible contributing factor in the ankylosis, was removed, and while the patient was under the anæsthetic, the jaws were forcibly opened to a width of about 2 cm. between the upper and lower incisors. Following this, and division of peri-articular adhesions in February, 1922, the former condition of almost complete ankylosis returned.

In October, 1922, it was found that the upper and lower incisors could not be separated more than 1 cm., and that attempts to force the jaws farther apart produced pain in the right mandibular joint. In opening, the mandible seemed to move toward the right side, with the fixed right condyle as a pivot. No outward facial deformity, such as is seen in cases of ankylosis occurring before full growth of the mandible, was visible.

October 13, 1922, at the Polyclinic Hospital, under ether, an incision was made through the skin, beginning below just in front of the lobe of the right ear, passing vertically upward to a point opposite the upper attachment of the pinna, then extending upward and forward in a curved manner to the level of the top of the pinna, then downward and forward to end at a point about 3 cm. in front of the upper attachment of the pinna. The skin flap thus outlined was then turned down. A flap of superficial fascia with the same outlines as the skin flap was now made, the posterior attachment of the masseter severed from the zygoma, and the neck of the condyle exposed. With a narrow gouge, the neck of the condyle was divided, about 0.5 cm. of bone being removed. This permitted free opening of the jaws to the full extent. The end of the flap of superficial fascia was fixed with catgut sutures between the bone surfaces, to prevent them from reuniting, and the skin flap was sutured back in its original position, a temporary rubber dam drain being inserted at the lower angle to prevent accumulation of blood. A wooden wedge was wired between the teeth of the right side to keep

the mouth open, but this gave so much discomfort that it was removed the next day without untoward results.

The patient made an uninterrupted recovery and was discharged from the hospital on October 18.

Since that time he has had full use of the jaw, with maintenance of ability to separate the upper and lower teeth to a normal extent.

Operations for the relief of bony ankylosis of the mandible are not new. In 1855, Esmarch recommended removal of a wedge-shaped piece of bone from the angle, and Wilms of Berlin first successfully performed the operation in 1858.

The first removal of the condyle was performed by Humphry, in 1856. In 1883 Heath resected the neck of the condyle through an incision in front of the ear. Similar operations are described by Gross (1874), Mears (1883), and other American surgeons.

Coming to more recent times, Blair, in *Surgery, Gynecology and Obstetrics*, 1914, vol. xix, p. 436, gives a very exhaustive analysis of 212 cases including several of his own. In 1910, before the St. Louis Medical Society, Blair first presented the operation used in the case reported here. The incision gives free access to the joint and at the same time avoids important seventh nerve branches. With the angular incision described later by Murphy (*Jour. A. M. A.*, 1914, vol. lxii, p. 1783) there would seem to be more danger of paralysis of the orbicularis palpebrarum and certainly of the occipito-frontalis.

DR. GEORGE M. DORRANCE said that he had seen that day two cases in which he had performed arthroplasty within six months. Not only was bony ankylosis present in these cases but the muscles were short and fibrous, much more so than in the normal muscles. In looking over a number of cases he had been impressed with the fact that they recur. Something over a year ago he started in with mechanical exercises of various types. In the two cases now referred to the exercises had been of great value. The ankylosis had existed in these cases from twelve to fourteen years before operation. They had started to ankylose between eight and ten years of age so that the bone was not developed as the adult bone would have been.

The most important thing is that these exercises have kept the distance as long as they were used. When they were stopped, contraction again set in. In all these cases of long duration one should not expect these muscles to get back their function again any more than one would expect an arm to do so after it has been in a sling a long time.

DR. A. BRUCE GILL said that he had operated upon two cases of ankylosis of the jaw. In June, 1919, a boy of seventeen years from Birmingham, Alabama, was brought to Philadelphia by his father because of ankylosis of the jaw which had existed since early childhood. The father had been away from home during the boy's infancy and could give no history of the cause or development of the ankylosis. There was a history, however, of an osteomyelitis of the femur with sinuses which discharged for several years.

ANKYLOSIS OF MANDIBULAR JOINT

The boy presented a very marked retrognathism, or under-development of the lower jaw. His lower teeth in front were fully one-half inch behind the upper teeth, and by means of this orifice the boy was able to introduce meat and other articles of a general diet into his mouth, where he partially masticated them with his tongue before swallowing. There was no perceptible motion of the lower jaw either side-wise or up and down. They were unable to tell by examination, or by means of any inequalities of the two sides of the face, or by X-ray examination which temporo-mandibular joint was ankylosed, or whether both were involved. A small linear scar about one-fourth inch in length in the region of the left joint suggested that an incision had been made at some time, possibly for metastatic abscess following the osteomyelitis of the femur.

Doctor Ashhurst examined the case with him and assisted in the operation. An incision was made along the lower border of the zygoma, going directly down to the periosteum. The incision was carried downward for about an inch in front of the ear. The soft tissues were retracted downward, exposing the region of the joint. No line of demarcation of the joint was evident. There was bony union of the entire width of the mandible, including condyle, coronoid, and sigmoid fossa, with the glenoid fossa and the zygoma. The ramus of the jaw was divided with biting-forceps and osteotome across its entire width below the zygoma without injury to neighboring vessels or nerves. The jaw could then be opened about an inch. When the jaw was closed there was a gap of about one-quarter of an inch between zygoma and mandible. The wound was closed and healed promptly.

A hard rubber screw was used during the after-treatment to force the mouth open more and to maintain the opening, but its use was more or less painful and caused loosening of the teeth. Many of the back teeth were unerupted.

The boy left for home at the end of a month able to open his mouth about one inch and to close it again. There was no soreness in the muscles of mastication nor about the joints.

He returned to Philadelphia at the end of five months because of a relapse and inability to open the mouth.

A second operation, similar to the first, was done. Bony ankylosis was present. Three-eighths of an inch of bone was excised. The mouth could then be opened an inch, when it was observed that the bony gap increased to beyond a half-inch. A free transplant of fat from the thigh was then placed between the bones and wound was closed.

Following this operation several rubber wedges of different sizes were employed to keep the mouth open. It was found, however, that there was no tendency to relapse, as after the first operation, but that there was constant improvement in the use of the jaw and without pain. Voluntary motion increased from three-fourths to five-fourths of an inch during the following month. The patient reported some time after his return home that he had good motion in his jaw and that he was entirely satisfied.

The second case was that of a colored girl of fourteen years with

complete ankylosis dating from infancy, cause unknown, marked retrognathism, and again no sure indication by inequality of the face or by X-ray examination as to which joint was ankylosed. Operation was performed on the right side, when a bony ankylosis between mandible and zygoma was found extending from the condyle almost to the tip of the coronoid process, with obliteration of the sigmoid notch. With osteotome and mallet a gutter was cut across the mandible just below the zygoma, and the opening was enlarged with rongeur forceps to a width of five-eighths of an inch. The jaw could then be opened almost an inch. A free fat transplant from the thigh was placed between the bones, and the wound was closed.

A dental instrument consisting of hinged plates for the upper and lower teeth with a screw was obtained and used in the after-treatment.

This patient gained steadily in the use of her jaw and obtained a splendid result.

From these cases he learned that it is better to interpose soft tissue between the raw bony surfaces to prevent relapse, and that one is not always able to tell by any means of examination on which side the ankylosis is present. The operation by means of the method described is easy and is free of danger of injury to vessels and nerves if one uses precaution and gentleness.

DR. J. T. RUGH said that last year he had the pleasure of seeing one of the cases which Doctor Mears did many years ago. The patient is now a physician in Western Pennsylvania. He still has excellent function in the jaws as the result of that operation. It seemed to him that one of the greatest things that Murphy has shown has been the uncertainty of arthroplasty. Subsequent studies of his cases show recurrence of the ankylosis, not only in the jaw but in other parts of the body. The results of arthroplasty can not be estimated until three or four years have passed. This result of Doctor Ivy's is beautiful, but it is only at the end of seven or eight months. The speaker wanted to know what the result is at the end of three or four years. All surgeons know what it is to have recurrences when dealing with bony ankylosis.

DR. JOHN H. JOPSON said that these are not very common cases. Dr. J. Ewing Mears, a former President of the Academy, was a pioneer in this field, and showed several cases at a meeting many years ago. Mears' work ought to be kept in mind and the part that he played in helping what seemed almost an incurable deformity at that time. John B. Murphy's report before the American Surgical Association in 1914 also should be recalled. The speaker had operated on and exhibited one case here, a case of double ankylosis, treated by the Lilienthal method, including osteoplastic resection of the zygoma. The cosmetic result was inferior to that obtained by Doctor Ivy, which is the best he had seen; but the functional result was excellent. If the ankylosed joint is thoroughly resected and this followed by an arthroplasty along modern lines, one should not expect a recurrence.

DOCTOR IVY, in closing discussion, said that the determination of which side

TREATMENT OF WEBBED FINGERS

is ankylosed generally presents little difficulty. In cases of long standing a careful study of the deformity due to lack of use will frequently determine this point. The ramus of the mandible on the ankylosed side is usually shorter vertically, giving that side of the face a full, rounded appearance, whereas the opposite side is flattened. Mistakes, however, have frequently been made, the flattened or sound side being opened first because it looks more abnormal than the other. The X-ray generally gives very little aid on this point.

If the jaws do not open by free removal of bone on both sides, the remaining ankylosis is due to contracture of the soft tissues and these must then be divided or removed as far as is necessary. One case seen in the army was due to myositis ossificans of the masseter muscle, requiring complete excision of the muscle.

It was undeniable that final conclusions as to the result of operation in these cases could not be reached until at least two years have elapsed. They practically all require the use of muscle exercisers to maintain mobility.

TREATMENT OF WEBBED FINGERS

DRS. G. M. DORRANCE and J. W. BRANSFIELD read a paper with the above title, for which see page 532.

DR. A. BRUCE GILL said that he had operated on a few cases of congenital syndactylism, and obtained fair results by a plastic operation. The skin on the dorsum of the hand is very loose, and a triangular flap with the apex at the web of the fingers can be drawn downward to cover not only the raw surface between the fingers, but also part of the side of a finger.

One should not operate on infants or young children probably before the age of ten or twelve years, because the scar on the lateral surface of the fingers contracts and causes a lateral bowing of the fingers. The fingers are so small and the scar so relatively large that deforming contracture cannot be prevented.

DOCTOR DORRANCE said he had had no experience at all with children. The simplicity and success of this method came to his notice in the army, after explosions where the whole hand would be burned. They put these grafts on and thought they had remarkably good results. It is a local anæsthesia job, simple and easy. The only trouble with flaps from the abdomen is that they are liable to take on fat and for this reason they had not been entirely satisfactory to him. They had been making their grafts a little thicker recently, they are half-way between a Wolf and an Ollier-Thiersch method. In burn cases this method has been particularly satisfactory.

DR. JOHN H. JOPSON said that he had found the Agnew or Zeller operation a good one, but in operating in young children it has the fault that it does not provide for early healing of the lateral incisions on the fingers beyond the web. Scars at these sites do not grow proportionately to the growth of the hand, and the resulting contraction draws down the interdigital fold of skin and results in partial relapse. The method recommended by Doctor Dorrance obviates to some extent this difficulty.