

TRANSACTIONS
OF THE
PHILADELPHIA ACADEMY OF SURGERY

Stated Meeting Held October 1, 1923

The President, DR. JOHN H. JOPSON, in the Chair

BRACHIAL PLEXUS ANÆSTHESIA FOR AMPUTATION OF
FOREARM IN A PATIENT WITH ADVANCED PHTHISIS

DR. ASTLEY P. C. ASHHURST reported the case of a woman, twenty-two years of age, who came under his care in the Orthopædic Hospital in March, 1922. She was suffering from an advanced stage of bilateral pulmonary tuberculosis, and had developed about eighteen months previously, tuberculosis of the left wrist joint, following about six months after a severe sprain. The wrist lesion had advanced rapidly, an abscess had broken more than a year previously, and four sinuses were present when first seen. The hand had been utterly useless for a year, and was constantly painful. The patient asked that it be amputated, even before the surgeon had an opportunity to explain that this offered the only chance of relief.

The pulmonary condition contra-indicated a general anæsthetic by inhalation, and as the patient was too weak to sit up, in the approved fashion for injecting the brachial plexus subcutaneously, the plexus was exposed March 25, 1922, by local infiltration anæsthesia with novocain one-quarter per cent. (morphin and atropin having been given hypodermically): incision 5 cm. long above the left clavicle; fat dissected; omohyoid drawn upward; internal jugular vein retracted medially. Brachial plexus exposed, and six hypodermic syringefuls (about 12 c.c. in all) of novocain one-quarter per cent. were injected among its trunks, infiltrating the surrounding fascia. The wound was closed with buried and skin sutures. The time required for exposure, injection, and closure of the wound was ten minutes.

One-half hour later, an Esmarch band was applied over a towel below the deltoid muscle, after the arm had been held elevated for a period of three minutes. Amputation was then done at the middle of the forearm. The entire procedure was painless, except retrenchment of the median nerve, which had been haggled at its primary division. A momentary sharp pain was experienced when it was drawn down and again divided. The stump was closed with buried and superficial sutures without drainage. The time required for the amputation was 15 minutes.

The patient promptly began to improve after the removal of the suppurating limb; she was able to resume her housework, but died of phthisis about a year later.

EXCISION OF A CERVICAL RIB

EXCISION OF A CERVICAL RIB

DOCTOR ASHHURST presented a woman, twenty-five years of age, who was admitted October 5, 1922, to his service at the Episcopal Hospital. Her chief complaint was pain in the left shoulder, arm and neck. Her previous personal history was irrelevant. In June, 1922, a friend called her attention to a swelling in the left supraclavicular fossa. She came to the Surgical Dispensary of the hospital on June 26, where Doctor Brown suspected the existence of a cervical rib, but when X-rays were made of her neck, neither an antero-posterior nor a lateral view showed any abnormality. In July, she began to experience pain in the arm and shoulder, and the left side of the neck felt stiff and tight from the ear down. She thought the swelling had been increasing in size, and her own physician told her the same.

Examination was negative except for the neck. In the left supraclavicular fossa, inspection showed a swelling about 2 cm. above the junction of the middle with the outer third of the clavicle. Above this swelling, the jugular vein was visibly distended. On palpation the mass was found to be dense, like bone, and was round and smooth, the skin not adherent. Two bony processes extended from this mass—one went upward and mesially, and did not seem to be attached to the lower process which ran downward and mesially to disappear beneath the middle of the clavicle. A diagnosis of cervical rib was made and the patient referred for further X-ray examination by Dr. R. S. Bromer, who found (Plate 14, 143) a definite left cervical rib, which at the first X-ray examination had been hidden by the shadow of the first rib. The cervical rib ran from the left transverse process of the seventh cervical vertebra to a facet on the anterior surface of the first rib. The right transverse process of the seventh cervical vertebra was abnormally large.

Operation, October 7, 1922, intrapharyngeal ether. An incision 12 cm. long was made in a skin fold about 2 to 2.5 cm. above the left clavicle. The external jugular vein was doubly ligated and divided, and the posterior margin of the sternomastoid drawn forward. The omohyoid muscle was divided. The subclavian artery lying high in the neck, and running downward almost parallel with the usual course of the common carotid, was identified easily by the fact that pressure on it checked the radial pulse. It was dissected free and drawn forward. The brachial plexus was dissected free and drawn backward. Between these two important structures the most prominent part of the cervical rib was identified, covered with cartilage. The rib was thence traced backward almost to the vertebral column, and there divided with bone forceps. Next, by retracting the subclavian artery laterally over the cervical rib, the anterior end of the latter was found inserting into the first rib, beneath the clavicle, near the sternum. The lung was in plain view through the transparent pleura. It was impossible to distinguish between the lower border of the cervical rib and the upper border of the first rib. So, to make certain that all the cervical rib was removed at its anterior end, the upper border of the first rib was resected also with forceps, and the two were removed in one piece. It was then found that a movable joint was present between the end of the cervical rib

and the upper border of the first thoracic. As the rib was withdrawn from the wound, there was a sound as of air entering the pleural cavity, but no symptoms occurred. The rib was removed with its periosteum intact. The platysma and skin were closed separately. The operation lasted one hour.

There was no pain at all from the time of the operation, and at no time were there any evidences of motor or sensory disturbances from nerve injury. Doctor Ashhurst said he was rather surprised at the entire freedom from nerve lesions, as Dr. Alfred S. Taylor, who had reported a number of operations for cervical ribs, and who was quite accustomed to doing operations on the brachial plexus, had found them of nearly constant though usually temporary occurrence after the removal of cervical ribs. Doctor Taylor (N. Y. State J. of Med., 1922, vol. xxii, p. 97) writes: "The operation is difficult, is apt to be quite bloody, and is frequently followed for a varying period of time by more or less paralysis of the extremity which results from operative traumatism to the plexus. Were it not for these objections," continues Doctor Taylor, "which a review of the literature shows to be very real, there could be no question that operative treatment should be the method of choice." Doctor Taylor adds that leaving the head of the rib *in situ* has seemed to cause no late disturbance, but that it is important to remove the rib right up to the head because there might otherwise be continuing irritation of the seventh root. He points out that the shorter the rib, the more apt is such irritation to occur, because the very rudimentary ribs have their broadest surfaces in the coronal plane, with sharp borders above and below. In such short ribs, he approaches them from the lateral or posterior border of the brachial plexus; in longer ribs he excises the anterior portion first from the median side of the plexus, and then goes lateral to the plexus to remove the stump which remains.

It is true that in the present case the vertebral end of the rib had not been completely removed, a small segment still being articulated with the transverse process of the seventh cervical vertebra; but this was well above the region where the nerve caused pain from pressure on the brachial plexus.

SPONTANEOUS (?) FRACTURE OF CLAVICLE; RESULTING CALLUS MISTAKEN FOR TUMOR

DOCTOR ASHHURST also presented a boy, seven years of age, in whose right clavicle a lump had been first noticed on August 26, 1922. There was no history of any injury and there had been no disability at any time. The patient was sent by Dr. A. V. Moschcowitz of New York, with a tentative diagnosis of malignant growth, with pathological fracture.

Examination on September 5, 1922, showed a perfectly healthy and unusually intelligent boy, physical examination of whom was negative except for the lump on the right clavicle. This was situated about 3 cm. from the sternal end, was prominent, about 2 cm. in diameter, attached to the clavicle, and of cartilaginous consistency, not bony hard.

CERVICAL LYMPHADENITIS SIMULATING A TUMOR

It was tender on firm pressure. Skiagraphs which he brought with him, made in New York, showed a fracture (pathological?) of the clavicle, with rather spotty looking bone. The callus or tumor did not show in the skiagraphs.

X-rays made September 11, 1922, at the Episcopal Hospital, by Dr. R. S. Bromer, showed callus forming around the fracture in fusiform shape, in excess of the normal for fracture repair, and greatly in excess of the normal for any fracture without displacement and apparently subperiosteal. Doctor Bromer, however, did not see anything which indicated the presence of a tumor.

Operation September 12, 1922.—An incision 12 cm. long was made over the right clavicle, detaching the pectoralis major, sternomastoid, and subclavius muscles, without opening the periosteum. The sternoclavicular joint was opened, and the clavicle was raised, and divided at the junction of the middle and outer thirds by means of bone forceps, and the fragment was removed. A second incision, 15 cm. long, was made over the right fibula, the middle third of this bone being exposed posterior to the peroneal group of muscles. The periosteum was reflected, and an aperiosteal transplant, 7.5 cm. long, was removed by bone-cutting forceps, and the leg wound closed. The transplant was inserted in the defect in the clavicle, its sternal end being fixed to the sternum by No. 2 chromic gut sutures passed around the entire transplant and perforating the sternum. The remainder of the transplant was imbedded beneath the sternomastoid and pectoralis major muscles. Its distal end did not quite touch the scapular fragment of the original clavicle as the patient lay with his shoulder stretched over a sand bag. After closure of the incision a T-shaped splint was applied to the back, holding both shoulders back against the transverse bar.

September 18. The patient was discharged from the hospital.

October 5. The T-splint was discontinued, as the clavicle seemed to be united, and its scapular end in apposition with the transplant.

October 1, 1923. Thirteen months since operation. The right clavicle is less than 0.5 cm. shorter than the left. Its sternal end is firmly attached, but at the junction of the transplant and the scapular end there is only fibrous union. There is no pain or tenderness and no disability of any kind.

Pathological Report.—The specimen, consisting of the inner two-thirds of the right clavicle, was sawed in two, lengthwise, exposing a line of fracture, with recent callus forming in excess about it. Microscopical examination by Dr. C. Y. White failed to show any evidence of tumor formation; merely normal bone with a line of cartilage traversing it, as might be seen in any uniting fracture.

CERVICAL LYMPHADENITIS SIMULATING A TUMOR

DOCTOR ASHURST related the history of a man, thirty years of age, who came under his care in the Episcopal Hospital in October, 1922. His family and previous histories were negative, and his chief complaint was a lump on the left side of his neck, and stiffness of the neck. This lump was first noted about the first of August, 1922, and was then

about the size of a pea. By the middle of September, it had grown so large that he applied to the Frankford Hospital, where he was seen by Dr. Chas. F. Nassau. Doctor Nassau, according to the patient, made a diagnosis of malignant tumor, and recommended that no operation be attempted. Since that time the swelling had continued to increase in size. Later the swelling was submitted to an exploratory incision, nothing but blood being obtained. At present there is considerable aching in the region of the tumor, and recently the patient had had numerous attacks of vertigo. His best weight had been 135 pounds (61.5 kg.); on admission he weighed 120 pounds (54.5 kg.).

Examination showed a healthy adult male. His scalp, eyes, ears and nose were normal. His neck presented in the left submaxillary region a mass which extended from below the ear half-way to the clavicle protruded above the level of the mandible, and extended backward to the posterior border of the sternomastoid. This mass was firm and elastic to the touch and in its upper part, toward the mandible, gave an indistinct sense of fluctuation. The skin was not adherent except at the site of the exploratory incision. There was no œdema, and only slight heat. The mass was movable slightly antero-posteriorly, and less freely up and down. The deep cervical lymph-nodes were palpable on both sides, and were larger on the right than the left side. No submental nodes were palpable, nor were the right submaxillary lymph-nodes. The temporal pulses were equal. There was no indication that the mass was an aneurism.

The thorax and abdomen were negative. The epitrochlear and inguinal lymph-nodes were palpable on both sides of the body.

In view of Doctor Nassau's opinion that the mass was malignant, a number of consultants were asked to examine the patient. Doctor Nicholas, making a dental examination, reported that all the remaining teeth were in rather good condition except for stains and accretions; he found no evidence of a possible focus of infection. Doctor Collins, making an examination of the throat, nose, and ears, reported them as negative for possible source of infection. Dr. H. C. Deaver, making a local examination, gave as his first diagnosis, *sarcoma*; as his second, *tuberculosis* of lymph-nodes. Dr. E. G. Alexander thought it was a growth of the lymph-nodes, of *sarcomatous nature*; but thought tuberculous infection must be considered.

Operation.—On October 14, 1922, operation was undertaken by Doctor Ashhurst with the diagnosis of tuberculous lymph-nodes; second choice of diagnosis, branchial carcinoma. The rapidity of growth (just over two months) indicated, he thought, an inflammatory rather than a malignant tumor; although the negative exploration, and the absence of any recognizable focus of infection, were rather in favor of a neoplasm. However, it was determined to conduct the operation as if the tumor were malignant. With the patient in the head high position, and the neck hyperextended over a sand bag, and under ether anæsthesia, an incision, 15 cm. long, was made along the anterior border of the left sternomastoid muscle, an island of adherent skin, including the cicatrix of exploration, being removed with the mass. The sterno-

RECURRENT KELOID OF BOTH EARS

mastoid muscle was cut across about 5 cm. above the clavicle, and the common carotid artery was temporarily occluded with Crile's clamp. The tumor was dissected upward from the internal jugular vein until the latter became so densely adherent that it was cut across and tied. The submaxillary salivary gland was removed separately from the tumor, to which it was not adherent, though inflamed. This gave better exposure beneath the floor of the mouth and pharynx where the tumor extended. A few discrete enlarged lymph-nodes around the edge of the tumor were also removed with it. The superior laryngeal, hypoglossal and vagus nerves were identified and preserved; the spinal accessory nerve was not recognized. The tumor was dissected up to the base of the skull, where, in freeing it from the upper end of the internal jugular vein, the tumor was accidentally opened, with the discharge of a little creamy yellow pus. The upper end of the internal jugular vein was ligated, the resected portion being removed with the tumor. The arterial clamp was then removed. Temporary occlusion of the common carotid certainly facilitated the dissection by rendering the field relatively bloodless. The platysma was closed with interrupted chromic catgut, and the skin with equisetene; a rubber tissue drain was left at the lower end of the incision. The man made an uneventful convalescence.

Pathological Reports (Dr. C. Y. White).—From the pus encountered during operation, a smear showed no organisms, and a culture gave no growth. A guinea-pig inoculated with the tissue failed to develop tuberculosis. Histological examination showed merely chronic inflammation of lymph-nodes without evidence of any specific change, tuberculous or other.

The patient was seen in May, 1923, seven months after operation. He carried his head with the chin turned a little toward the left. At present, one year after operation, he carries his head straight, and is in good general health. The cicatrix is linear and supple. Just posterior to the scar at its upper end there is one enlarged lymph-node, about $\frac{1}{2}$ to 1 cm. in diameter, and slightly tender.

DOCTOR NASSAU remarked that although Doctor Ashhurst in his history of this man had traced this case as far as Frankford Hospital, he did not go back far enough. He had an epithelioma of the lip excised at Jefferson Hospital three years before he came to Frankford Hospital, so that there was every reason to assume that the enlargement in the neck was evidence of a malignant growth, a case of recurrent carcinoma. They advised X-rays, preliminary to radical operation, but the patient refused to have this done, left the hospital and did not return. As Doctor Ashhurst notes, he has another enlarged gland in his neck, posterior to the recent dissection. It would seem as though the diagnosis of malignant growth of the neck was justified, even though the pathological examination did not find any area of malignancy.

[POSTSCRIPT.—Reëxamination of the patient showed a small scar on the right lower lip; this the patient had tried to conceal for fear if it were seen, no operation would be done. He acknowledged having been operated on by Doctor Neilson in March, 1920, in the Episcopal Hospital, at which time he gave an assumed name. The records show that

PHILADELPHIA ACADEMY OF SURGERY

a small growth, which had then been present for six or seven years without any change in its character, was excised. Doctor Neilson's diagnosis was papilloma. The specimen was not sent to the laboratory for microscopic examination. The patient states he was never treated in the Jefferson Hospital.

The patient has promised to return after Christmas for excision of the palpable but indolent node, still present in the left neck, and a further report will then be made to the Academy. A. P. C. A., December, 1923.]

RECURRENT KELOID OF BOTH EARS

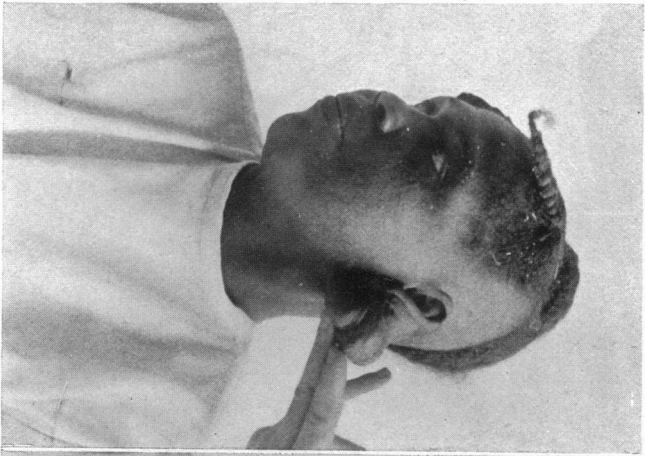DOCTOR ASHHURST presented a negress, forty years of age, who came under his care at the Episcopal Hospital in September, 1921. Keloids had developed in the lobule of each ear about twenty years previously, very soon after puncture for ear-rings. The keloids grew slowly, but became so large that she had submitted to an operation elsewhere in 1917. The keloids began to return almost at once, and were now larger than ever before. They formed firm pendulous masses (about 10 by 5 by 8 cm. in size) attached to the lower half of each auricle (Fig. 1) and apart from the conspicuous deformity, which she concealed by wearing a close-fitting cap covering the ears and tumors, they also incommoded her by their weight and size.

September 30, 1921, the keloid was excised from the *left* ear, leaving a defect about the size of the palm of the hand. The skin edges were undermined on all sides, thus exposing the platysma and fascia. A free transplant of fascia lata (about 8 by 5 cm. in size) was cut from the right thigh and inserted in the neck wound, being sutured with No. 00 chromic catgut to the platysma and fascia, well back from the skin edges. To close the skin a plastic operation was necessary. A flap was cut from the neck, with its base below and anteriorly, and the apex of the flap was inserted behind the auricle. In this flap were included the superficial fibres of the sterno-mastoid muscle. A small flap from the scalp had to be brought down to complete the closure above and behind the ear. The skin edges were closed with interrupted sutures of equisetene. The closure was smooth and without tension except at the lobule of the ear. This point subsequently became the seat of a slough, about 1.5 cm. in diameter. The rest of the wound healed properly.

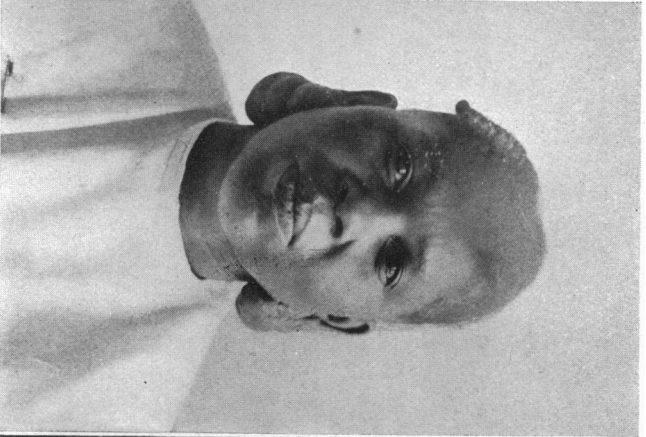November 1, 1921, the keloid of the *right* ear was excised in a similar manner, a free transplant of fascia lata (about 4 by 10 cm.) taken from the left thigh, being implanted, and a skin flap (about 5 by 10 cm.) being cut as already described from the neck, and turned up to cover the defect. Healing occurred without any slough, there being no tension on the suture line at any point.

Systematic exposures to the Röntgen-ray were given during the after-treatment by Dr. Ralph S. Bromer.

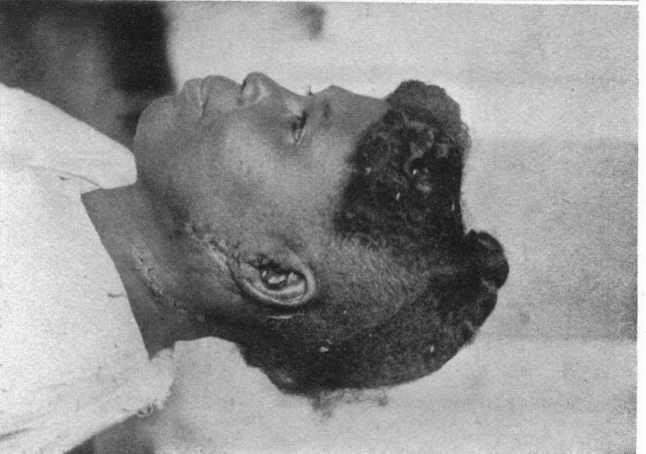Photographs made one year after operation (Fig. 2) show no recurrence of keloid at all except just below the left ear, where tension was present and a slough separated. The patient's present condition, two years since operation, shows no further recurrence, except on the scalp back of the left ear, where there is slight keloid. The ear itself



A



B



C

FIG. 1.—a and b. Keloid of both ears, recurrent after operation four years ago. c. Scar of operation on left ear, twelve days before photo.




Fig. 2.—One year after operation for keloid of both ears; no recurrence at the end of the second year.

CARCINOMA OF THE SIGMOID

is normal. Whether this freedom from recurrence is to be attributed to the implantation of the fascial transplants, thus relieving the skin cicatrices of tension, as advocated by Freeman (Colorado Medicine, 1915, vol. xii, p. 79) or to the Röntgen-ray treatment, is problematical. Certainly it is well recognized that simple excision of keloids, without any other precautions, is nearly always followed by prompt recurrence; and it is further notable that both the incisions made in this patient's thighs have developed keloids, that on the left giving her pain at times. The left thigh keloid measures 1.5 cm. by 17 cm., and that on the right 1 by .16 cm. These skin wounds were made in the long axis of the limb, that is at right angles to the normal skin creases, but were under no tension when sutured. Yet they were over defects in the fascia lata, which could not be closed completely after removal of the transplants, and they were not subjected to Röntgen therapy.

DR. RALPH S. BROMER said that X-ray treatment is indicated in every case, except where the keloid is so large that all hope of reduction in size is impossible, owing to the extreme growth of the tumor. In such cases post-operative treatment after removal by the surgeon is the best method. In this case, 9 or 10 doses of X-ray were given in which the scar was screened very closely in order to protect the remainder of the skin. The keloid tissue certainly did not increase in size. However, in another case a small keloid of the neck, seen about two weeks after starting this one, after three treatments there was no apparent effect on the growth. This case was then referred to the surgical service and the growth was excised, fascia lata transplantation being used. After six or seven post-operative treatments the keloid recurred. Doctor McKee, of New York, has had much experience in these cases and finds very little difference between the use of radium and the X-ray, but finds the beta rays of radium very efficacious in the treatment of small keloids. Pfahler and Knox agree that after post-operative removal, treatment by radiation is always indicated. In case of small keloids radiation should first be tried.

DOCTOR DORRANCE said that in a patient at St. Agnes' Hospital who had large keloids on the chest, a test was made by applying X-ray to 1/3; radium to 1/3, and nothing to 1/3. After X-ray treatment and radium treatment of, he did not remember what exact dosage; they excised it three months later and the pathological report showed no difference between any of the three parts. After they removed it they did the same thing over again with no particular change. They thought, however, that the side to which radium had been applied had less scar.

CARCINOMA OF THE SIGMOID WITH PERFORATION OF THE CÆCUM

DR. EDWARD J. KLOPP presented a specimen obtained from a man aged fifty years, who was admitted to Doctor Gibbon's service at the Jefferson Hospital, September 12, 1923. He complained of pain and distention of the abdomen and constipation. His father died at sixty-seven of cancer of the rectum.

In November, 1922, he had a cough which lasted about three weeks; no hæmoptysis, night sweats or pain in chest. All winter he felt weak and tired and began to lose weight. Had no nausea, vomiting, diarrhoea or increased constipation. About three months ago first noticed swelling of the abdomen which would appear and disappear. This has become worse until now it stays all the time. About six weeks ago pain gradually appeared and became fairly severe. He vomited only twice in last six weeks, rather copiously, a bitter, dark greenish material. Constipation began three months ago which later became very obstinate. At no time did he notice blood or mucus in the stools.

On examination the abdomen was found to be considerably distended, tympanitic, moderately tender over the right lower quadrant and no free fluid demonstrable. Transversely across the abdomen, immediately above the umbilicus and corresponding to the position of the transverse colon, was a mobile, fairly soft mass suggesting fecal accumulation.

Temperature, pulse and respiration were normal. He did not appear to be critically ill. Immediate surgical interference did not seem imperative.

At 4 P.M. of the following day he vomited, the abdominal pain was intense, the pulse could not be felt. There was no response to stimulation. He died at 8 P.M.

The autopsy made by DR. B. L. CRAWFORD revealed a general recent peritonitis due to a perforation of the anterior wall of the cæcum, in which part of the intestine was an area of necrosis.

The stomach and entire small intestine contained foul-smelling fecal material. The wall of the entire cæcum was dark green in color, the opening in the wall sharply defined, without any evidence of inflammation of the mucosa. No induration of the gut wall. The remaining portion of the large intestine was markedly distended with semisolid fecal material, down to the sigmoid, 30 cm. from the anus, where there was a definite constriction in the lumen of the gut; only with force could small quantities of fecal material be forced through. On sectioning the sigmoid, the constricted portion measured 2.75 cm. in circumference, a narrow portion of the gut wall is thickened and indurated.

The histologic diagnosis was adeno-carcinoma of sigmoid with metastasis to the regional and retro-peritoneal lymph-nodes. Acute fibrino-purulent peritonitis.

He presented this specimen not because cancer of the sigmoid is unusual nor that obstruction is infrequent, but because necrosis of the cæcum so far removed from the site of the obstructive lesion is uncommon. The necrosis probably was due to marked distention and weight of the heavy column of colon contents. One occasionally sees ulceration and perforation at site of malignant growth or near by on the proximal side when obstruction is almost complete and when the fecal matter is fairly hard, thus causing ulceration and possibly perforation.

Perforation apparently was not very sudden, evidenced by the closure of the opening by a coil of intestine and the absence of fecal material in the peritoneal cavity.

HYDRONEPHROSIS FROM KINKING OF URETER

DR. A. P. C. ASHHURST said that some years ago he had a patient who had an abscess around the cæcum, and came to the hospital very sick. The abscess was opened and drained, but the patient never got well and a fecal fistula developed. At autopsy a carcinoma was found at the hepatic flexure, entirely independent of the perforation of the cæcum, but which had caused the perforation, by back pressure from chronic intestinal obstruction. The carcinoma, however, was nearer the seat of perforation than it was in Doctor Klopp's case.

HYDRONEPHROSIS FROM KINKING OF URETER

DR. T. TURNER THOMAS reported the history of a man, forty-three years old, who three or four years ago, had a severe attack of abdominal pain in the right side of the abdomen and loin, and remained in bed three weeks. Last year he had another similar attack which kept him in bed five weeks. The pain bore no relation to meals. He never had any dysuria, incontinence, hæmaturia, or any trouble with urination. April 7, 1923, his last attack began when he became nauseated and vomited a few times. He has had no other gastric symptoms, no pain after meals, no gaseous or acid eructations, and his appetite has been good. He has had no dizziness in these attacks, no palpitation, œdema or other heart symptoms. He has not been jaundiced at any time. He was admitted to the Northeastern Hospital on April 7, 1923, the day on which this last attack began. April 9 the abdomen was opened by a right rectus incision. On introducing the hand into the abdomen for examination, an abnormal globular mass was discovered which appeared to be connected with the kidney. The abdominal incision was then closed and protected and the patient turned over into the prone position and the kidney exposed through the loin. It was delivered into the wound and the fluctuating mass explored by a needle and found to contain a fluid which was probably urine. It was then opened and found to be a dilated kidney pelvis.

The ureter immediately below the dilated pelvis was of about the normal calibre, indicating that there was an obstruction at the junction of the dilated and normal portions. It was concluded that there must be a kink here. No stone could be found in the pelvis and an ordinary (long) probe was passed down the ureter about 6 or 8 inches to where it crossed the iliac vessels and bent sharply downward into the pelvis without meeting any obstruction. In an effort to overcome the kink the ureter was divided longitudinally and an attempt made to suture this wound transversely. This was very difficult and resulted in the complete detachment of the ureter from the pelvis. The upper torn opening in the ureter was then anastomosed into the larger opening in the dilated pelvis by catgut suture, the effort being to overcome any further obstruction by uniting the small opening of the ureter all around to a larger opening in the pelvis, thus tending to hold the ureter wide open. This was accomplished fairly satisfactorily, the kidney was replaced in the abdomen, a split rubber tube with a gauze drain in it was introduced to the repaired pelvis and ureter and brought out of the lower angle of the wound, which was then closed in the usual manner. The patient was returned to the ward in a fair condition.

PHILADELPHIA ACADEMY OF SURGERY

April 10. The pulse which was about 60 before operation has gone up to 136, the temperature to 100.6. The abdomen is tense and tympanic and the patient breathes with difficulty. He is vomiting small quantities of a dark liquid, usually turning his head to one side to spit it out. He has not passed flatus, although peristalsis can be heard.

April 11. Same condition as yesterday, somewhat worse.

April 12. After an effectual enema to-day the abdomen became softer and the patient felt better.

April 14. The improvement has continued and to-day the patient is allowed soft diet. The dressings over the loin wound are dark from wound discharges, but have become dry, indicating that he has probably not been discharging urine from the wound. On the day following the operation the urine was dark colored, evidently from blood, indicating that he was already passing urine freely through the anastomosed ureter and kidney pelvis.

The patient continued to improve and was discharged April 25. At no time after the operation did he show any evidence of obstruction to the urine. He went back to work about four weeks later and has continued to do so since, according to his statement when last seen, about the middle of August, and by the statement since then by his physician, Dr. W. Drummond.

CHORIO-EPITHELIOMA OF THE UTERUS

DOCTOR THOMAS detailed the history of a woman, twenty-seven years of age, who was admitted to the Northeastern Hospital, July 29, 1923, on account of a metrorrhagia which had persisted for about ten weeks. Three years before she had experienced a similar trouble, which was relieved by a curettement. In the interval she had been perfectly well.

July 31. The cervix was widely dilated and the finger introduced, but could not reach the fundus nor feel anything pathological. The dull curette detected on the posterior surface of the uterine cavity near the fundus on the left side, a small, rough, gritty surface, the scraping of which produced a peculiar tissue, which was rather tough and fibrous and had a somewhat cauliflower appearance. To stop the free bleeding the uterus was irrigated with a hot solution and packed with sterile gauze, which was removed on the following day.

August 3. The pathologist, Dr. William Spaeth, reported that the specimen showed a chorioepithelioma.

August 4. A supravaginal hysterectomy with a bilateral salpingo-oöphorectomy was performed. The specimen consists of the uterus, both tubes and ovaries. The uterus is about twice the normal size and is soft and boggy. Both tubes and ovaries show no abnormalities. Opening the uterus anteriorly there is found a reddish-blue mass situated on the posterior wall of the fundus, soft and friable and intimately attached to the uterine endometrium. It is about 3 cm. in diameter and spherical in outline. A section taken for diagnosis, upon microscopical examination, showed a cellular extension taking place in the blood sinuses and irregular masses of nucleated protoplasm formed by syn-

RAPID REGENERATION FOLLOWING FACIAL NERVE SUTURES

cial cells. Many smaller cells resembling endothelial cells and some similar to lymphocytes are also present. In addition there is found some myxomatous degeneration. Diagnosis: Chorioepithelioma of the uterus.

The patient was discharged August 16 and has remained well since.

DR. A. P. C. ASHHURST said that in 1919, he reported to the Academy the case of a woman who was then well and healthy six years after a hysterectomy for chorioepithelioma. He had written her again and the letter was returned, marked removed, which did not seem to imply that she was dead. If she still lives it is now ten years since her operation. (NOTE.—Since this discussion, the patient has been traced by the Social Service Department of the Episcopal Hospital, and is in perfect health still.)

He thought it to be very important for anyone who has to evacuate the uterus after a miscarriage to have the tissue examined in the laboratory. In this case there was nothing grossly abnormal in the tissue, but the report from the laboratory came back in nine days and the next day the hysterectomy was done. Though this laboratory examination has been made as a routine since then in all cases, they have not found another case of chorioepithelioma, though such a diagnosis has been made twice erroneously from the gross specimen.

RAPID REGENERATION FOLLOWING FACIAL NERVE SUTURES

DR. E. L. ELIASON presented a woman who in the evening of April 11, 1923, sustained in an auto accident a jagged incised wound in front of the right ear extending from just above the tragus down to the angle of the mandible. This incision severed the facial nerve, the parotid gland and the masseter muscle. There was complete paralysis in the right facial nerve distribution. Other injuries to face, lip and teeth were present.

The wound was cleaned and the nerve which was severed just before it broke up into its division was sutured with 000 silk. The parotid was sutured and a small rubber wick placed in the lower angle of the wound.

April 17. She was discharged, wound having healed per primam. Facial paralysis still present.

April 30, 1923. A dentist who is at work on her teeth reports return of power to retract the angle of the mouth.

Neurological Report by Dr. George Wilson.—The first electrical reactions were made seventeen days after the injury and showed no reaction to faradism and reactions of degeneration to galvanism. Twenty-three days (May 4) after the accident there was a slight return of motion at the angle of the mouth and a strong faradic current produced slight reaction. She was treated with electricity, galvanism at first and later faradism two or three times a week until the first of September.

The return of power in the lower part of the face was quite rapid, but very little if any recovery has taken place in the upper branch of the seventh nerve. About the first of August she first began to show some movements in the lower part of the face when the eye was winked and

PHILADELPHIA ACADEMY OF SURGERY

also movements of the eye when the lower part of the face was moved. This is probably due to the fact that some of the fibres in growing distally lose their way, those which should go to the upper part of the face going to the lower and those which should go to the lower part of the face going to the upper.

DR. CHARLES H. FRAZIER said that he was particularly interested in whether it was physically possible for nerve restoration to take place with return of function in twenty-four days. Estimating on the basis that nerve regeneration occurs at the rate of $1\frac{1}{2}$ cm. per week, it is quite possible for new axes to have grown down in this case from the point of injury to the end muscle within the specified time. A point which had occurred to him was whether or not it was possible to revise the laws of physical repair in cases of nerve injury because it is generally understood that after complete dissolution before regeneration takes place, degeneration takes place in the duct. If that were true it would hardly be conceivable that function could be restored within the specified time. He had no recollection of any other case which recovered as rapidly as this.

Concerning the return of function in the occipital frontalis, for some reason or other this frequently occurs.

DOCTOR ELIASON added that he had no especial difficulty except in finding the proximal end of the nerve. He put three fine silk sutures in it and obtained good approximation. There is no doubt about the fact that the nerve was cut, and that the return of function is authentic. Doctor Frazier had said he had never heard of a case being as rapid. Doctor Spiller, also, thought it very unusual, but said he had never heard of the facial nerve being sutured within one hour of the injury to it, and thought this might have something to do with the rapid regeneration.