

TRANSACTIONS OF THE PHILADELPHIA ACADEMY OF SURGERY

STATED MEETING HELD APRIL 2, 1928

The President, DR. ASTLEY P. C. ASHHURST, in the Chair

CALVIN M. SMYTH, JR., M.D., Recorder

FRACTURE OF HUMERUS COMPLICATED BY INJURY TO MUSCULO- SPIRAL NERVE

DR. JAMES A. KELLY presented a man aged nineteen, who was admitted to St. Joseph's Hospital, November 30, 1926, suffering from a fracture of the left humerus about the junction of the lower and middle thirds; laceration of the left axilla, extending from the anterior axillary fold through the axilla to the posterior axillary fold, exposing contents of the axilla and particularly the axillary artery and vein. The two latter were completely separated from their surrounding fatty coverings. There was no injury to either vessel. In addition there were several lacerations about the head and face. Under anæsthesia the lacerations of the head and face were thoroughly cleansed and sutured. The axillary wound was sutured. The fracture of the left humerus was reduced and dressed. The patient made an uneventful convalescence from his wounds.

January 3, 1927, he was readmitted on account of musculo-spiral paralysis. Examination on readmission showed the left upper extremity held with the forearm flexed at right angles to the arm. The wrist flexed so that the hand hung at a right angle to the forearm. He was unable to extend the wrist or to supinate the hand. Pressure over the site of the fracture of the humerus caused burning sensation on the dorsum of the thumb and the radial side of the hand. Biceps, triceps and extensor tendons—at wrist—reflexes were absent. There was an area of anæsthesia over the lateral and posterior aspects of the arm. This area extended from the shoulder cap almost to the elbow. No areas of anæsthesia were found in the forearm; over the lateral aspect of the index finger there was an area of anæsthesia which extended about one inch proximal to the metacarpo-phalangeal articulation. He was unable to extend the hand or fingers, and there was very little movement at the elbow.

Neurological examination, January 7, 1927, revealed a typical wrist drop which, with the other findings present, indicated that there had been damage to the median, musculo-spiral and the ulnar nerves.

At operation, January 12, 1927, exposure of the two ends of the lacerated musculo-spiral nerve showed a separation of about one and one-half inches. These ends were bulbous in character. There was solid union at the site of fracture. The two ends of the musculo-spiral nerve were drawn together, the bulbous portion of the ends excised, and the ends of the nerve held together without tension by means of four fine silk mattress sutures. A square flap of fat and fascia was then dissected on three sides from the superficial fat and fascia, and placed about the line of sutures on the nerve, acting as a cuff. The wound was closed without drainage. Primary healing took place and the patient was discharged, January 25, 1927. At present the patient is able to play base-ball, basket-ball and other sports.

An examination made March 12, 1928, showed complete function in this

FRACTURE OF HUMERUS

limb with one slight exception, and that is failure to fully extend the thumb. The extensor muscles are not yet as strong as those on the opposite side but they have considerable power. There is no appreciable atrophy of any muscles

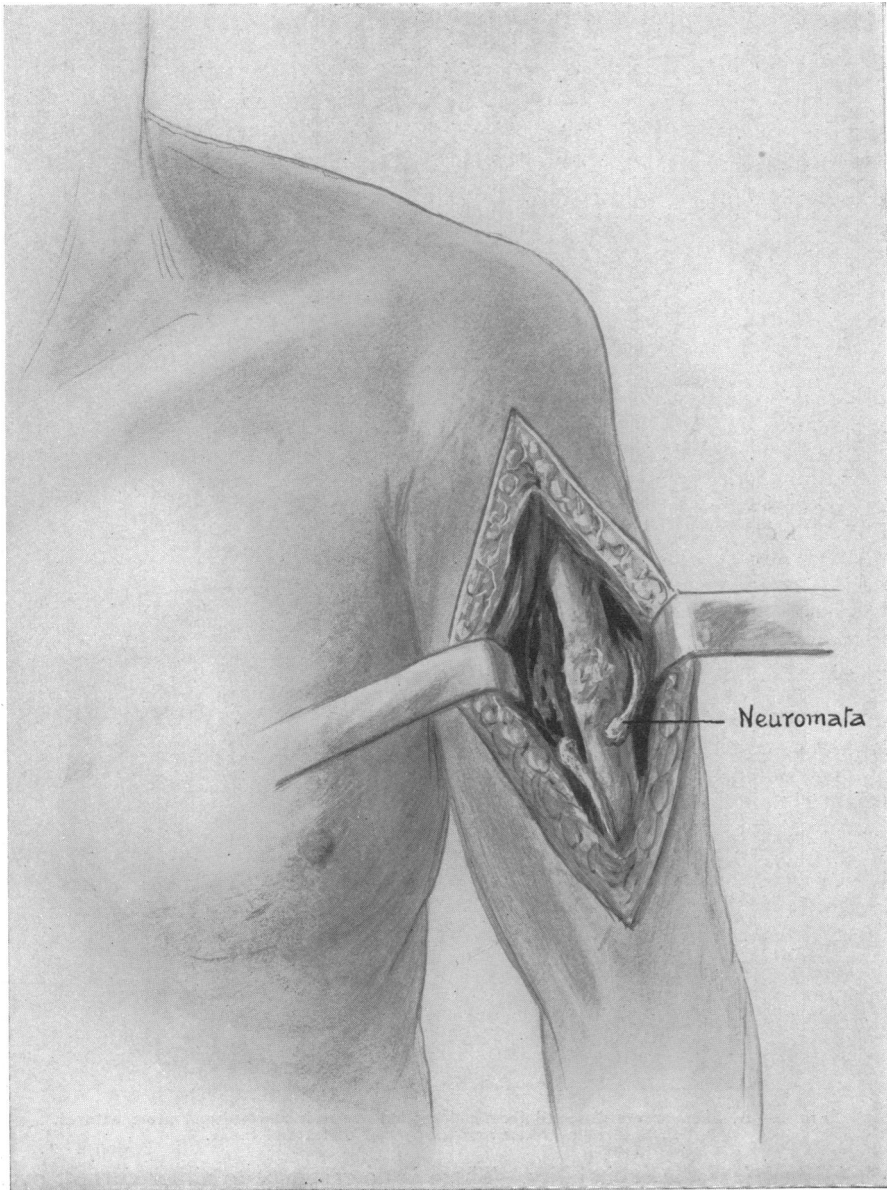


FIG. 1.—Condition found at time of operation six weeks after injury, and cut ends of musculo-spiral nerve separated about $1\frac{1}{2}$ inches, with bulbous ends.

supplied by the musculo-spiral nerve. The left deltoid muscle is completely atrophied but the suraspinatus has taken over its function, so that the patient is able to extend the limb at right angles to the trunk and about the head. The

biceps and triceps reflexes are normal. The electrical reactions are as follows: To galvanism in the musculo-spiral distribution the CCC. is greater than the ACC., and the size of the contraction is almost normal. There is still

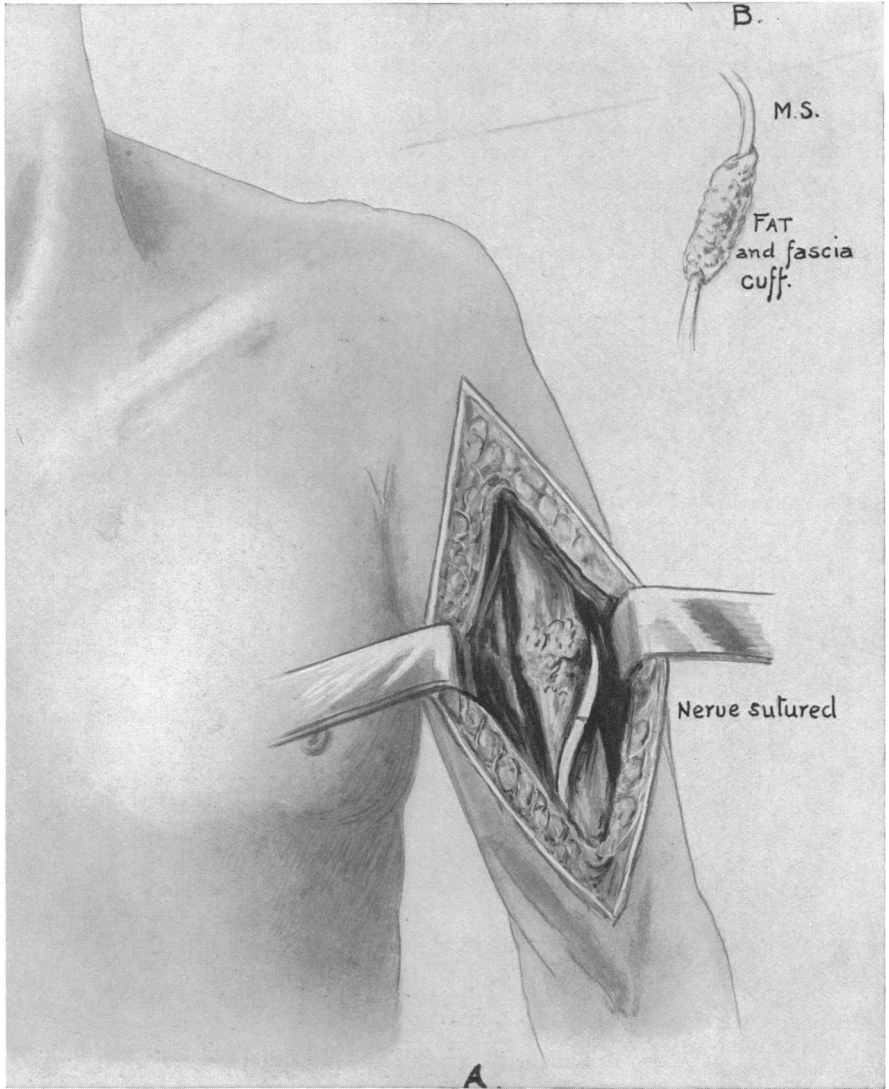


FIG. 2.—A. Shows nerve dissected from callous; bulbous ends resected and nerve sutured.
B. Sutured nerve surrounded by cuff of fat and fascia.

diminished farradic excitability. There is no response to either current over the deltoid.

There is an area of anæsthesia for light touch and pin-prick over the lower two-thirds of the deltoid and the upper two-thirds of the triceps. Deep pressure over the musculo-spiral distribution anywhere causes pain. The area of anæsthesia over the deltoid corresponds very well to the distribution of the circumflex nerve. The area over the triceps, however, covers the distribution for

CARCINOMA OF THE JEJUNUM

several nerves, namely: Part of the area supplied by the external cutaneous and most of that supplied by the internal cutaneous and perhaps that part supplied by the intercosto-humeral.

The patient thinks that he began to have return of function eight or nine months after the nerve was sutured. Doctor McIver who made the examination stated that he had never seen a case of deltoid-paralysis in which the supraspinatus took on its function.

CARCINOMA OF THE JEJUNUM

DR. J. JAMES CANCELMO, by invitation, reported the case of a woman, aged sixty-three, who was admitted to St. Mary's Hospital in the service of Dr. James A. Kelly, June 21, 1927, complaining of "indigestion" of eight years

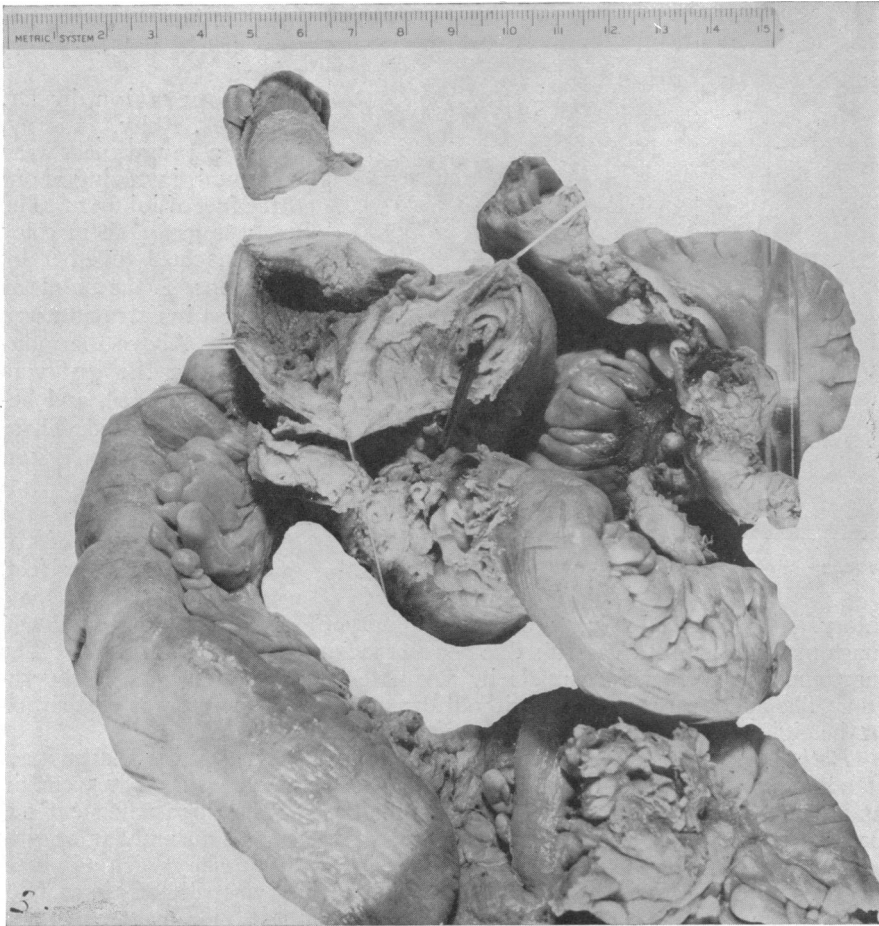


FIG. 3.—The glass rod about 3 mm. in diameter extends into the annular constriction due to carcinoma. To the left the enormously distended bowel may be seen. The portion of gut lying immediately above is the tissue from which the sections (4 and 5) are taken.

duration; for the past four years her symptoms have been getting worse. Eight months ago she noticed some enlargement of the abdomen which had slowly been increasing. Her appetite was poor and about one hour after each meal she had cramp-like pains in the middle of the abdomen. She had always

been costive and took purgatives daily. Vomiting occurred almost daily. The past history is negative except for childhood diseases. Examination revealed a distended abdomen with visible peristaltic waves in the lower part of the upper right quadrant. No tenderness; no masses palpable. The usual examinations of the blood and urine were negative; the blood chemistry and tests of kidney function were within normal limits.

Fluoroscopic examination of the gastro-intestinal tract showed that the duodenal cap filled after considerable difficulty, and exhibited a flattening not only of the cap but of the entire pyloric end of the stomach. The head of the six-hour meal remained in the small intestine which was tremendously dilated, and showed very active peristalsis. Evidence of obstruction was present in the

small intestine at a considerable distance from the pylorus, but the exact nature could not be determined.

At operation, by Dr. James A. Kelly, June 27, 1927, a large mass was exposed, involving about three feet of jejunum. The gut was grayish in color and was held together by adhesions. In the middle of the mass infiltration was marked. Above the indurated area the gut was greatly distended, and below it was collapsed. There were very few enlarged nodes, except in the immediate vicinity of the growth. A section of the gut, measuring four feet, was removed with its mes-

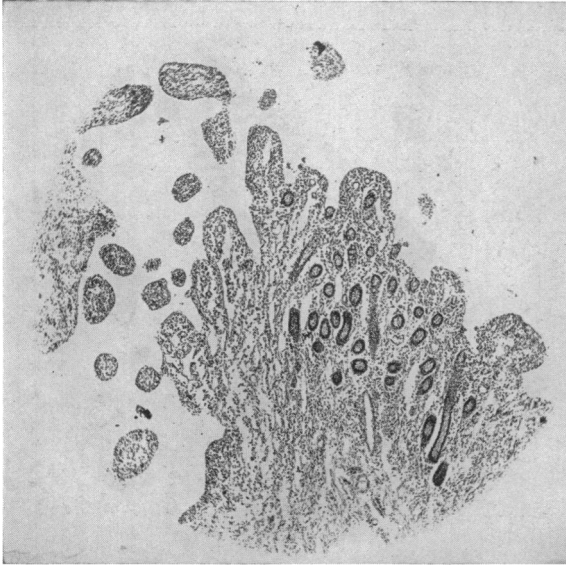


FIG. 4.—Sixteen mm. objective. Normal jejunum. Cross and tangent section of villi and crypts of Lieberkuhn.

entery. An attempt to restore the continuity of the bowel by end-to-end anastomosis was unsuccessful, due to encroachment upon the lumen. The anastomosis was therefore made by a simple lateral short circuiting operation. The abdomen was closed without drainage. The patient was discharged on the eighteenth day after operation, very much improved.

Pathological Report.—*Macroscopic:* The operative removal is a large mass of adherent loops of jejunum which when separated measure 117.5 cm. in length. A small firm tumor was present in the centre which when cut out measured 3.7 cm. x 2.5 cm. x 1.2 cm. and was found to be an annular or ring neoplasm, encircling the intestine and constricting the lumen which admitted a 5 mm. quill. The intestine on the proximal side was dilated times two. There were several small polypoid growths of brittle tumor mass extending into the dilated intestine of the proximal side. The neoplasm had invaded all the coats of the intestine but none of the other loops were involved. (Fig. 3.)

Microscopic: Study of the neoplasm reveals a primary adeno-carcinoma in the mucosa of the jejunum which invades the muscular and serous coats. The tendency to form acini with central lumen is lost as the tumor cells penetrate the mucosa and they diffusely infiltrate the muscle in the form of small alveoli consisting of compact masses of cell groups. (Figs. 4 and 5.)

CARCINOMA OF THE JEJUNUM

Pathological Diagnosis: Primary adeno-carcinoma of the jejunum.

The reporter added that Probst¹ states that in 41,858 necropsies performed at the Vienna General Hospital, 3,585 were carcinoma, of these 342 were in the intestinal tract and only nine of these were in the jejunum. In the past twenty years, 4,684 cases of gastro-intestinal carcinoma have been operated on at the Mayo Clinic, and thirty-six cases or less than 1 per cent. were in the small intestines.² Unless the carcinoma is obstructive the physical findings show very little that enables one to make a diagnosis. The mass is very often not palpated because of the fluidity of the intestinal contents. Auscultation should help more but there is little evidence that his procedure is much used. Unless the lesion is ulcerative blood is not found in the stools so that this test does not help much. Even the X-ray seldom points out the lesion to be carcinoma.

BRICKNER and MILCH² report a case of carcinoma of the ileum in which the symptoms were those of sciatica. Nuzum³ has observed two instances in which the patient's conditions were diagnosed as pellagra and at autopsy, carcinoma of the terminal portion of the ileum was found. Rankin⁴ reports four cases of acute intestinal obstruction due to malignancy, while Morrison¹ reports a case of high intestinal obstruction due to carcinoma.

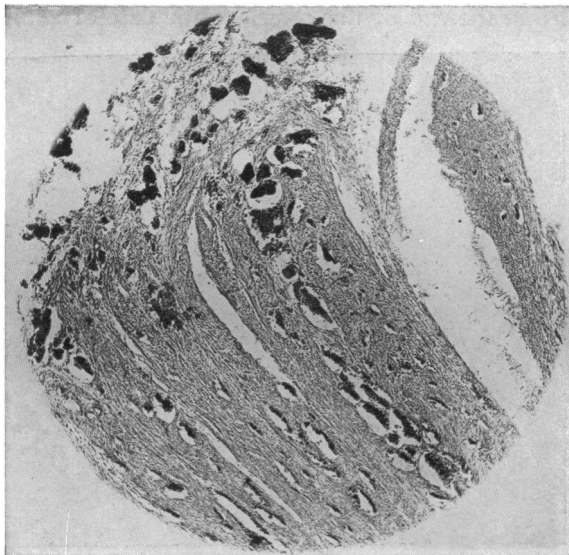


FIG. 5.—Sixteen mm. objective. Primary adeno-carcinoma of jejunum. The tendency to form acini is lost as the tumor cells penetrate the mucosa and they diffusely infiltrate the muscle in the form of alveoli.

Prognosis: The cases of intestinal carcinoma which have the best outlook are those which are operated upon earliest. Those with obstructive lesions will be seen earlier than others. One is impressed with the fact that the lower the lesion the better the prognosis. In the reporter's case, the lesion was an annular carcinoma. Its removal was not only feasible, but indicated. At the present writing three months after operation, the patient has gained thirty pounds in weight, has regained her strength and has no complaints.

DR. DONALD GEIST reported from the service of Dr. James A. Kelly, at

¹ Probst, J. G.: Subacute Ileocolic Intussusception Secondary to Carcinoma of the Ileum. *Surgery, Gynecology and Obstetrics*, vol. xlii, pp. 769-771, June, 1926. Quoted by Morrison. High Intestinal Obstruction Caused by Primary Carcinoma of the Proximal Jejunum. *The American Journal of Surgery*, vol. ii, pp. 154-159, February, 1927.

² Brickner, Walter M., and Milch, Henry: Carcinoma of the Terminal Ileum Causing "Sciatica". *International Clinics*, vol. iv, pp. 238-239, December, 1926.

³ Nuzum, Franklin R.: Pellagra Associated with Annular Carcinoma of the Terminal Portion of the Ileum. *Jour. A. M. A.*, vol. lxxv, pp. 1861-1863, December 12, 1925.

⁴ Rankin, Fred W.: Acute Intestinal Obstruction Due to Malignancy, vol. xlii, pp. 638-643. *Surgery, Gynecology and Obstetrics*, May, 1926.

the Misericordia Hospital, the case of a white woman, age forty-three, who was admitted to hospital, October 9, 1927. Her chief complaint was bloody stools. She stated that two years prior to admission she began to have aching abdominal pain about the umbilicus, radiating from right to left abdomen. Occasionally she noticed small amounts of bright red blood mixed in with the feces. Pain gradually grew worse and in January, 1927, became very severe and was associated with marked diarrhoea and loose, watery stools containing large amounts of bright red blood. This attack lasted for about two months and then subsided, the pain ceasing first and then the blood, the stools very quickly becoming formed. She remained well until the latter part of June and early July when she had a second attack, exactly similar and lasting five weeks. From the end of this attack to the date of admission she remained well and

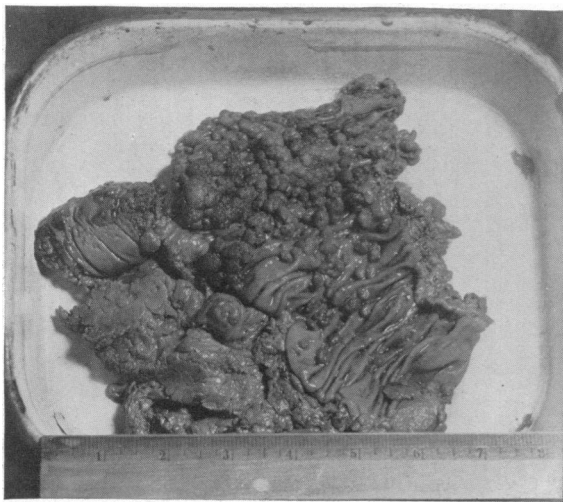


FIG. 6.—Polyposis of colon; gross appearance. A portion of the section removed.

free of symptoms. Appetite good and no loss of weight noticed. Only other symptoms were occasional swelling of the feet and ankles, and occasional frequency of urination. Past medical and social history were negative. Family history showed the presence of malignancy in one sister, one brother and father and grandfather but was otherwise negative.

When admitted no definite mass was palpable although there was a suggestion of a soft mass just above and to the right of the umbilicus, suggesting a mass in the transverse colon. Rectal examination

was negative. Blood Wassermann was negative in both the acetone insoluble antigen and the cholesterin antigen. Feces were positive for occult blood.

X-Ray examination of the colon showed an "irregular filling defect in the first part of the transverse colon. This was suggestive of multiple polyposis, possibly associated with ulceration."

Operative Findings.—The patient was operated upon by Doctor Kelly, October 15, 1927. Upper right rectus incision. Most of the transverse colon lay below the umbilicus. Its appearance was normal. Palpation revealed numerous, small, soft, pulpy, grape-like masses, apparently springing from the mucosa and slipping from the grasp quickly and easily. The outer coats of the bowel were smooth, pliable and showed no evidence of induration or fixation. There were no adhesions and no masses felt in the mesentery or omentum. The growths began about 100 cm. from the splenic flexure and extended for about 25 cm. to the left. About 25 cm. of the transverse colon were excised with the cautery. An end-to-end anastomosis was done. There resulted good approximation with an opening of over two fingers' breadth diameter. The abdomen was closed without drainage. Diagnosis at operation was diffuse polyposis of the transverse colon.

Progress of Case.—Except for occasional vomiting of small amounts of bile-stained fluid and hiccoughs which stopped on the second day after gastric

CARCINOMA OF THE JEJUNUM

lavage, convalescence was uneventful until October 26, when she developed slight tenderness in the right calf and inner thigh, a definite but mild phlebitis. This subsided and on November 4, 1927, she again was well. The first bowel movement occurred on the fourth day after operation and recurred daily for five days. They showed no gross blood. Three examinations of the feces were negative for occult blood. Barium enema the day before her discharge resulted in the report, "Injection of the colon shows an extremely short, ascending colon, measuring 10 cm. There is a very marked incompetency of the ileocæcal valve. At the site of the operation there is a very slight constriction. The remainder of the colon fills normally." The patient was discharged in good condition on November 13, 1927.

The pathological report recorded that the portion of the colon removed was covered with upwards of 300 pedunculated tumors ranging in diameter from three to four millimetres to about one centimetre, round, of a dark red color, a few of the largest showing bleeding points corresponding to superficial ulceration (Fig. 6.). Some of the smaller tumors have no pedicle. The tumors are soft, the base does not appear to infiltrate the mucosa and no evidence of tumor is seen anywhere else in the deeper structures of the colon. Lymph-nodes of the mesentery are not enlarged. Microscopically (Figs. 7 and 8), the polyps are formed of a well developed vascular pedicle, supporting a papilliferous growth formed of connective tissue frame-work with well-formed lymph-nodes. They are covered with cylindrical epithelium often showing mucoid degeneration. Mucus glands are well developed and the epithelium occurs everywhere in a single layer, the cellular elements being normal."

The reporter added that the presence of polypi in the gastro-intestinal tract has frequently been reported.

Statistics as to incidence are varied and scattered and difficulty is experienced in arriving at the true frequency of the lesion.

Two theories as to the origin of polyposis have gained prominence although many factors have been projected as causes. The first of these is that the lesion is congenital in origin. The second theory is that the lesion is an acquired one and the result of chronic irritation and inflammation. Among the many forms of irritation mentioned are chronic gastritis, atrophic gastritis, constipation, dietetic errors, irritation by foreign bodies or parasites such as the ascaris, alcoholism, faulty and incomplete mastication and atheroma of blood-vessels. There may be a certain hereditary influence in cases of gastro-intestinal polyposis, as the lesion has been found in brothers and sisters, twins and in mother and son. Certain observers state, "It is very probable that there are two types of epithelial overgrowth, an hyperplasia secondary to inflammation and an hypertrophy congenital in origin."

A variety of pathological entities have been included in the term polyposis. Polypi are fairly commonly seen in the rectum and there are numerous cases of multiple polypi scattered through the gastro-intestinal system. Myomata, fibromata, adenomata and carcinomatous growths, which assume a polypoid form, are included. Menetrier's pathological classification is still accepted. He divides polyposis into two groups: the first, polyadenoma polypeaux, in which a great many separate and discrete, usually pedunculated or lobulated

nodules involve the mucosa ; the second group he calls polyadenoma en nappe, in which, there is a raised, plaque-like, non-lobulated, non-pedunculated layer of hypertrophied mucous membrane. The individual polypi appears as soft, warty growths, varying in size from that of a pea to that of a nut or even larger. The color varies from a gray to a red or reddish-brown and the polypi often exude a considerable amount of mucus. They are lobulated or pedunculated and scattered diffusely but closely together along the mucosa. The number varies from a few to several hundred or more. Often they show

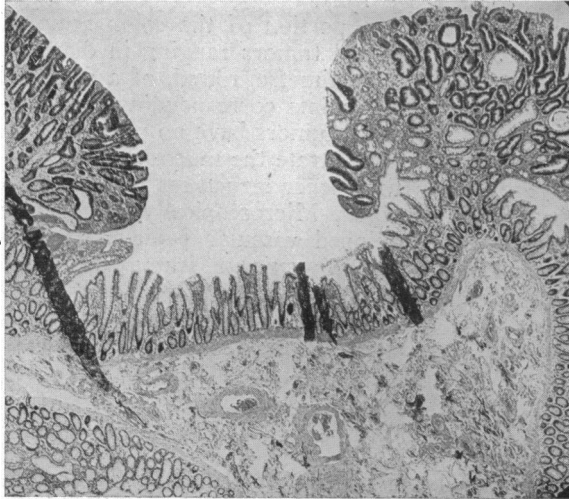


FIG. 7.—Section of polyps of the colon (microscopical).

small hæmorrhages or ulcerations. Frequent inflammatory changes occur. Microscopic examination shows the normal epithelium of that portion of the gut in which they occur and a supporting stalk of connective tissue. The submucosa is well developed and normal and often the muscularis mucosa is well seen. Malignant degeneration frequently occurs and shows itself by the same changes as in other neoplastic growths, namely: undifferentiation

of the epithelium, pleomorphism, mitosis and the extension of the epithelium past its normal boundaries. The actual frequency of such changes varies from 12 per cent. or 17 per cent. to 60 per cent. according to different authors. The other common secondary change is inflammation, the result of frequent irritation and trauma.

Polyposis offers no definite symptom complex. The disease may produce the most variable of symptoms or be marked in its involvement and yet devoid of signs. When the stomach is involved the symptoms are often those of any gastric disorder, be it ulcer, carcinoma or gastritis. They are, however, usually of long duration and with little or no constitutional effects. Abdominal pain and distress are frequent. The pain has no reference to meals, time of day, or type of food and may be mild or severe. However, frequent eating of small amounts of food often gives relief. It occurs no matter whether the lesion be in the stomach, small or large intestine. Vomiting, anorexia, constipation and weakness are noted. Hæmatemesis occurs and there is often occult blood in the stools but the acute hæmorrhage is rarely fatal. The picture may be that of a long-standing anemia with its blood findings, a little shortness of breath, pitting œdema of the extremities and weakness. A fairly constant finding, and one reported by many, is the presence of a marked diminution in or absence of

HELIOOTHERAPY IN EXTRA-PULMONARY TUBERCULOSIS

acid in the gastric contents. Due to the latter, diarrhœa may develop. When the growth involves the colon there is marked diarrhœa, tenesmus, hæmorrhage from the bowel and often pus and mucus in the stools. Yet with it all, loss of weight is slight and the general appearance of the patient is that of good health. The blood picture is negative or shows a moderate secondary anemia. Physical examination is usually negative although in some cases a mass may be felt. The latter is soft, freely movable and slips from the grasp easily so that a second effort at palpation makes one believe that there is none. Occasionally the symptoms become those of obstruction or intussusception and the latter is frequent in its occurrence.

The X-ray findings are significant and the diagnosis often made by this means alone. According to the late Doctor Carman, "The röntgenograms show a diffuse mottled appearance of the pars pylorica and the lower pars media without six-hour retention or a correspondingly palpable mass. This mottling is due to the displacement of the barium by the

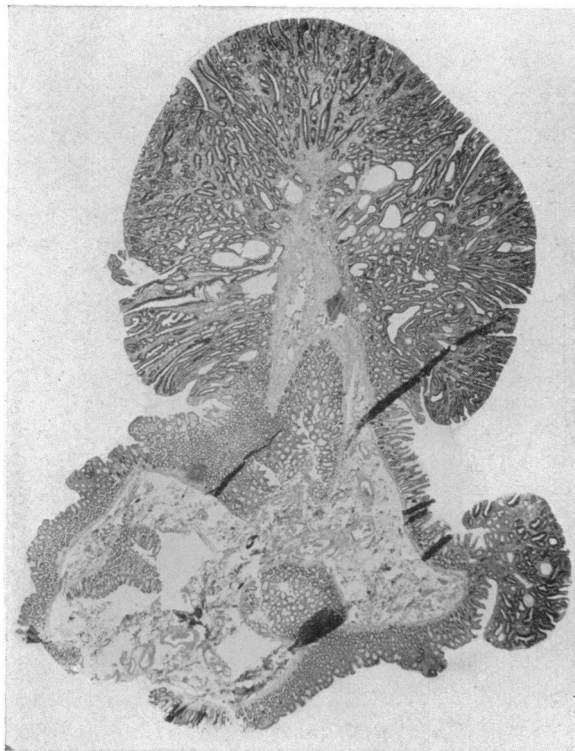

FIG. 8.—Section of polyps of the colon (microscopical).

approximation of the polyps which, offering no resistance to X-ray, produce numerous small, black shadows in the silhouette of the stomach." The same mottled appearance occurs in other parts of the intestinal tract, giving an appearance much like a bunch of grapes.

The treatment of diffuse polyposis is essentially surgical. If the growth is small and fairly well circumscribed, it may be removed by excision. When large and at all spreading, it requires resection. Occasionally such procedures as gastro-enterostomy have been attempted but have failed. The lesion almost always requires complete extirpation.

HELIOOTHERAPY IN EXTRA-PULMONARY TUBERCULOSIS

DR. RICHARD T. ELIASON, by invitation, said that his remarks were based on the work of the past three years in the heliotherapy demonstration at Chestnut Hill. This demonstration was organized to show what results could be

obtained with the use of heliotherapy in the extra-pulmonary forms of tuberculosis in children at this altitude and close to a big city. At the end of this period it is felt that the results have been most gratifying—so much so that the demonstration has been continued.

Of course the ideal location for the use of heliotherapy is one having both altitude and an atmosphere free from the smoke and dust raised by a large

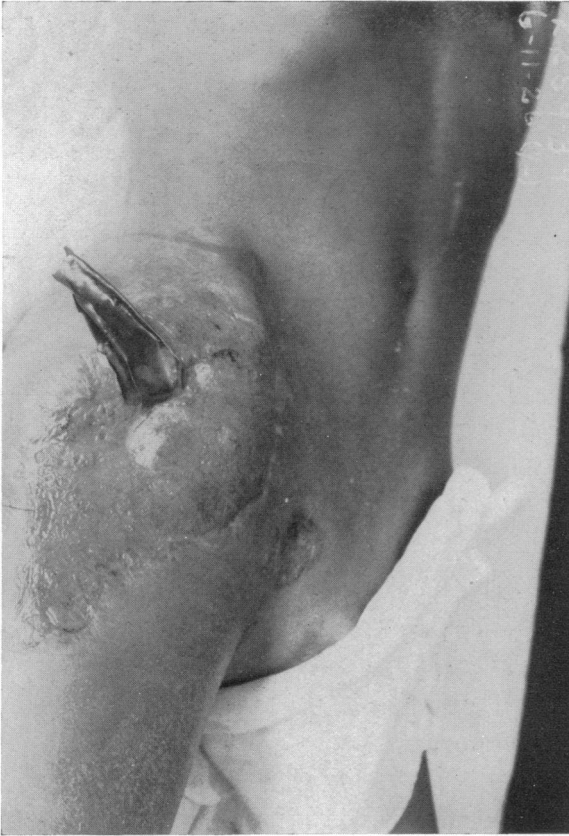

FIG. 9.—Result of heliotherapy in extra-pulmonary tuberculosis.

city. It is under such circumstances that the ultra-violet portion of the sun's spectrum is strongest, but the amount that penetrates to the ground in the outskirts of any large city is sufficient to be of great therapeutic value. It is well known that it is the ultra-violet band of sunlight that has the greatest therapeutic value but there is a growing feeling that the visible and infra-red regions also are of value and tend to augment the effects of the ultraviolet. Heliotherapy is really much more than just the use of the ultraviolet radiation derived from the sun and should include fresh air baths, rest, diet and a strict adherence to all well established conservative orthopaedic practices. Spring and early summer are the best

times for heliotherapy for then the ultraviolet portion is strongest. Also the air temperature is such that the middle of the day can be used. In the summer the heat of the day should be avoided and the morning and afternoon hours used. Fresh air baths are an important factor and are responsible in large part for the marked muscular development, and the excellent state of general nutrition that these children show. All children and especially those that are emaciated or are acutely sick must be acclimatized gradually to the fresh air before they are exposed to the sun. Diet needs no special comment except to insist that it be plain, of sufficient amount and contain the necessary building materials. Rest is second only to the ultraviolet in importance and in some cases even more important because if the diseased part is not put

HELIO THERAPY IN EXTRA-PULMONARY TUBERCULOSIS

at rest no amount of ultraviolet will bring about cure. During the acute stage, especially in bone and joint involvement, absolute rest of the part is essential, and this rest must be continued until there is X-ray evidence that there has been healing of the diseased area. Even then an additional four to six months will reduce the number of recurrences. After the subsidence of the acute stage gradual increase in motion can be allowed as it prevents ankylosis but weight bearing should not be allowed for several years. The last factor in heliotherapy is an adherence to accepted orthopædic teaching in all respects except one. We must continue rest in the strict orthopædic sense and we must continue the usual methods for the prevention and correction of deformity, but heliotherapy has introduced one marked departure from the usual teaching. We have been taught that ankylosis, as firm and enduring as possible, is to be sought in all cases involving joints but the introduction of heliotherapy has shown that healing can take place without

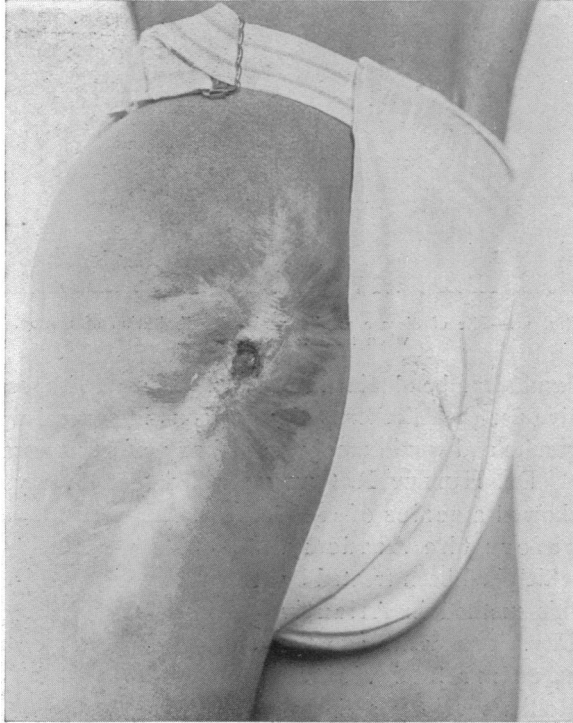


FIG. 10.—Result of heliotherapy in extra-pulmonary tuberculosis.

ankylosis and that a surprising amount of motion can be returned to many of these joints. This, in the speaker's opinion, is the most important change that the use of heliotherapy has brought about. For ultraviolet is not a specific cure for any type of tuberculosis but only puts the patient in the best possible condition to combat the disease with the means that he has within himself.

Just what are the benefits that can be expected from the use of heliotherapy in this type of tuberculosis? First the general results are an enrichment of the blood both in its hæmoglobin and cellular contents, a better appetite and a better digestion, an increase in metabolism, resulting in an increase in general nutrition and the development of a firm musculature and also a change in the mental attitude that in many children is truly remarkable. All these results are well illustrated by the pictures of Case 1 and the general pictures of Case 2.

The local effect on ulcers, sinuses and open wounds is well seen in the pictures of the local lesion in Case 2. Sinuses at first have a more profuse and

thinner discharge but soon tend to heal. Ulcers show healthy granulation tissue and a marked tendency to epithelialize. There is also a marked tendency to calcification of rarified bone as can be seen in Case 3. There is also

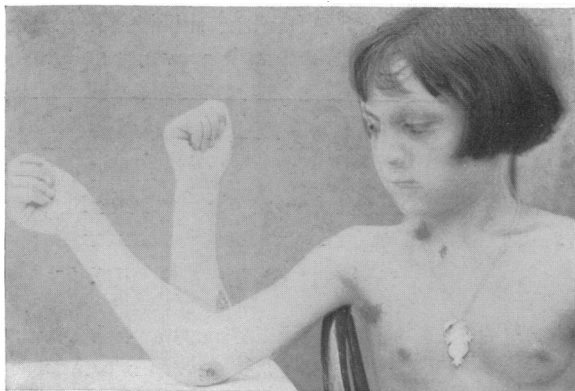

FIG. 11.—Site of disease at elbow, showing limitation of motion, when treatment was begun.

marked tendency to an increased rate of absorption of fluid from the peritoneal and pleural cavities.

The amount of function that can be restored to a seemingly hopelessly involved joint is well shown by Case 4.

These results are not limited to cases with tuberculosis but can be duplicated and even excelled in non-tuberculous conditions. Equally favorable

results can be obtained in adults. DOCTOR ELIASON thinks that a more extensive use of heliotherapy by surgeons in general would lead to very gratifying results and would amply reward any effort necessary.

DR. HUBLEY R. OWEN recalled that three years ago, Dr. A. Bruce Gill showed a series of cases before the Academy, which had been treated by this method in Atlantic City. Two years ago the speaker had visited Rollier's colony and was impressed with the remarkable muscular development in the patients which he saw. There was also a striking absence of wasting and anemia in practically all cases. Doctor Owen said that very little surgery of any sort was done on these patients; for example, tuberculous empyema is never operated upon or even aspirated. Cases of Pott's disease are treated without plaster cases or fixation of any sort.

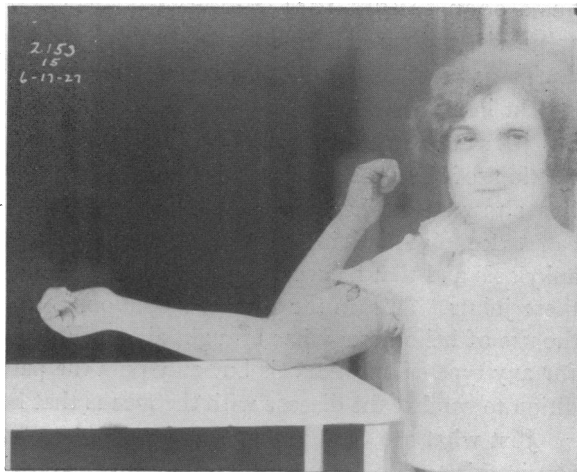


FIG. 12.—Same case as shown in Figure 11, after two years' treatment.

DR. WALTER G. ELMER said that the chief difficulty is lack of facilities for carrying out the treatment. In the Orthopædic Department of the Philadelphia General Hospital, and also in that of the Graduate Hospital of the Uni-

HELIOOTHERAPY IN EXTRA-PULMONARY TUBERCULOSIS

versity of Pennsylvania, the Social Service Departments have great difficulty in placing patients in sanitariums in the country where they can receive the open-air sunlight treatment. Quite a number of them are sent to the Children's Seashore House in Atlantic City, where about 500 can be cared for

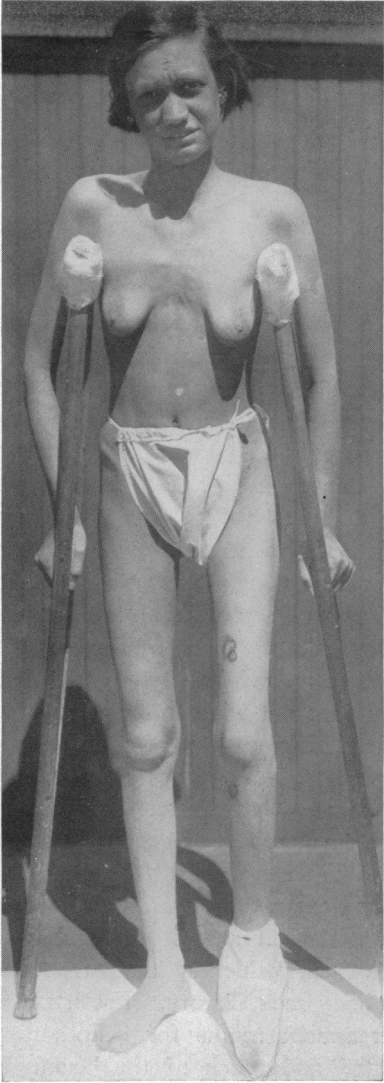


FIG. 13.—Tuberculosis of ankle, condition when treatment was begun.

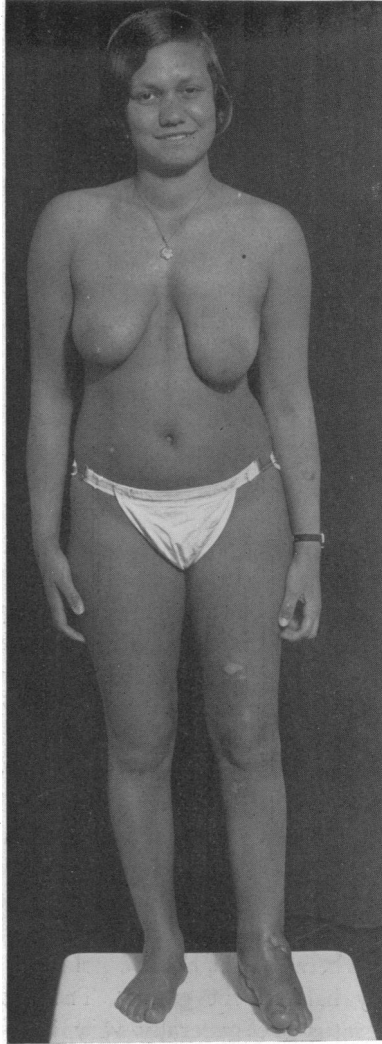

FIG. 14.—Same case as shown in Figure 13, after one year of treatment.

during the summer months—not so many in winter—and occasionally a child was admitted to the Chestnut Hill Sanitarium. If there were five times as many beds available in this latter institution, as there are at present, it could be kept filled throughout the year. It is exceedingly difficult to find a place for a patient over thirteen years of age.

There is no way of treating these patients that can compare with the open-air sunlight method.

DR. RUTHERFORD L. JOHN said that Doctor Rollier does not use the lamps but depends on the sunlight entirely. Here one does not have the sunlight as constantly and so the lamp is of great help. The work which Rollier has done is magnificent, especially in the treatment of tuberculous disease of bones. The older idea that one should be content with arrest of the disease and permanent fixation of tuberculous joints, no longer obtains. Many cases treated by heliotherapy recover without loss of motion in the involved joint.

DR. RICHARD T. ELIASON (closing the discussion) said that he has not resorted to surgery in any of these cases. Some of the cases have had surgical treatment prior to their arrival at the institution, but it has not been found necessary to send any of them back for surgery. The sinuses have healed themselves fairly well except those of long standing, *i.e.*, over five or six years. Where the underlying lesion is a secondary infection, the sinuses are permanent although the amount of discharge is greatly reduced.

As to the lights, the initial cost of the carbon lamps is less than the mercury quartz lamp. There are other types of carbon arc lamps in use, one at the Taft Hospital in Cincinnati is designed for large groups of patients and consists of four large carbon arc lamps suspended from a central pivot. The patients are grouped around the light, the footboards taken off the beds, and the patients are so arranged that the light is cast on them perpendicularly, which tends to greater absorption. As to the comparative value of the carbon vs. the mercury lamps in the treatment of this type of lesion, the carbon arc lamp is considered to be the better for extrapulmonary lesions. The advantage of the mercury lamp is that with it one can give more ultraviolet rays in less time and this is of help in office work where one does not wish to clutter up his office by taking several hours to the one patient. In a number of clinics, especially in Germany, they use mercury lamps reinforced with lamps giving visible light and heat as they believe this to be of value. Gauvain has stressed the value of fresh air as being responsible for the development of the musculature and the subcutaneous fat. He shows that in his treatment of patients at the seashore where children who are unable to walk are carried out into the water the estimation of the metabolic rate before and after shows an increase of about 1000 per cent. He thinks that it is the "kick" which is gotten from the hydrotherapy which is responsible for the body musculature. Fresh air is really half of the game. The ordinary treatment rooms for heliotherapy apparatus are generally very badly ventilated and much of the benefit is thereby lost. Rollier starts his patients with fresh air baths, even before putting them in the sun. This is practiced at Chestnut Hill, the children's garments are taken away from them one by one until they end up in the G-string. With bed patients the amount of bed clothing is reduced until the patient is entirely exposed and they are then put in the sunlight.

SUPPURATIVE PERICARDITIS

DR. EMORY G. ALEXANDER pronounced the annual oration entitled "Suppurative Pericarditis from the Surgical Viewpoint", for which see p. 801.