

when stones are found in the gall-bladder and the common duct is dilated, one ought not to be content with palpation, because one cannot always feel stones in the presence of dilatation, and it is wiser to operate in such cases. His point was for the removal of any stone rather than with the idea of opening the dilated duct. Also, he said that he did not know that this dilatation of the duct is harmful. Judd at an American Surgical Association meeting showed a case of dilatation of the entire biliary tract after removal of the gall-bladder, so that it would seem that dilatation does take place where the gall-bladder is out of commission due to disease. Removal or obliteration of the gall-bladder causes a compensatory dilatation of the duct. Division should be done down close to the common duct; a number of operators think the only thing necessary is to take the gall-bladder out and they often overlook this important point and do a great deal of harm. It must be taken out close to the common duct, regardless of the situation.

STATED MEETING HELD MAY 7, 1929

The President, DR. ASTLEY P. C. ASHHURST, in the Chair,
CALVIN M. SMYTH, JR., M.D., Recorder

COLORED MOTION PICTURES OF SURGICAL OPERATIONS

DR. WALTER E. LEE demonstrated a film of motion pictures of operations, made in colors. These pictures represented the first attempt to make colored reproductions with the artificial light of the operating room. A great handicap has been that in looking at a black and white picture, one keeps trying to interpret the film in colors and this makes it an effort to follow the technic. The speaker did not consider the demonstration perfect but presented the film because it seemed to be the first evidence of success in attempts to employ this method of teaching surgical technic.

TENDON TRANSPLANTATION FOR WRIST DROP

DR. DE FOREST P. WILLARD presented a man who was injured September 27, 1926, when he received ten fractures of the right upper extremity and an injury to the musculo-spiral nerve. At least three of the fractures were compound. He was treated at St. Luke's Hospital, Bethlehem. Open reduction of the fractures of the radius, ulna and humerus were done. All the fractures healed without infection. In April, 1927, a bone-grafting operation was performed for an ununited fracture of the middle of the humerus. In May, 1928, the musculo-spiral nerve was operated on for persistent wrist drop. The nerve was found to be a mass of fibrous tissue, and union of the nerve tissue was found to be impossible. During the past winter he was examined by neurologists in New York and Philadelphia, and further nerve operations were considered useless. Tendon transplantation was suggested. After full discussions of his needs, it was decided that individual extension of his fingers was not necessary, but that strong extension of the fingers to the 180° position and sufficient extension of the thumb extensor and one to the common extensor. This procedure usually functions well for a short period of time, but the weak flexor often proves inadequate for the necessary work and the tendon stretches and the finger flexion recurs. In this patient scars of the operative incisions on the bones of the forearm

ADENOMA OF THYROID WITH TORSION OF LARYNX

lay in the paths of the tendon transplants and it was felt that these might interfere with muscle function. Therefore, to give greater extensor power, the following operation was done January 22, 1929. The flexor carpi radialis was freed from its insertion, dissected back as far as possible and passed around the radial side of the forearm. It was then passed through the extensor tendon of each finger separately (proximally to the annular ligament) and sutured with silk to each tendon. The flexor carpi ulnaris was treated similarly and brought to the extensor surface around the ulna and sutured to each extensor tendon in the same way. This gave the combined pull in the normal direction of the extensor tendons and prevented the dislocation of the extensor tendons to either the radial or ulnar side. The palmaris longus tendon was also freed from its insertion and brought over the ulna and sutured into the long extensor of the thumb. Assisted active motion was started on the third day to prevent the formation of adhesions and active motion began on the seventh day. In ten days the patient was able to actively extend the fingers and strong extension to 180° was obtained in four weeks. He has now actively used his hand for nearly three months and muscular power is increasing.

The case is reported in the belief that the transplantation of two flexor tendons into the finger extensors, one passing on each side of the forearm, will give stronger and more powerful function.

DR. WALTER G. ELMER said that this is the most perfect restoration of function following tendon transplantation in the forearm that he has even seen.

ADENOMA OF THYROID WITH TORSION OF LARYNX

DR. FREDRICK A. BOTHE reported the case of a negress, sixty-two years of age, who was admitted to the Presbyterian Hospital December 20, 1928, in the service of Dr. John Speese, through whose courtesy the reporter was permitted to operate upon this patient and report the case. The patient gave a ten years' history of the gradual development of a thyroid tumor until it had reached the size of a medium-sized grapefruit seated on the left side of her neck but extending well to the right of the midline. Attacks of tachycardia, choking spells and hoarseness have become increasingly frequent and severe.

The patient was placed under the routine management for a toxic adenoma and in addition steam inhalations were administered to decrease the acute congestion of the epiglottis and larynx which was super-imposed upon the chronic congestion. Eight days after admission to the hospital the adenoma was removed under local anæsthesia. The pathologist pronounced it a toxic foetal adenoma. Immediate relief from the choking spells was obtained following the operation but the hoarseness of the voice did not disappear for three weeks. At this time a second laryngoscopic examination was made by Doctor Cariss. The œdema of the epiglottis and the arytenoid area had disappeared. The larynx had returned to the midline and both the true and false vocal cords were normal in position and appearance. She was discharged from the hospital January 24, 1929, twenty-seven days after operation, feeling much stronger, was relieved of the choking spells and hoarseness. Her pulse rate had settled down to 82, was of good volume and her blood pressure had fallen to systolic 138 and diastolic 70. She returned to the Follow-Up Clinic four months after the operation and was relieved of the local symptoms which the adenoma had caused. She had not regained her entire normal strength but was able to do a part of her housework for

the first time in two and one-half years. An X-ray picture of the chest showed the trachea had returned to the midline. She still experiences occasional mild attacks of tachycardia and palpitation. Her nervousness had greatly decreased but had not entirely disappeared.

The degree of torsion of the larynx with œdema of the epiglottis and arytenoids and the marked posterior lateral displacement of the common carotid artery were the findings which prompted the report of this case. The outward displacement of the common carotid artery is of diagnostic value in adenomatous goitres, as in tuberculous or malignant tumors this artery lies in the centre of the mass.

GANGRENOUS INFECTION OF THE HAND AND FOREARM FOLLOWING HUMAN-BITE

DR. JOHN B. FLICK reported the case of a negro man, aged thirty years, who was admitted to the Pennsylvania Hospital December 30, 1927, with the history of having been bitten on the right thumb by another negro five days previously while engaging in a street fight. The hand was greatly swollen, he had a temperature of 102° F. and seemed toxic. The hand and forearm were incised under a general anæsthetic and pus evacuated.

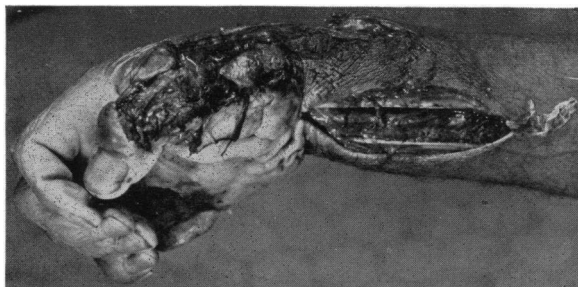


FIG. 1.—Infection of the hand and forearm following human-bite, showing the extensive destruction of tissue.

The tissues exposed in the wound were œdematous and had a peculiar greenish-gray appearance. The odor was most offensive and reminded one of that which is given off in spirochætal pulmonary gangrene. A dark field examination of the pus from the hand showed numerous organisms, some of which were motile and which were

thought to be spirochætes. Subsequent smears showed definitely the presence of spirochætes. A non-hæmolytic staphylococcus albus was isolated on culture, but no growth of the spirochætes was obtained. A guinea pig inoculated in the groin remained healthy. It was killed almost two months later.

Five days after the patient's admission to the hospital it was noticed that he had jaundice and he began to have chills and sweats. There was extensive destruction of tissue in the hand and forearm and amputation of the forearm was advised. (Fig. 1.) This the patient refused. A blood culture taken at this time failed to show a growth. The patient died on January 9, 1928, sixteen days after the injury was received.

While the type of spirochæte was not identified nor the fusiform bacillus of Vincent isolated, this case suggested that the organisms of "Vincent's Angina" so often found in the human mouth might be factors in determining the seriousness of human bites. With this in mind the reporter searched the literature for cases similar to the one cited.

Hennessy and Fletcher report the case of a Malay who was bitten on the left forearm and thumb by another Malay and who developed an infection of the thumb with extensive destruction of tissue and disorganization of the thumb joints. The pus from the wound contained fusiform bacilli and enormous numbers of spirochætes. They refer to other cases reported

GANGRENOUS PANCREATITIS

by Peters. The following is taken from Hennessy and Fletcher's article: "The infection of wounds caused by the teeth has been reported by Peters. In one instance a laborer injured his fingers by striking a man in the mouth. The injury was followed by intense swelling, œdema, and a foul discharge in which fusiform bacilli were discovered in association with streptococci, but without spirochætes. The same author describes the case of a bartender who hit a man in the mouth and injured his own hand. Despite free incisions and soaking in antiseptic lotions there was deep destruction of tissue and the hand did not heal for fifty-four days. In this instance great numbers of spirochætes were associated with the fusiform bacilli. Peters also mentions the case of a seven-year-old child who suffered from partial gangrene of one of her index fingers as the result of infection with spirochætes and fusiform bacilli attributed to the child's habit of biting her nails with her carious teeth." P. H. Hennessy in another article, again reports the Hennessy-Fletcher case given above and adds four cases in which the appearance of the lesion, the character of the pus and the course of the disease strongly suggested infection with the organisms of "Vincent's Angina," but in which no bacteriological studies had been made. A common feature of all the cases reported seems to have been an extensive destruction of tissue.

DR. HUBLEY R. OWEN showed some slides demonstrating similar cases, although he stated the condition in them was not as severe as the form of gangrene Doctor Flick had discussed. He stated that most of the cases which had come to the attention of the Police Surgeon's office had previously been sewed up in some dispensary. While he said he was not prepared to say what was the really correct method of first-aid treatment in these conditions, it is not suturing. In his service he has tried every method of treatment, including the actual cautery and Dakin's solution and still has considerable trouble in preventing ankylosis of the metacarpal and phalangeal joints.

GANGRENOUS PANCREATITIS

DR. ELRIDGE E. ELIASON and (by invitation) DR. JAMES LACEY reported the case of a woman, fifty years of age, who was admitted to the University Hospital, in the service of Doctor Eliason, November 30, 1927, with the chief complaint of abdominal pain and vomiting.

For the past year before admission she had complained of repeated attacks of nausea and vomiting, followed by severe, steady, generalized abdominal pain. The severity of the attack was usually over in four hours and she was entirely relieved of symptoms in twenty-four hours. There was no jaundice, or loss of weight. On admission the patient was having an attack which had lasted four days and was more severe than any previous attack.

On physical examination the abdomen was tender throughout; most marked in the epigastrium. There was rigidity in the epigastrium and moderate distention throughout the abdomen. Peristalsis was practically inaudible. On the day following admission the tenderness and rigidity seemed more marked on the left side of the epigastrium. The leucocytes were 29,200 and the hæmoglobin was 100 per cent. The plasma carbon dioxide was 47 volumes per cent. The urine contained urobilin and bilirubin.

The temperature, pulse, and respiration on admission were 99.2-104-20. A diagnosis of cholelithiasis was made on admission. With the shifting of the pain and tenderness and rigidity to the left side of the abdomen on the morning after admission, an additional diagnosis of acute pancreatitis was made.

At operation, December 2, 1927, the peritoneal cavity was found to contain chocolate-colored fluid and fat necrosis was seen in the peritoneum. The pancreas was swollen and indurated. The entire gland was black in color and gangrenous throughout. The gall-bladder was opened and found to contain several hundred small, yellow stones which were evacuated. No stones were palpated in the common duct. The gastrohepatic omentum was opened, exposing the pancreas. Drainage of the pancreas was established by multiple cautery incisions. The gall-bladder and pancreas were drained, externally.

The post-operative course was stormy and on the fifth day she developed the physical signs of atelectasis of the left lower lobe. The temperature, pulse and respiration remained elevated, the abdomen was distended and there was distressing hiccough. On the thirteenth post-operative day the signs of fluid were demonstrable in the left chest. The blood sugar ranged from 135 to 99 milligrams per 100 cubic centimetre of blood, the patient being on a diabetic diet with insulin. The abdominal wound drained profusely of necrotic material. On the fourteenth post-operative day a small amount of straw-colored fluid was removed from the chest. Aspiration was repeated six days later and 100 cubic centimetres withdrawn. On the twenty-eighth post-operative day a fluctuating mass was palpated in the left upper quadrant. On the thirty-eighth post-operative day the patient was again operated upon and an abscess near the tail of the pancreas drained through the subcostal region of the left loin. This operation was followed by marked improvement. Forty-nine days after operation the chest was again tapped and 650 cubic centimetres of fluid removed. Following this both wounds drained profusely though the temperature was slightly hectic. The patient was allowed out of bed after seventy days from the original operation. A peculiar feature was noted during irrigations of the abdominal wounds; the patient would cough and taste the irrigating fluids and a diagnosis of abdomino-bronchial fistula was made. However, improvement continued and the patient was discharged February 28, 1928, three months after admission. At present she is apparently in perfect health.

INCARCERATED RETROCÆCAL HERNIA—GANGRENOUS APPENDICITIS

DOCTOR ELIASON presented a man, sixty-five years of age, who was admitted to the University Hospital in the service of the reporter, November 20, 1927, whose chief complaint was pain in the lower abdomen, nausea and vomiting and constipation. Seven days prior to admission he drank heavily and ate various sea foods. The next day he complained of pain in the lower abdomen, followed by nausea and vomiting. He was confined to bed from then on; the pain became worse and localized in the right lower quadrant. Vomiting continued and there was no bowel movement from onset to admission.

On admission the temperature and pulse were normal. The blood pressure was 115S-50D. The patient was emaciated and weak. The leucocytes were 17,800. The abdomen was distended and tympanitic. There was tenderness in the lower abdomen, especially the right lower quadrant, where a mass could be palpated. A diagnosis of appendiceal abscess was made and the patient was operated upon immediately. The right lower quadrant

PERFORATED PEPTIC ULCER

was opened through a gridiron incision and a loop of terminal ileum was found to be incarcerated in a retrocæcal hernial sac, with a tightly constricting neck. On stretching the neck of the sac the hernia was found to consist of about six inches of terminal ileum and the appendix which was gangrenous. The ileum had perforated just within the constricting neck and the sac contained pus and some liquid fæces. The perforation was oversewed and the appendix removed. The opening of the pouch was repaired around a drainage tube and an ileostomy was done proximal to the obstructed loop.

The immediate post-operative course was complicated by delirium tremens which cleared up in forty-eight hours. Normal bowel movements started on the fourteenth post-operative day and the ileostomy tube was removed. The patient was discharged December 9, 1927, on the nineteenth day after admission. He is now perfectly well.

PERFORATED PEPTIC ULCER

DR. ELRIDGE E. ELIASON presented a man, twenty-nine years of age, who was admitted to the Howard Hospital May 26, 1922, on account of pain in the abdomen, vomiting and weakness.

The history of illness started three years prior to admission, when the patient was seized with severe pain in the abdomen. Following this attack he was confined to bed for one week. During the intervening three years the patient had repeated attacks of abdominal pain following the ingestion of sweet foods or occasioned by worry. One week before admission he experienced an exceptionally severe attack of pain in the abdomen which was not relieved by the medicine he was accustomed to take. From the onset of this last attack he had vomited everything he ate.

Physical examination was negative save for the abdomen, which was slightly rigid throughout and tender to deep pressure over the epigastrium, especially to the right of the midline. The temperature, pulse and respiration on admission were 99-112-26 respectively. The urine analysis was negative save for a trace of albumin. The leucocytes were 11,400. Laparotomy was performed May 27, 1922, and a duodenal ulcer was found which had perforated. The gall-bladder was freed from the mass of adhesions. The ulcer was oversewed. A posterior gastro-jejunostomy was performed and appendectomy done.

September 18, 1923, the patient was again admitted to the Howard Hospital, complaining of severe abdominal pain, but no nausea. Physical examination of the abdomen showed no distension or rigidity, but two points of tenderness, one below and to the right of the umbilicus and the other at a lower level and to the left of the umbilicus.

The temperature and pulse were slightly elevated. The leucocytes were 16,000. The urine analysis was essentially negative. A diagnosis of perforated jejunal ulcer was made and an immediate operation was performed. The jejunum was slightly enlarged, dull red in color and covered by a small amount of lymphatic exudate. A perforated ulcer was found opposite on the mesenteric border distal to the gastro-jejunostomy. This ulcer was oversewed and a second incision was made to the right of the first, exposing the pylorus which was obliterated by two sutures of kangaroo tendon.

An X-ray examination after discharge showed none of the opaque meal leaving the stomach by way of the pylorus. Following this second operation the patient was symptom-free for five years and held rigidly to his diet until the last few months of this period.

On the morning of January 29, 1929, he was seized with severe, agonizing pain in the centre of the abdomen which did not radiate. He went to work, however, and at the completion of his milk route the pain was still more severe. He was admitted to the University Hospital the evening of the same day. Physical examination of the abdomen at this time showed extreme tenderness throughout the upper abdomen, being most severe in the left upper quadrant. Deep palpation was not especially painful. The abdomen showed very little rigidity, but the wall was extremely thin over the upper half of the abdomen. Peristalsis was diminished. Rectal examination was negative. The blood pressure was 140S-64D. There was slight elevation of pulse and temperature. The leucocytes on admission were 7900, but one hour after admission a second count was 11,400. The urine was negative. An X-ray examination failed to reveal the evidence of gas under the diaphragm.

Laparotomy was done by Doctor Eliason four hours after admission. The gastro-enterostomy site was examined and found to be functioning normally. An ulcer was found on the jejunum proximal to the gastro-jejunosomy. The loop of jejunum distal to the gastro-jejunosomy was firmly adherent to the proximal loop at the ulcer site and there was a kissing ulcer of the distal loop of the jejunum. The proximal loop was kinked and partially obstructed and there was dilatation of the gut above the obstruction. The distal loop was hypertrophic but not obstructed, and showed the scar of previous ulcer five years before. In an attempt to free the adhesions the jejunal wall was perforated at the point of ulceration. The ulcer of the distal loop was found to have penetrated to the serous coat. The ulcerated areas were excised with the cautery and a jejuno-jejunosomy was performed at this site. An area of calcification was found in the right rectus muscle.

The convalescence was complicated by a breaking down of the superficial tissues of the wound and a bilateral basal atelectasis.

SURGERY IN BREAST TUMORS

DR. EDWARD J. KLOPP pronounced the annual oration entitled "Surgery in Breast Tumors; Problems Concerning Diagnosis and Treatment," for which see p. 424.