STATED MEETING, HELD APRIL 2, 1906.

The President, John B. Roberts, M.D., in the Chair.

TRAUMATIC INTUSSUSCEPTION.

Dr. Francis T. Stewart reported the case of a man, aged 30 years, who was struck just above the crest of the left ilium by a heavy steel beam. Shortly afterwards he was admitted to the Germantown Hospital in the most profound shock. At the end of 20 hours his temperature had risen to normal and the pulse had fallen to 110. He had vomited twice and passed 12 ounces of bloody urine. There was great pain all over the abdomen, a large hæmatoma in the left loin, and intense rigidity of the abdominal muscles. Liver dulness was decreased by three finger-breadths, and no dulness could be detected in the flanks. The abdomen was opened in the middle line below the umbilicus and a large extraperitoneal extravasation of blood found extending from the bladder, whose walls were infiltrated with blood, to the left kidney, which was normal to palpation. The abdominal muscles on the left side were torn from the left iliac crest. The peritoneal cavity was opened and found to be clean; there was no visceral rupture. In numerous places the small intestine was tightly contracted, the areas involved varying greatly in extent, so that in certain regions the intestine seemed to be ligatured, while in others it resembled a piece of tape. In one place the contracted intestine had passed into the relaxed segment below for a distance of two inches. The intussusception was reduced, the peritoneal cavity closed and the extraperitoneal tissues drained. The patient died four hours later of shock.

Dr. Stewart observed that every surgeon has probably been struck by the tetanic contraction of portions of the intestine in traumatic cases, and has conceived the possibility of a traumatic intussusception, but of this there is no record. Attention, however, has been called to the fact that this muscular contraction may prevent the escape of intestinal contents for some days, even when the bowel has been completely divided.

In some cases areas of dulness due to the contraction of large segments of bowel may be detected before operation. It may be that in some cases of transient intestinal obstruction after laparotomy for nontraumatic conditions the lesion is a spastic stenosis due to the necessary violence of the operation.

Dr. Robert G. Le Conte briefly described a case he had seen eight years ago which resembled in many points the one reported by Dr. Stewart. A boy of nine was stabbed in the left side of the abdomen, the wound penetrating to the peritoneum, as shown by omental protrusion. Under ether the abdomen was opened and a careful search of the intestine did not reveal any injury. Considerable hæmorrhage had taken place into the abdominal muscles, and also in the peritoneal cavity, from some large vessel which had been severed in the rectus muscle. While searching the intestine for a wound a direct intussusception about an inch long was found about the middle of the small gut, and two or three feet lower down two more were found, one direct, the other retrograde, each about three-fourths of an inch in length, while the sheath or intussuscipiens covering them was probably two inches in length. These intussusceptions resembled in appearance the kind so frequently observed at post-mortem examinations. There was no sign of inflammation, no congestion or change of color in the gut or mesentery, the peritoneal coat was normal in appearance, and reduction was accomplished with very light traction. Treves, in his work on intestinal obstruction, divides invaginations into two great forms, according to the circumstances of their origin: (1) The common or obstructive intussusception, and (2) the intussusception of the dying.

The latter form he attributes to certain irregular peristaltic movements which may be conceived to occur during the act of dying, either from changes in the circulation or from irregular stimulations of the vagi nerves. Such intussusceptions may form many hours after death, as is well illustrated in the case of Rurah (Archives of Pediatrics, April, 1896). While making an autopsy twenty hours after death on the body of an infant he saw an intussusception of the ileum form, and on handling the intestines other portions of the ileum began to invaginate themselves, so that in a few moments the entire small

gut had become a mass of intussusceptions varying from 5 cm. to 10 cm. in length.

In the case reported by Dr. Stewart, and in his own, the intussusceptions present resembled in all particulars the so-called moribund invagination, and not the obstructive intsussusception.

Three theories present themselves as a possible explanation: 1. The mechanical injury to the abdomen (the blow). 2. Hæmorrhage which may produce local changes in the circulation of the intestine or irregular stimulation of the nerves controlling peristalsis. 3. Opening the abdomen and handling the intestines while searching for the wound. This latter would seem the most probable cause.

GALL-STONES WITH ACUTE SUPPURATIVE PANCREATITIS.

Dr. Stewart related the case of a man, aged 51 years, who had suffered with attacks of indigestion for many years. February 25, 1906, he entered the Pennsylvania Hospital in the service of Dr. Le Conte. He had been ill for three weeks with severe epigastric pain, particularly after eating. There had been no vomiting or jaundice, but the temperature fluctuated irregularly, sometimes reaching as high as 103°. The epigastric muscles, especially on the right side, were rigid, and Dr. Thornton, who had had charge of the case, thought that at a previous examination he could feel an indefinite mass; he advised operation, believing the patient to be suffering from cholecystitis, with possible involvement of the pancreas. The urine was normal. At operation the gall-bladder was found tensely distended, the common duct unobstructed, and the pancreas hard lobulated and several times its normal size. There were no adhesions, and the stomach and duodenum showed no pathological change. The gall-bladder was opened and drained; it contained three large gall-stones and a mixture of bile and mucus which proved to be sterile. The cystic duct was filled with a quantity of a sand-and-putty-like material. Two days after operation the patient became slightly jaundiced, and between this time and the second operation he had three chills. The tube drained between one and two ounces of muco-bile during the course of each twenty-four hours. The bowels moved regularly and were always colored. On the eleventh

day the abdomen was opened through a separate incision to the outer side of the original incision, which had become infected. The pancreas seemed to be in the same condition as at the previous operation. Some sandy material had lodged in the distal end of the cystic duct and could only be removed by excising a portion of the duct. A probe passed into the hepatic duct and down in the common duct revealed no obstruction, and these ducts were empty and collapsed. The patient died three days later, the jaundice becoming more intense, but the fever not recurring. At the post-mortem no obstruction was found in the ducts, but the head of the pancreas contained an abscess cavity holding perhaps two ounces of pus, which proved to be caused by the colon bacillus. There was a septic phlebitis of the portal vein and miliary abscesses in the liver. The remaining abdominal organs and the heart and lungs were normal. Quénu and Duval have collected 118 cases of pancreatitis coexisting with cholelithiasis. Of 104 cases in which the seat of the stones was stated, in 56 the common duct was involved, while in 46 the calculi were in the gall-bladder or cystic duct. A study of the relation of the location of the stones to the variety of pancreatitis shows that the chronic form is most frequently associated with lithiasis of the common duct, the suppurative form with calculi in the gall-bladder, and the hæmorrhagic variety with stones in the ampulla of Vater. In 72 cases there was a history of infectious or retention jaundice. Of the 118 cases, 20 were hæmorrhagic, 7 suppurative, 63 chronic, one cyst of the pancreas, and 7 reported as pancreatitis without any other epithet. In the great majority of the acute cases the process was localized to the head of the gland. Abscess of the lesser peritoneal cavity and phlebitis of the splenic or portal vein were common. In 20 cases there was a disseminated fat necrosis.

Pancreatitis developing in the course of biliary lithiasis is generally regarded as a complication. The relation is easily explained when the common duct is involved. The infection spreads by contiguity to the head of the pancreas, by continuity along the pancreatic duct, or it invades the intrapancreatic lymph-glands. Obstruction at the duodenal papilla may cause pancreatic stasis and regurgitation of infected bile, while a stone lodged in the pancreatic segment of the duct may compress the canal of Wirsung and lead to pancreatic retention,

thus predisposing to infection. The passage of a stone by dilating the ducts favors an ascending infection from the duodenum, the contents of which are rendered more septic by the absence of bile. There is no satisfactory hypothesis for the occurrence of pancreatitis in cases in which the stones are lodged in the gall-bladder. Desjardins suggests that the initial infection in these cases is an ascending one which causes cholelithiasis and pancreatitis contemporaneously. Probably in some cases there is absolutely no relation between these two affections. The operative mortality in five hæmorrhagic cases was 100 per cent.; in 16 suppurative or necrotic cases, 50 per cent., and in 62 chronic cases almost 13 per cent. In acute cases the pancreas should, of course, be drained. In the case reported above, the induration felt at the time of *operation* was thought to be due to chronic inflammation, and this may have been true, the suppuration occurring subsequent to the cholecystostomy. The same course was taken in five of the 21 operations for acute pancreatitis reported by Quénu and Duval, with death in each instance.

SARCOMA OF THE OVARY.

Dr. Stewart related the case of a woman, aged 31 years, who was admitted into the Polyclinic Hospital, February 26, 1906. About two years ago the patient noticed a small, painful lump in the right iliac region. The tumor gradually increased in size until at present it almost fills the abdomen. There are irregular attacks of sharp pain which have been so severe during the past two weeks that the patient has been unable to work. The menses began at twelve, are always regular, and last from two to three days; they are more painful but no more profuse since the lump was noticed. There has been no loss of weight or symptoms referable to the digestive or urinary apparatus. The tumor is hard, smooth, symmetrical, and slightly movable with the respirations and on pressure. Pulsation and bruit are quite distinct over the whole growth. There is no œdema of the legs. There is a patch of tympany behind the tumor in the left flank, and dulness in the right flank, giving way to tympany when the patient turns on the left side. The growth was removed through a median abdominal incision about eight inches in length. There were no adhesions and but little fluid in the abdominal cavity. The pedicle attached to the right horn of the uterus was about three inches in diameter. The left ovary, which was about four inches in diameter and cystic, was also removed. At each point where the aneurism needle had been passed through the pedicle of the tumor there was free bleeding. An attempt was made to control this by sutures, but each additional needle puncture also caused bleeding, so that a piece of gauze was pressed against the bleeding points and allowed to remain in place. The patient suffered little shock and reacted promptly without vomiting. At the end of thirty-six hours she quietly began to regurgitate stercoraceous material. Under ether the gauze was removed and a slight kink in the bowel straightened; this did not appear, however, to be sufficiently great to produce obstruction. The patient did not vomit for the succeeding twelve hours, at which time the stercoraceous regurgitation recurred. There was no pain, no fever, and no active peristalsis, although the bowels moved once by enema. The incision was reopened and the entire intestinal canal found moderately distended and motionless. There were no evidences of peritonitis or obstruction. An artificial anus was established by anastomosing a rubber tube to the bowels by means of a Murphy button, but there was absolutely no drainage from the tube until the time of death, which occurred twenty-four hours later. The lesion was probably an intestinal paralysis caused by the sudden relief of long-continued pressure.

The tumor weighs 2830 grammes. Microscopic diagnosis, round-celled sarcoma. Left ovary, angiosarcoma.

PERFORATING TYPHOIDAL APPENDICITIS.

Dr. John B. Roberts reported the case of a boy of nine years, who was admitted to Dr. James Hendrie Lloyd's ward of the Methodist Hospital on January 5, 1906, with symptoms of typhoid fever. The illness was said to have begun seven days previously, when he went to bed with severe headache, but he had had no nose-bleed or pain in the back. There was no cough, and no diarrhœa. When he was admitted to the hospital his tongue was coated; temperature 104°; respiration 26; pulse 108. The abdomen was flaccid, showed no rose-colored spots and was not tender on pressure. The blood obtained on

the day of admission gave a positive Widal reaction, and on January 7th rose-colored spots appeared on his abdomen. His urine showed a specic gravity of 1020, contained no albumen or sugar, and gave the diazo-reaction. The white blood-corpuscles numbered 5600. The hæmoglobin was 80 per cent. The heart and lungs and other viscera showed nothing special, except that the spleen was palpable.

On January 8th the general condition of the patient was good. There was no pain or tenderness in the abdomen. The morning temperature was 102°; pulse 96; respiration 24. In the evening the temperature rose to 104°, with pulse 120 and respiration 24.

In the early morning of the 9th, the patient, after being sponged, complained of pain in the abdomen, and a little later had a distinct chill. His temperature dropped to 100.6°, but subsequently rose to 103°, which was followed by free perspiration and a rapid drop during the evening, until at midnight the temperature was 98°, with pulse 110; respiration 24. During the time of this fall of temperature the patient had marked diarrhœa, with a large amount of mucus, but no blood. The pulse was not altered very much in frequency, but during the period of perspiration the patient seemed weak and the pulse varied somewhat in quality. The patient looked white, and vomited. A blood examination made at midnight by the resident physician, Dr. L. L. Powell, showed 44,480 leucocytes. At 3 A. M. of the 10th the patient's temperature was 97.8°, though the pulse was only 104 and the respiration 24. The patient's facial expression was bad, and there was pain in the abdomen, with marked tenderness, and with rigidity on the right side. Symptoms of perforation seemed sufficiently positive to warrant operation; and Dr. Roberts opened the abdomen about six o'clock in the morning, making an incision 6 cm. long, through the right rectus 2 cm. to the right of the umbilicus, beginning 3 cm. below the level of the umbilicus. The incision ran obliquely downwards and toward the middle line. On opening the peritoneal cavity a small amount of pus was found, but no fæces, among the intestinal coils. It was rather thick and did not have the colon-bacillus odor. The appendix was somewhat swollen and congested, and showed a small perforation near its junction with the cæcum. The lower three feet of the

ileum were inspected, but no perforation was found. The peritoneum of the intestine did not show any discoloration to indicate where the inflamed Peyer's patches were situated. There was no marked congestion of the intestine, and no enlarged mesenteric glands were seen. The cæcum and the first eight inches of the large bowel were examined, but showed nothing abnormal. There were no adhesions about the appendix or the examined intestines. The perforated appendix was excised, and the stump touched with carbolic acid and dropped into the abdomen. A large rubber drainage tube was inserted in the iliac fossa and iodoform gauze placed around it in the wound. Examination of the pus removed from the abdominal cavity showed a few diplococci.

The child's temperature remained at about the normal point for some thirty hours after operation, then began to ascend in a characteristic typhoid-fever curve. A blood examination made the evening of the day of operation gave the positive Widal reaction and showed a leucocytosis of 17,760. The drainage tube was pumped out by means of a syringe every few hours at gradually longer intervals and was finally removed on January 21st. A leucocyte count on January 16th showed that the number of leucocytes had decreased to 7,650. For two or three days after operation there was considerable abdominal distention, which was relieved by enemas of asafœtida. The patient convalesced without interruption, and on February 28th was discharged from the hospital.

Dr. Roberts said that it was well established that the appendix is very frequently the subject of pathological changes during the course of typhoid fever; and that these lesions are similar to those found in the lymphatic structures of the mucous membrane of the rest of the intestine. This may with propriety be termed typhoidal appendicitis. Then there are cases of typhoid fever in which appendicitis occurs from pyogenic infection, just as it may in healthy persons. Kelly and Hurdon discuss these conditions with great fullness. Deaver also devotes much attention to appendicitis coincident with, and caused by, typhoid infection.

In the matter of treatment these authorities are practically in accord. They believe that appendicitis developing in the course of typhoid fever does not call for operative treatment

unless the symptoms are urgent. The access of symptoms of perforation or other grave accident demands prompt surgical interference, in their opinion, but otherwise an expectant policy under surgical supervision is advocated. When surgical intervention is evidently needed, it is to be adopted promptly and carried out with celerity.

VOLVULUS OF THE SMALL INTESTINE IN TYPHOID FEVER, SIMULATING PERFORATION.

BY JOHN B. ROBERTS, M.D.,

OF PHILADELPHIA.

Surgeon to the Methodist and to the Jewish Hospitals.

A GIRL, aged 19 years, in the Polyclinic Hospital, under the care of Dr. David Riesman for typhoid fever, had been admitted on February 9th, and showed the usual symptoms of that disease.

At 9 P.M. on the 22d of the month she began to complain of abdominal pain of a severe character, which persisted throughout the night. On the next morning the patient was listless, with contracted pupils and parted lips; and had a temperature at 2 A.M. of 103.4°; at 8 A.M. of 102.4°. The pulse had not varied much from what it was before the pain occurred, but her respiration was increased. The breathing was mostly abdominal in type. There was slight fulness in the lower right quadrant of the abdomen and extreme tenderness in that region, with marked rigidity and some dulness and impaired resonance. The pain was most marked at McBurney's point. At intervals the resistance lessened. There was no tenderness in the right flank posteriorly. The pulse was of good volume but dicrotic. The liver dulness was preserved and extended to the costal margins. The heart sounds had good tone and were normal. The tongue was dry and could not be readily protruded. At 11 o'clock in the morning of the 23d, tenderness and rigidity were more marked than at 10 o'clock.

When I saw her on the 23d at 11.30 A.M. the whole abdomen was rigid, but the rigidity was much more marked in the right iliac region. There had been no sudden drop in temperature, though in the preceding thirty-six hours the temperature had come down about three degrees and there had been a slight increase in pulse and respiration. At the time of the examination, however, the condition of pulse, respiration and temperature was about that which had existed prior to this gradual fall in the temperature. The patient was crying out at intervals from pain, and gave evidence of great pain when the skin over the right iliac region was even lightly touched. This occurred

even if her attention were distracted from her abdomen, by asking her to put out her tongue. The general symptoms of perforation were not present, but the pain, tenderness and rigidity seemed to indicate some intra-abdominal lesion.

An incision, about three inches in length, was made over the ileocæcal region. No pus or serum was found in the abdomen. There was great difficulty in drawing up the cæcal portion of the ileum, which seemed to be imprisoned in the pelvis and was collapsed. The ileum, above the portion held in the pelvis, was moderately distended, freely movable, and easily delivered through the wound. The appendix was short and bound, throughout its whole length, to the cæcum by a web-like attachment, and pointed upwards. It was not swollen nor inflamed externally, and no concretion could be felt within it. The condition of the appendix seemed to me to be more like a congenital anomaly than a condition due to old inflammatory adhesions. There was no perforation in the appendix or cæcum. After a good deal of difficulty the lower portion of the ileum was pulled up from the pelvis and drawn out of the wound, when it became normally distended. There were no evidences of its having been held by adhesions. About two feet of the ileum, from the cæcum upward, were examined and no perforation found. There was no discoloration of the serosa to indicate the presence of internal ulceration. The gall-bladder was examined, but found normal to touch. It was moderately distended and contained no calculus. The incision was closed, and subsequently healed by first intention.

The patient's pain and the rigidity of the abdomen disappeared after the operation. She went through the remainder of the typhoid fever without abdominal symptoms other than such occasional pain as might be seen in ordinary cases. There was no later evidence that there had been an appendicitis to have been the cause of the pain and rigidity. The slight rigidity and pain, which were subsequently complained of, seemed to be very different from what was present at the time of the operation, and could readily be accounted for by the ordinary nervous condition of the patient. When convalescence seemed almost complete, the patient had a relapse, with comparatively high temperature and an enlarged spleen. From this condition, she gradually recovered.

Consideration of this case seems to show that there was either a volvulus causing constriction of the lower portion of the ileum, or a mild appendicitis, due probably to a typhoid inflammation of the mucous membrane. Because of the critical condition of the patient from typhoid fever, the absence of definite symptoms of appendicitis and the possibility of the condition of the appendix being congenital, the appendix was not removed.

I have come to the conclusion that the symptoms were due to a sudden twist of the ileum, which was finally disentangled, when I turned the coils over and over, in my endeavor to bring the cæcal end of the small intestine up from the pelvis, in which it was imprisoned.

Dr. Riesman writes me that " taken all in all, I agree with you that volvulus or perhaps a localized spasm of the intestine was the cause of the girl's symptoms, which brought her to the operating-table."

The situation of the appendix was very like that shown in Figure 252 of Kelly and Hurden on The Vermiform Appendix and Its Diseases. It is labeled by those authors, " Embryonic Displacement of the Appendix." In this instance, which I am considering, the appendix was much shorter, but it pointed upwards and was similarly adherent to the cæcum.

Had I not found the bowel held down in the pelvis so firmly, I should have been driven to the conclusion that the symptoms were due to an attack of mild appendicitis, which promptly subsided, as not infrequently happens in that disease unassociated with typhoid fever. The woman states that she never had a similar attack of pain or other evidences of appendicitis. I have watched her carefully since operation, and have found no reason to believe that an appendicitis has been present. The operation seemed to exert no influence on the course of the typhoid fever; except to relieve the abdominal pain and rigidity. Intestinal obstruction in typhoid fever from volvulus or other cause appears to be unusual. At all events its occurrence has not attracted the attention in literature that its importance demands. This may be due to the fact that many

cases have been considered to be fatal perforations of the bowel. If no operation or necropsy was performed, the true condition would remain unrevealed.

Dr. Allan Eustis,[1] in a paper read March 11, 1905, before the Orleans Parish Medical Society, records two cases of fatal volvulus of the small intestine, occurring in typhoid fever. He believes that cases occur which are mistaken for perforation of, or hæmorrhage into, the bowel. In his cases the diagnosis was only made by autopsy, and it is probable that in both instances prompt operation would have saved life. The symptoms, according to Dr. Eustis, closely simulated those of perforation, excepting that the leucocytosis was not so high. He says that a localized paresis of the bowels favors the occurrence of volvulus, as does also absence of mesentery in the lower end of the intestine. He thinks that volvulus might occur in cases recovering from typhoid fever, on account of the localized peritonitis so often seen in this disease; and quotes Mayo Robson as mentioning the occasional occurrence of volvulus during colic from cholelithiasis.

DR. EUSTIS'S CASES.

Case I.—A colored woman, aged 22 years, with typical symptoms of typhoid fever, for six and a-half weeks, was seized with violent abdominal pains, referred to the umbilical region, followed by violent and persistent vomiting. The morning temperature had been normal for 15 days, while the afternoon temperature reached 99° or 99.5°. The pain was accompanied by extreme collapse, subnormal temperature and imperceptible pulse. When seen by Dr. Eustis a few hours later her temperature was 97°, the skin cold and clammy, and the pulse imperceptible. She was vomiting almost incessantly and passing loose green stools with an offensive odor. The abdominal walls were rigid and palpation was extremely painful. There was very little tympanites. No mass could be felt through the abdominal walls, on account of their rigidity. The leucocytes numbered 15,000. She died within a few hours, notwithstanding the use of stimulants and external heat.

Post-mortem examination of the abdominal cavity disclosed a volvulus of the middle of the jejunum. The intestine here was intensely congested and almost gangrenous, and was matted down at the site of the volvulus. The mucous membrane from the ileocæcal valve to beyond

[1] New Orleans Medical and Surgical Journal, 1904–1905, vol. lvii, p. 816.

the region of the volvulus showed ulcerations of the Peyer's patches. In some places the ulceration had almost extended to the serous coat of the intestine.

Case II.—About ten days later a similar case was seen by him. It presented the following history: A colored girl, aged 15 years, was admitted to the Charity Hospital on July 22, 1903, in a delirious condition, which prevented the obtaining of a definite history. There was severe abdominal pain which persisted until death. The abdomen was moderately distended, tympanitic and extremely tender to pressure. The extreme prostration of the patient was overcome to some extent by stimulation until three days after admission, when she was seized with excruciating pain in the abdomen, accompanied by subnormal temperature. Vomiting occurred immediately and soon became stercoraceous. Diarrhœa with offensive stools succeeded the constipation which had been present for some days after admission. Cold, clammy skin, imperceptible pulse, and subnormal temperature occurred, and she died on July 27th without rallying from the initial symptoms of shock.

The intestines were found congested, and the solitary follicles and a few Peyer's patches were ulcerated. No perforation was found, but the intestines were matted together by recent adhesions. Four feet above the ileocæcal valve the adhesions formed a flexion about four inches in length producing an obstruction at this site, and there was distinct twisting of the involved intestine. Dr. Eustis believed it probable that both patients could have been saved by prompt surgical interference.

Duliscöuet reports a case of laparotomy for the treatment of intestinal perforation, occurring during convalescence from typhoid fever, in which four days later a second abdominal section was required because of twisting of an intestinal loop.[1]

I have not been able to obtain the original article in time for incorporation in this paper. The double operation was followed by recovery of the patient.

J. Vincent reports a case of intestinal invagination during convalescence from typhoid fever.[2] At the end of nearly seven weeks the man was suddenly seized with abdominal pain and vomiting. Up to that time the typhoid fever had shown nothing unusual, and was of moderate severity and devoid of special symptoms. The diarrhœa had disappeared, and the patient had been free from fever for about two weeks. The man showed depression and complained of a little dull and

[1] Anjou méd. Angers, 1899, vi., 193.

[2] Archives de médicine et de pharmacie militaires, 1895, xxv., 400.

diffused abdominal pain, with occasional colicky attacks. Below the navel and especially above the pubes marked pain on pressure was present.

Vincent was uncertain whether intestinal obstruction or perforation existed. Necropsy disclosed an invagination of the jejunum about 30 centimetres below the duodenum, which completely obliterated the lumen. The invagination was downwards and about 5 to 6 centimetres of bowel were engaged. At a point below, a second invagination was found, but here the obliteration of the calibre was not complete. The typhoid lesions were cured and showed no trace of cicatricial contraction or ulceration.

In Dunglison's College and Clinical Record [1] is mentioned a case of chronic obstruction of the bowel occurring in a man who had had typhoid fever seven years previously. He suffered at the time of the fever with peritonitis and seemed to recover perfectly, but a year later he was seized with an attack of obstinate constipation. Dr. James C. Wilson, who showed the man at his clinic in Jefferson Medical College, stated that such attacks had continued to happen at intervals of eight or ten weeks. Vomiting would occur, and finally the throwing up of great quantities of food mixed with fæces relieved the symptoms until a similar attack took place a few weeks later. The voided matter was a large, irregular mass, showing the appearance of having come through a small aperture and then being coiled upon itself to form a large accumulation. Surgical operation was advised.

G. Harrison Young [2] reports an extensive chronic contraction of the ileum due to typhoid ulceration occurring two and a half years before. It had caused no symptoms until sudden obstruction occurred after a jolt on horseback. The patient died eighteen days later with symptoms suggestive of a second attack of typhoid fever. Examination showed great contraction of the lower twenty-two inches of the ileum, with enormous dilatation above this region. The stricture was due

[2] Medical Press and Circular, December 1, 1886, p. 471.
[1] Philadelphia, 1898, xix., 219.

to two bands, in the submucous tissue, believed to be due to old typhoid ulcerations. There were old cicatrices of the mucous membrane; and four recent ulcers in the ileum, one of which had perforated. There was also a perforation in the cæcum. The reporter did not believe the fatal ulcerations to be typhoid in origin.

Drs. R. H. Harte and A. P. C. Ashhurt mention [1] a case of peritonitis in typhoid fever due to intussusception.

August Hölscher, of Wiesbaden, in a study of the complications in 2000 cases of fatal typhoid fever examined in the Pathological Institute in Munich, mentions that ileus, or twisting of the intestines, was found in three cases.

It is probable that an extended search would show other reported cases of intestinal obstruction, happening in connection with typhoid fever and being responsible for its fatal termination. Enough has been said, however, to convince the thoughtful that acute abdominal crises in this fever should be sufficient warrant for prompt exploratory incision. The innocuousness of such operations skillfully performed, even in the course of this debilitating disease, has been fully established.

Dr. Gwilym G. Davis took exception to Dr. Roberts's statement that perforation of the appendix is more fatal than is perforation of the intestine in typhoid fever; the mortality of the former is generally placed at 50 per cent.; that of the latter, 75 to 80 per cent. One would naturally expect this difference, because if there is a typhoid ulcer of the appendix the patient is very sick of typhoid *per se;* if the appendicitis is separate, then the patient so far as the typhoid is concerned may be in good condition. Then again the appendix is situated at one side of the abdomen and toward the posterior wall, and is at least partly covered by intestines. For these reasons extravasated material from this organ is less apt to extend widely. In typhoid fever the perforation is usually at least a few inches or a foot from the ileocæcal valve, if not in the middle of the abdomen. The fæcal material passes out among the coils of the intestine, adhesions do not form, and general peritonitis is the

[1] Annals of Surgery, January, 1904, p. 23.

result. Intestinal contents are more often poured out from typhoid perforation, as fæces are not commonly found in the cæcum.

Dr. John B. Deaver said he had had some experience with perforation of the appendix during typhoid fever and had successfully operated on cases of this type. Recently he saw a case in which perforation of the appendix and of the intestine both occurred. The condition of the patient was such that operation was not advised, and death soon followed. Autopsy showed a perforation of the appendix and also one of the ileum at a point six inches above the ileocæcal junction. It is generally proved bacteriologically in these cases that the appendicitis is typhoidal in origin. Dr. Deaver has seen but little of intestinal obstruction during typhoid fever. Recently he operated on a case of intsussusception, the diagnosis of which was made by an observant resident physician (Dr. Becker) at the German Hospital. The patient was a woman in the third week of typhoid fever, in whom there developed abdominal pain, shock and fall of temperature. She had not the pronounced rigidity which is so characteristic of perforation. Operation revealed an intussusception of the ileocolic variety, including the ileum for four inches above the ileocæcal valve. It was easily reduced, and in so doing there was exposed an ulcer the size of a quarter. There were also ulcers in the ileum. The patient is now convalescing. Dr. Deaver regards the second case of Dr. Roberts as one of volvulus which was reduced by manipulation.

Dr. John H. Gibbon said the cases reported by Dr. Roberts emphasize the fact that one should operate during typhoid fever if the symptoms warrant it, even though the condition does not suggest perforation. Medical men want the surgeon to assure them that perforation has occurred before they consent to operation. This assurance cannot in all cases be given. The point is that in all cases with pronounced symptoms operation is warranted; if perforation be not found, usually some condition demanding interference, as in the cases of Dr. Roberts, will be present. Dr. Gibbon has operated on two cases of appendicitis during typhoid fever. In one, three ulcers were present, blocking the appendix and causing all the symptoms of appendicitis with an abdominal crisis. The physician asked if he was sure of perforation, and was told no. Operation was then refused,

but permission was finally obtained after insisting that the symptoms warranted opening the abdomen. Dr. Roberts's cases show that one should open the abdomen if the symptoms warrant it, even with the lack of a definite diagnosis.

Dr. William J. Taylor has operated on two cases of appendicitis occurring during typhoid fever, but operated before the appendix perforated; both patients recovered. He believes that when abdominal symptoms in cases of typhoid fever lead one reasonably to suppose there is appendicitis, then he should operate. Both of his patients were benefited by the operation. He intends continuing the use of this method of treatment.

Dr. Gwilym G. Davis said that he did not mean to suggest that Dr. Roberts's case was one of typhoid perforation of the appendix. He has operated on one case of perforation of the appendix during typhoid in which there was also an additional intestinal perforation present.

Dr. Richard H. Harte regards Dr. Roberts's experience as emphasizing the old statement, "When in doubt, operate." There are so many complications during and after typhoid fever that we are led to regard numerous cases as doubtful; this is because no one can tell what is going on within the abdominal cavity. In many cases distinction is not possible, and the surgeon really can only guess what is the lesion; in all these cases operation should be performed. It is a wonder that there are not more cases of volvulus during typhoid fever than are reported, but it is not a common condition. By his colleagues present at this meeting at least one hundred cases of typhoid perforation have been operated upon, the greater number of which were diagnosed before operation, yet Dr. Harte ventures the assertion that among them was no case of volvulus. There are many curious conditions in typhoid fever. In some cases there is a great deal of abdominal rigidity, though in many of these there is no perforation. Cases in which there is sudden onset of abdominal pain, with tenderness and rigidity and a peculiar facial expression, are very important as indicating perforation. In all doubtful cases it is wise to open the abdomen, as this procedure does not materially affect convalescence. Of the 26 cases Dr. Harte had thus treated, two had no perforation, but both patients made satisfactory recoveries. As a sequel of typhoid fever, some cases present, a few months or a year after-

ward, marked peritoneal irritation, probably due to cicatricial contractions. Where the intestine has been studded with ulcers there must necessarily be a great deal of contraction. As a rule these patients die, but a few recover, and these later present curious symptoms of partial obstruction, which is frequently relieved by the intelligent use of purgatives.

Dr. George Erety Shoemaker said that definite localizing symptoms indicating the presence of an acute disabling lesion call for operation during typhoid fever just the same as at any other time. He has operated for appendicitis in one case during typhoid and the patient recovered.

Dr. Francis T. Stewart has operated on several clear cases of appendicitis during the course of typhoid fever, and upon three other cases illustrating the possible findings in cases of like character. One was regarded as typhoid perforation of the appendix, there being in that organ a punched-out ulcer from which fæces were oozing. Recovery. In the second a diagnosis of perforation was made, but operation showed suppurative peritonitis and no perforation. The patient recovered. The third case was diagnosed appendiceal abscess in the course of typhoid fever; operation revealed an enormous mass of mesenteric glands below the cæcum. The peritoneum was clean, and there was no pus in the gland. The patient died of typhoid toxemia at a later period.

Dr. Astley P. C. Ashhurst said that there appeared to be no question that appendicitis is a much less severe condition during typhoid fever than is intestinal perforation. Some patients recover from the appendiceal lesion without operation, and practically all with unoperated intestinal perforation die. Patients who develop appendiceal symptoms during the early stages of typhoid fever usually recover whether operation is performed or not; but during the height of the typhoid fever both statistics and experience show that it is best to postpone operative interference unless it is very certain that the appendix is perforated or that peritonitis has occurred without actual perforation. Dr. Ashhurst had in mind now the case of a child, recently seen, who was suddenly seized with abdominal pain and vomiting. No clear history was obtainable, but in addition to extreme tenderness over the appendix there was high fever and slow pulse. The fever was too high and the pulse too slow

to be typical of appendicitis, so the girl was sent to the Pennsylvania Hospital with a diagnosis of typhoid fever. The course of the disease was long and severe, the child being in the hospital ten or twelve weeks, but finally recovering. It seems probable that typhoid lesions in the appendix caused early irritation, and that recovery would have followed operation early in the attack, just as it did although no operation was performed. The case of intussusception during typhoid fever, included in the statistics published by Dr. Harte and the speaker, and referred to by Dr. Roberts, was one of the Episcopal Hospital cases operated upon by Dr. Hutchinson. The intussusception was gangrenous and irreducible, and a resection of the gut was therefore done, with circular enterorrhaphy; but the patient was too ill to stand the shock of the operation and died shortly afterwards.

Dr. Robert G. Le Conte said it must be remembered that the diagnosis of an acute abdominal crisis in the course of typhoid fever is often uncertain, particularly in the third and fourth weeks of the disease, when the patient is markedly adynamic with either stupor or delirium. Under such circumstances the three cardinal symptoms of peritonitis,—namely, pain, localized tenderness and rigidity,—are often absent, and few of the secondary symptoms may be present, such as changes in temperature and pulse rate, vomiting, distention, dulness in the flanks, etc. In these cases the surgeon cannot make a diagnosis of perforation at his first visit, for the symptoms present are so masked by the toxemia of the patient, or come on so insidiously, that an exact diagnosis is not possible.

Dr. Le Conte then briefly detailed two cases.

The first, seen about two weeks ago, was a woman of twenty-five in the fourth week of typhoid fever. She was delirious, picking at the bed-clothes, and profoundly toxic. The abdomen was distended and tender, but there was no rigidity, and no pain was complained of; no change in the temperature or pulse-rate, and the ear could not detect signs of peristalsis in the abdomen. An immediate operation revealed perhaps more than a quart of pus in the abdominal cavity, which was free from adhesions.

The second case, seen to-day, was a boy of seventeen, in the nineteenth day of his illness. He was profoundly stupor-

ous and toxic. The abdomen was distended and rigid, with some tenderness; no change in the temperature or pulse-rate. The attending physician had diagnosed perforation. In consultation with Dr. Harte it was agreed that an exploratory incision should be made, but that the diagnosis of perforation was doubtful. The abdomen was opened and no sign of peritonitis was present.

Both cases were markedly distended, and in neither was there any alteration in the temperature or pulse. The one with peritonitis had tenderness but no rigidity, while the other was rigid without any mark of tenderness. These cases illustrate the difficulties of an exact diagnosis at the first visit, and yet in both an immediate operation was deemed advisable.

Dr. Roberts, in closing, said he was indebted to Dr. Davis for calling attention to his erroneous verbal statement in regard to the comparative mortality of perforation in the appendix and the ileum in typhoid fever. The statement was not contained in his paper, but was made during the introductory remarks. He rather feels that appendicitis, if it be not true typhoidal appendicitis, should be operated on in typhoid patients with pretty much the same urgency as in appendicitis occurring in patients not suffering from typhoid fever. A carefully-performed operation in competent hands, with proper surroundings, will probably not influence unfavorably the course of the enteric fever. It may even be done under local anæsthesia, if general anæsthesia is considered unwise.

Fig. 1.

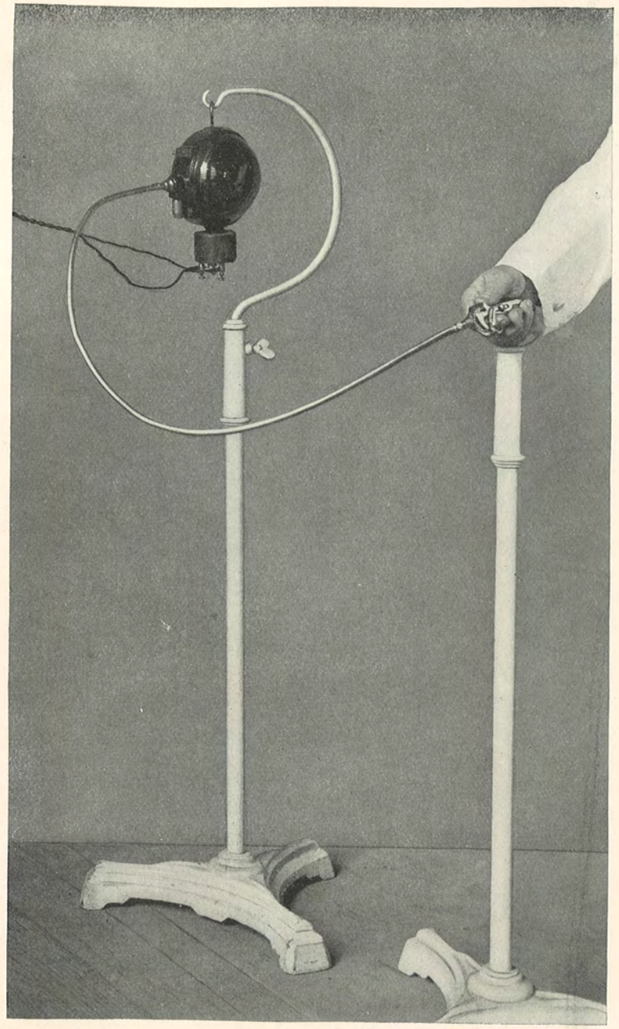

ON THE USE OF THE MASLAND SAW FOR OPENING THE CRANIAL VAULT.

BY H. C. MASLAND, M.D.,

OF PHILADELPHIA.

About one year ago when we first presented before The County Medical Society a new cranial saw, utilizing the power-driven circular saw principle, we felt that the ideas involved and the practical applicability were assured.

Since then we have studied carefully the details of construction so as to produce an instrument thoroughly reliable under all circumstances. The only change made in the saw itself has been to increase the diameter of the circular saw, thereby insuring ability to cut through the thickest skull that might be encountered.

The motor is a sixth horse-power, which has been demonstrated strong enough to drive the saw with perfect ease through the hardest bone.

The flexible cable has been made stronger. It is strong enough to stop the motor without injury to the physical condition of either motor or cable.

It will be seen that a motor ample for any demand of power required, and a cable strong enough to drive the saw with certainty and steadiness through the hardest bone, and yet stronger than the motor itself, secures a reliability of mechanism above every requirement.

The saw is so simple in construction that it can hardly get out of order. The chief necessity is to see that the bearing of the saw shaft is lubricated with a sterile oil. This is done by dropping, as needed, oil in the oil-hole provided at the side of the bearing.

It is appreciated that this instrument opens the skull with a smaller waste of bone-tissue than any other instrument yet devised. The width of section, but one millimeter, and the bevelled cut, permits the replacement of the bone flap on a

firm shelf with insignificant sinking of the flap; securing, in other words, a postoperative condition as substantial as before the skull was cut.

We have demonstrated that the skull can be entered with this instrument by either of two methods of operation, each of which has certain advantages which will recommend the one or the other to different operators. The plan of operation depends upon whether one prefers the inside or the outside guard.

In my former paper, I advocated the use of the outside guard. This method does not require the making of any

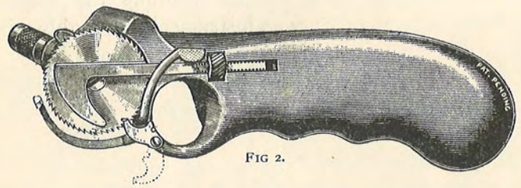

FIG 2.

FIG. 3.

preliminary openings. The osteoplastic flap is, preferably, four-sided, with the shortest side at the basal portion of the skull. This side is to be left uncut for the retention of the vitality of the flap. With a scalpel the flap is outlined in the soft tissue and the tissue cut to the bone surface.

Leaving the flap adherent to its underlying bone, the tissue on the outer side of the incision is dissected away to allow the easy access of the saw. The guard is then set for a depth that we are reasonably sure will not penetrate the thickness of the skull. The saw is always held with the cable side overhanging the flap. This permits a better observation of the section and makes more easy the bevelling of the incision through the bone. After the first cut, the incision is percussed

with a bone-sounder which I have devised for the purpose (Fig. 3). A trained ear can learn from this the relative thickness of the uncut bone. According to one's judgment the guard can then be set coarse or fine. It is possible to set the guard for a difference of one one-hundredth of an inch. Naturally the skill of the operator is called in play in making the final incision through the skull to protect the dura. Only the exercise of undue haste would result in injury to the brain-tissue. After completing the bone sections, soft-tempered steel chisels are inserted in the cut bone at opposite sides of the flap. Springing the flap up with these chisels the remaining short side is broken and the vitality of the flap thus preserved.

It will be seen that the chief problem involved in the use of this saw is to make the section without injury to the subjacent dura. The saw, rotating 1,500 or 2,000 revolutions per minute, cuts the bone with practically no pressure on the part of the operator. As to the mere cutting of the bone the question of time is eliminated. The greatest care, however, should be exercised in the final stages of the section. It is true that the tactile sense with this instrument is preserved, and surgeons have expressed the opinion that they could tell when they have entered the skull cavity without the use of the guard. I would advise, however, the taking the time with finely-graded adjustments of the guard to prevent injury to a dura intimately attached to the bone. In my judgment the chief necessity for this care is to obviate hæmorrhage by cutting a dural vessel. True it is preferable to cut the dura subsequently inside the line of the bone incision to facilitate suturing, but the only ill effect arising from simple cutting of the dura by the saw would be the more troublesome subsequent suturing. Hernia cerebri considering the perfect bony support, is impossible.

It is evident that this instrument, notwithstanding its ability to make a flap superior to all others, must still be able to cut the bone with as little or less injury to the sublying tissues than the best of the others, to entitle it to recognition as being distinctly superior.

The method just described will accomplish this better than any other instrument yet devised with the exception of the Cryer drill. I believe however that with the use of the inside guard on my saw, the dura can be protected from injury with absolute certainty. Using this method the outside guard is discarded. The skin section is made as before mentioned. At the two superior angles of the flap, preliminary openings are made about 3-16 of an inch in diameter, the guard, de-

FIG. 4.

tached, is then entered in the opening and the dura pressed away from the inner table of the skull. The saw is now used to cut two grooves in the bone chiefly to the outer side of the opening and almost through the bone (Fig. 4). These cuts are made in the lines of the intended bone sections. They permit the entry of the guard in a more oblique manner.

The shaft of the guard, now attached to the saw, occupies this groove and is supported by its sides. The idea of this groove is to give the saw more room so that it may cut the more easily the bone at the side of the opening. The guard is now kept by the pressure of the thumb on the handle arm in constant contact with the inner wall of the skull, and the incision is advanced. It will be noticed that the guard, to prevent its own destruction, does not come in immediate contact with the teeth of the saw. As a result of this, a thin section of the bone on the inner table of the skull may remain uncut. So soon as the handle-arm of the guard presses upward this condition is in all likelihood present. The advance of the saw is immediately checked, then by pressing the handle of the saw downward, practically rotating it downward with the guard-tip as the pivotal point, the guard sinks deeper and presses the dura away, the saw also sinks deeper and cuts through this remaining portion. The further progress of the incision is then pursued. Starting on a new line of incision the guard is adjusted in the opening and this side of the flap cut as before.

It is always to be borne in mind that when the handle-arm of the guard rises up against the thumb, the advance of the incision should be checked, and the reason for this movement of the guard ascertained. If we find that the bone has been cut through, then it may be an internal ridge of bone or an adherent dura giving the trouble. Should it be a ridge the only care is to have the guard advance over and past it without deflecting into the deeper tissues. This should give no special trouble. It may be that the dura resists the detachment by the guard. Should this occur it is better to detach the guard from the saw, and using it as a blunt dissector coax the dura away from the bone as far as the guard can be advanced. The saw is then attached and this portion of the bone divided. This process can be repeated as often as necessary. The essence of careful surgery would recommend this as the absolute method of preventing injury to the underlying tissues.

I am confident that the plan of operation I have outlined,

which takes longer to tell than to perform, removes with certainty the liability of injuring the dura or producing serious hæmorrhage. The bleeding that would ensue would be the usual bone bleeding that is expected.

The subsequent breaking of the undivided side of the bone-flap is performed as before, and is familiar to all.

In claiming for this instrument a superiority as to method and results over all other instruments used for the purpose, it may be well to mention some of the chief disadvantages of these instruments and show wherein this new one excels.

The hand trephine, descended to us from remote antiquity, requires but little notice. Its tendency with the best of care to injure the dura or even the brain-tissue is known to all. It destroys the vitality of the button of bone, and makes an opening restricted to the fixed diameter of the trephine in hand. It is tiresome, dirty and practically abandoned by the advanced cranial surgeons.

The Stellwagen trephine is a considerable improvement, but it is still possessed of many of the defects of the original trephine. It is very tiring to the hand and is easily capable of injuring the dura and causing serious hæmorrhage. It does not permit of a bevel edge and the sustaining shelf so desirable. There is a tendency to jam consequent upon and inseparable from its mechanical construction. This jamming is intensified as the cut becomes deeper. Subsequent enlargment of the original opening must be made with the bone forceps, with a resultant waste of bone.

The mallet and chisel are probably used by more of the best surgeons to-day than any other instruments. Yet after all such weapons are a shock to us, more to the laity and most to the unfortunate victim requiring its use. The charge has some merit that more perfect instruments should have been devised long ago. Yet we are aware that the mallet and chisel have many elements of superiority. They permit of sections of any desired shape and size, and they permit of reposition of the bone-flap upon supporting spicules of the surrounding bone, giving results possibly attained by no other instrument hereto-

fore used. The objections to the chisel are the length of time required to make the bone-flap, the concussion that undoubtedly does add to the risks of the patient, and the great likelihood of the bone suddenly giving away and the skull contents being injured. The difficulties of the mallet and chisel increase many fold with an unusually thick or hard skull. While a surgeon with much practice may become high-master in the use of the mallet and chisel, yet all appreciate that its use generally is fraught with many perils.

The foregoing instruments have the advantage of cheapness and that they are dependent upon no mechanism restricting the wide range of their usefulness.

The Cryer instrument, devised by Dr. Cryer of this city, is a departure from the principles of its predecessors. It receives its cutting power from a mechanical source external to the operator. A side-cutting drill is used to make the section in the bone, and an inside guard is provided that protects the dura from all possible injury. The flap section is made large or small at the will of the operator. Celerity is attained, hæmorrhage is avoided, and a vital flap is secured. Some of its disadvantages are that it makes a wide incision of the bone, not permitting the shelf support so desirable. The drill is necessarily slender, to make a reasonably narrow incision. Inasmuch as the force is applied against the long diameter of the drill, the point of least resistance, the drill must not be pressed too hard against the bone or it will break.

The inside guard prevents the instrument being withdrawn till it is carried back to the original opening. This may present a very considerable disadvantage under certain circumstances. The operator's hand must constantly occupy a constrained position in keeping the guard up against the inner wall of the skull.

An instrument devised by Alfred Sykes, of Yorkshire, is a modification of the Cryer instrument having a handle at right angles to the drill-shaft. This instrument, of which I have seen the illustration only, possibly relieves this un-

comfortable position of the hand, though I would not judge it as useful as the Cryer instrument in other respects.

While the Cryer instrument can be sterilized, its structural parts cannot be dissociated by an amateur for thorough cleansing purposes.

The Doyen saw utilizes the circular saw but without an efficient guard to adequately control the depth of cut. Its construction does not permit that steadiness and fine control which is an essential in this class of instruments. I am informed by Prof. Keen that as he saw it used it was no more rapid than he found possible with his mallet and chisel.

The Doyen small saw is a Hey saw with the addition of an adjustable guard. It is subject still to practically all the disadvantages of the Hey Saw.

In the Sudeck instrument the circular saw is placed between the handles. The instrument is grasped as a woman would grasp the handles of a rolling-pin. It does not have an adjustable guard. While by no means devoid of merit, yet its construction prevents the utilization of many of the principles which are necessary to make a thoroughly practical saw. The defects of the foregoing instruments are apparently overcome by my new saw.

The osteoplastic flap can be made any size or shape.

The time required to make the cut is as short as can possibly be hoped for.

When using the outside guard, it is impossible to cut deeper than the depth set by the guard.

The likelihood of hæmorrhage, particularly with the use of the inside guard, is obviated.

The incision is but one millimeter in width, whatever the thickness of the skull.

Perfect bony support for the reposed flap is secured to a degree not heretofore obtained, giving perfect bone protection to the brain.

The instrument gives no vibration, a thoroughly comfortable grasp to the hand, and occasions no tension of the hand, permitting a full utilization of the sense of touch.

The inside guard, when used, can be detached immediately and the saw at once withdrawn from the cut.

The saw is so simply constructed that by observing a few simple rules no mishap in its working should occur. Further the construction is so simple that a nurse or an amateur can take it apart and cleanse it thoroughly, replacing the parts without trouble.

It will no doubt take time for the profession to accustom itself to this new instrument, but I firmly believe that a utilization of the principles here involved will open up a new field in successful and more perfect surgery of the brain.

Dr. M. H. Cryer said that about 1891 a circular saw was devised with various guards to regulate the depth of penetration, also with an underguard which would pass between the dura-mater and the inner plate of the bone, thus dissecting the membrane from the bone and preventing the saw from cutting it. This instrument with an upper guard was used by him in helping Dr. W. W. Keen to open the brain-case for the removal of the Gasserian ganglion on October 18, 1893. The following is a quotation from Dr. Keen's report of the case: "An omega-shaped incision was made the length of which vertically was three inches; one leg terminated in the front of the tragus, the other just in front of the junction of the anterior and middle third of the distance between the auditory meatus and the external angular process. The temporal artery was cut, and that and a few vessels required ligation. Dr. M. H. Cryer, with a surgical engine of S. S. White Co., and a circular saw one and a-half inches, with guard, then rapidly and very successfully divided the external table excepting at the two extremities."

On receiving the invitation to discuss Dr. Masland's paper, Dr. Cryer went to his instrument morgue and resurrected this instrument spoken of by Dr. Keen as doing the work "rapidly and successfully." Tied to the instrument is another upper guard so arranged that the blood would not be thrown upwards. There are also two lower guards with it, intended to dissect away the dura and at the same time prevent the saw from cutting it, all of which is quite similar in principle to those described by Dr. Masland.

Although the circular saw with its upper guard worked fairly well, Dr. Cryer was not satisfied with it, as he felt that for his use an instrument must be made that would cut any thickness of skull in straight or curved lines without withdrawing the osteotome, and with great rapidity and absolutely no damage to the dura-mater. A guard therefore must be made to work on the inner side of the skull, and must be capable of turning on a very short curve without catching or tearing the dura. As such an instrument had been thought of at the time of the Keen operation, it was but a short time afterward that the one known as the spiral osteotome, with its underguard, was devised and used by others as well as himself. This cutting instrument has been spoken of as a drill by Dr. Masland. This is quite a mistake, as a drill is known to mechanics as an instrument for drilling a hole, usually in hard substances such as stone, metal, etc. The instrument in question is not a drill, as it would be impossible to drill or even bore a hole with it. It is as absolutely a side cutting instrument as any saw could be; in fact, in one sense it is a circular saw with three teeth or spiral blades cutting in the line of its shaft instead of at right angles. The instruments were presented. There are three hand-pieces which are all interchangeable with the instruments. In one hand-piece there is a very small trephine for making the initial opening if so desired; in another a spiral osteotome with its guard which cuts a kerf about one-eighth of an inch in width. In the third a spiral osteotome which is somewhat finer and cuts a less track. A still finer one can be used. This instrument is the ideal one to the speaker for opening the brain-case. It may not be for others, as to a certain extent each one should judge for himself, as every man ought to use the instrument with which he knows he can do the best work. But apart from the advantage of having a person use the instrument to which he is most accustomed, the best appliance is undoubtedly that which is so constructed that it can be used successfully by the greatest number of men and do its work well under the greatest variety of circumstances. For this reason the younger surgeons should adopt the use of the most modern and efficient instruments that are presented to the profession.

The circular saw, driven by a light spiral cable for craniotomy, has inherent defects. The cable does not give a steady motion, it is liable to have what is known as "back-lash," and will chatter if the saw becomes the least bound or if a greater force is suddenly required. The saw cannot be used in making a curved incision when cutting the full depth of bone. It has to be lifted out for each change of direction, and will make an ugly cut at corner. It cannot be regulated by an upper guard to the varying thickness of the skull that is being cut. An underguard, if properly constructed, would allow any varying thickness to be cut, but an extra opening would have to be made by a trephine or the mallet and chisel to allow the entrance of the guard for nearly each direction cut. This would take considerable time. For these reasons he had long ago discarded the use of the ordinary circular saw with its upper and lower guards.

Dr. Thomas C. Stellwagen said he did not question the efficacy of the instruments of Drs. Masland and Cryer in their own hands, but personally he had tried them and found that special training was necessary for their use. This is especially needful to avoid injury to the brain and to the middle meningeal artery. None of these instruments can be thoroughly controlled, and to use them safely the surgeon must be trained by many operations on the cadaver and by using the instrument every day. The Masland saw is difficult of sterilization when oil is being slung from it, as is constantly done. As to beveling the edge of the bone, this is not necessary. In a number of cases the bevel is not of great advantage. Another point is that the external table and diploe should be sawed and the internal table broken with a chisel instead of being sawed through as is done with these instruments. It is impossible to saw through the inner table without injuring the dura unless the operator is perfectly trained. None of these special instruments, including the one devised by himself, is being used by surgeons, because they have not time to perfect the use of the device.

Dr. Gwilym G. Davis saw a year ago an instrument devised by Dr. Codivilla, of Bologna, which very closely resembled that of Dr. Stellwagen. As to the general question of surgical engines, they may be used to bore holes and they can be used with burrs, trephines and saws, as shown by the demonstrators. He became interested in the matter some years ago, and

found that for boring ordinary holes the engines are admirable. There is some difficulty in sterilization and in other points, but these give no special trouble. When it came to using burrs he found he could obtain better and quicker results with a mallet and gouge. With the trephine he used the engine in an intracranial neurectomy case. A guard was carefully applied, and he practised diligently on the dead body until he could cut just to the dura-mater without injuring that structure. On the patient, although he was more careful than with the cadaver, the trephine cut entirely through and brought up the dura with the bone. The patient died of meningitis. He then tried opening the skull with saws, but found it difficult to get saws that would work. Guards were made for the saws, but this method was finally abandoned because it was necessary first to make a trephine opening and also because the guards, in order to work, were so thin that they were liable to perforate the dura. It was desirable that the saws should cut a circle, and he had saws made for this purpose, but a guard could not be used with them and there was a tendency to jam. This latter fault is common to all these mechanical saws. His engine is now in the anatomical laboratory and he concludes they are all of little practical value except Dr. Cryer's method of first opening the skull and using his recently perfected fine cutting osteotome. In his work he prefers a gouge instead of an engine. The bevel of the gouge should be on the under side, however, instead of upper, as they are commonly made.

Dr. John B. Roberts said that he had long been interested in improvements in methods of opening the skull. Some twenty years ago he had suggested and experimented in making openings of various shapes in the skull by means of a flat burr driven by the dental engine. This was before surgeons knew that osteoplastic cranial flaps were practicable, and that pieces of bone could be replaced in the trephine opening with the probability of retaining life and closing the opening. He published a paper on this subject at that time in the Philadelphia *Medical Times*. Subsequently he had devised an aseptic trephine, which has been a good deal used, and also invented a segment trephine for removing a button when the thickness of the skull varied very much in different parts of the circle to be removed. At the present time he feels a little inclined to agree with Dr.

Davis in the opinion that many of the modern devices driven by electric motors are too complicated to be employed in occasional operations. They are, however, undoubtedly valuable in large hospitals, where they can be kept in order and where they will be frequently needed.

Dr. Cryer, in closing, stated his preference for the straight barrel trephine for making the initial opening, which, if held perpendiularly to the skull and with the hand resting upon the skull, can be accurately manipulated. It takes practice to use it properly; then one can use the instrument without injuring the dura. He showed another instrument which stops when it passes through the bone, and no amount of pressure will make it go deeper, as it is made to choke when it passes through the hard tissue. In all delicate surgical operations ne prefer's the "cord" engine, because it runs without vibration or "back-lash," the hand-piece carrying the cutting instrument can be carried in any direction without moving the engine, and if the cutting instrument is caught the cord will slip and practically no harm be done. One disadvantage with instruments of the type shown by Dr. Masland is that the hand-piece being fastened to a comparatively rigid shaft, the operator cannot cut the various sides of the flap without moving the entire engine, which would be very inconvenient, besides impracticable in actual surgical work.

Dr. Masland, in closing, said that the back-lash of the dental cable is prevented here by dispensing with the flexible wrist connection, and using a heavy cable. The attendant who has charge of the motor can at the same time gently support the cable, and so prevent any drag it might otherwise have on the saw. The cable is superior to the belt in that both cable and sheath can be sterilized, whereas with the belt we have an unsterilizable and rapidly moving belt and gear in immediate proximity to the seat of operation.