REFERENCES.

[1] Pfitzner, Morpholog. Albeit. de Schwalbe, Jena, 1892, Bd. 8.
[2] Fawcett, Jour. Anat. and Physiol., 1897, vol. xxxi, p. 157.
[3] Stieda, Beit. zur klin. Chir., 1904, Bd. 42, s. 237.
[4] Dwight, Variations of the Bones of the Hand and Feet.
[5] Momburg, Deutsche Zeit. f. Chir., 1907, Bd. 86, s. 382.
[6] Stieda, Munch. med. Woch., 1906, Bd. 53, s. 1954.
[7] Wolff, Berlin. klin. Woch., 1904, Bd. 41.
[8] Pancoast, Univ. Penn. Med. Bull., 1909, vol. xxii, p. 213.
[9] Painter, Bos. Med. Surg. Jour., 1910, vol. clxiii, p. 363.
[10] Preiser, Arztliche Sachverstand, 1907, s. 400.
[11] Morian, Deutsche Zeit. f. Chir., 1909, vol. clxiii, s. 363.
[12] Schunke, Monatschr. f. Unfallheilk., 1901, s. 242.
[13] Marx, Munch. med. Woch., 1904, Bd. 51, s. 1688.
[14] Muskat, Deutsche med. Woch., Jahr 32, s. 1319.
[15] Igelstein, Deutsche Zeit. f. Chir., 1908, Bd. 93.
[16] Stumme, Fortsche. auf dem Gebiet. du Röntgen, 1909, Bd. 13, s. 312.

NOTE.—There are two instances of luxation of the sesamoids on record, viz., Karschulin (Wiener med. Woch., 1906, No. 17, s. 814) and Perlman (Deutsche Militar. Arztl. Zeit., 1904, s. 474).

STATED MEETING, HELD DECEMBER 4, 1911

DR. R. G. LE CONTE, President, in the Chair.

A CHILD WITH RUDIMENTARY LEFT UPPER EXTREMITY (PEROBRACHIUM).

DR. PENN G. SKILLERN, JR., exhibited the patient. He was a male, aged 5 years, the second youngest child of healthy and normal Irish parents. Five brothers and sisters healthy and well formed. Patient presents no other abnormalities or defects, congenital or acquired.

As shown by the sketch (Fig. 1), the left upper extremity is very rudimentary, extending but little more than half way down the chest wall, to which it is adherent, instead of down nearly to the left knee. The limb terminates in a free foot-shaped projection, of which the heel corresponds to a rudimentary thumb and the remainder to a partially flexed and fairly well-developed index-finger.

Movements of the limb are principally elevation of the shoulder and flexion of the remaining dwarfed segments.

External examination reveals a fairly well-developed clavicle, an acromion, a very small humerus, an elbow-joint, small forearm bones, and in the index small nodules of bone corresponding to a carpal, a metacarpal, and a phalanx. The presence of the elbow-joint was confirmed by Dr. Astley P. C. Ashhurst.

Internal examination by Röntgen rays served to orientate the skeleton of the limb more accurately. The first skiagram taken (Fig. 2) shows a comparatively well-developed clavicle, a rudimentary acromion, coracoid process, humerus, forearm, carpal, and digit bones. As it was afterward determined, the scapular spine was obscured in this picture by the shadow of the clavicle. Because the glenoid rim and elbow-joint were not well shown, another skiagram was taken (Fig. 3). Now the upper extremity of the humerus was found in juxtaposition with a rudimentary glenoid, from which there faded away below an indistinct axillary border. The scapular spine is now shown. The position of the elbow-joint is brought out by the partially flexed forearm. The radius and ulna here form a common shadow.

Epiphyses are lacking, and the bones have advanced but little in development beyond a stage represented by the early months of intra-uterine life.

It is not claimed that this interpretation of the skiagrams is wholly accurate, but it is the result of careful study, in which the author sought the aid of Professors G. A. Piersol, H. K. Pancoast, G. G. Davis, and T. T. Thomas, and the artist, Mr. Erwin Faber. The case occurred in the service of Dr. B. A. Thomas, at the University Hospital.

To crown the interest of the case there is the usual history of maternal impression. The mother, when two months pregnant, answered the door-bell in response to a mendicant who exhibited to her his left shoulder, which bore the stump remaining after a railroad-amputation of the upper extremity.

LITHOTOMY UNDER SPINAL ANÆSTHESIA.

Dr. Harry S. Carmany read the history of a man, 61 years of age, who was admitted to St. Timothy's Hospital with a vesical calculus. On account of a chronic cough it was thought a suitable case for spinal anæsthesia, which was employed according to Professor Bier's original method, between the fourth and fifth lumbar vertebræ, first using ½ c.c. of a 1 : 1000 adrenalin solution, along with 2 c.c. of normal salt solution, waiting five minutes and then introducing 2 c.c. of a 1 per cent. solution of cocaine. After waiting ten minutes the operation was proceeded with. Anæsthesia was complete from twelfth rib down. Operation was started about 5.10 p.m. and completed about 5.40 p.m. Did not have return of sensation until 7 p.m. and was not complete until 9 p.m., although at 5.50 patient had profuse sweating, was slightly excited, felt a little faint, and had a subnormal temperature. Strychnine and atropine were given with prompt improvement. At 8.30 was given alcoholic rub, as sweating was still profuse. The stone was removed suprapubicly, with drainage tube for four days, when permanent catheterization was instituted for a week or ten days. Convalescence uninterrupted. Suprapubic wound healed four and one-half weeks after operation.

Dr. B. A. Thomas called attention to another method of removing vesical calculi, particularly small ones not more than half a centimetre in diameter, namely, by the use of Young's cystoscopic rongeur. About six weeks ago he had a case in which there were two small calculi which were removed by this method. The device consists of a beaked instrument shaped somewhat like an ordinary urethral sound which opens out on a hinge on its posterior surface like a clam shell, and passing

Fig. 1.

Rudimentary left upper extremity (perobrachium).

Fig. 2.

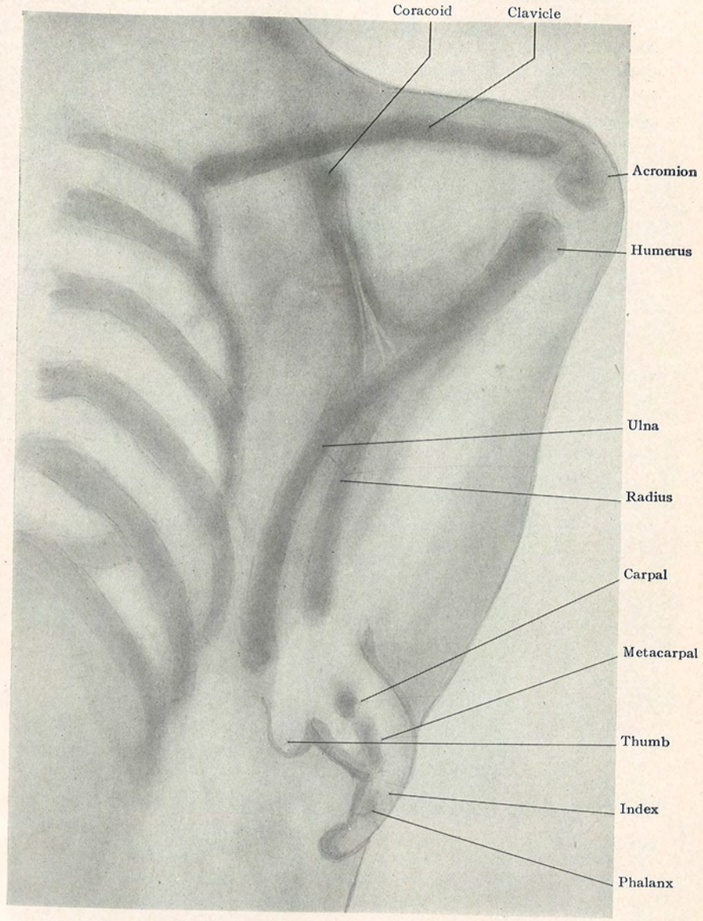

Rudimentary left upper extremity (perobrachium).

Fig. 3.

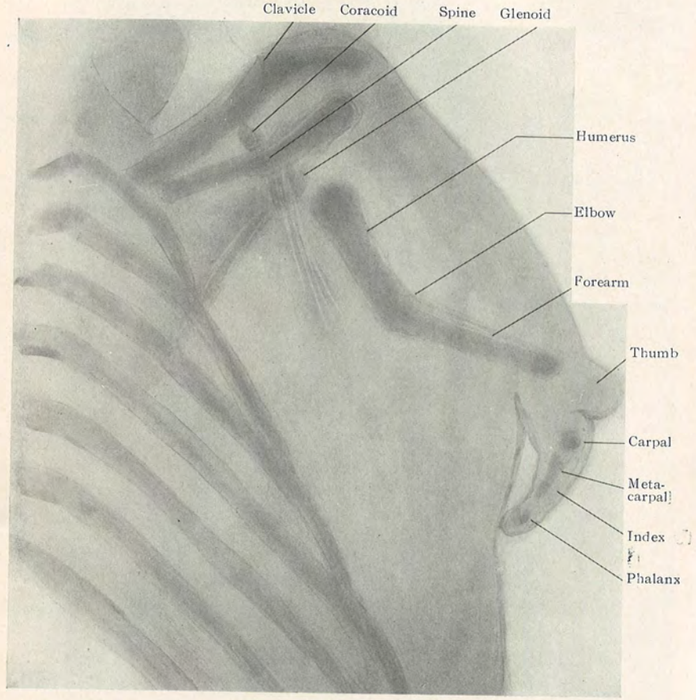

Skiagram of left upper extremity taken from behind and mesially forward and laterally.

through the hinge, as it were, is a straight cystoscope through which the stone is seen while grasping it with the expanded tip. One of the two stones removed by the use of this instrument was really larger than is applicable to this method and therefore had to be crushed before it could be removed.

Dr. James P. Hutchinson said apropos of spinal anæsthesia, that some years ago Dr. Le Conte and he were abroad together, and saw Dr. Tuffier use his spinal anæsthesia. After returning home they tried it regularly in the first fifty or more cases of operation below the umbilicus; it was uniformly successful, but the large majority of patients objected to the mental depression and, in many cases, the headaches that followed its use. They then discontinued its use, but he had recently taken it up entirely in prostatic and bladder cases if the patients would allow it.

It has an advantage which Dr. Carmany did not mention, and that is that there is absolute and complete relaxation of the patient. In a bladder case, using ether, one is apt at times during the operation to get rigidity of the abdominal wall, which never occurs in spinal anæsthesia. Spinal anæsthesia also has a great advantage in that in elderly individuals the patient can be gotten out of bed in four or five hours after the operation, after the effect of the paralysis of the lower limbs has subsided, while with ether they are apt to have nausea and vomiting and be upset for a day or more, with a much greater probability of subsequent pneumonia.

Dr. Astley P. C. Ashhurst referred to a recent paper by Dr. Bevan, of Chicago, in which he unqualifiedly condemns spinal anæsthesia. There is no doubt whatever that there are a great many cases where local anæsthesia will do as well. It will not do to use local anæsthesia in removing an enlarged prostate, but it can be used in doing suprapubic cystotomy and even in removing a stone from the bladder. If a surgeon has a little patience and a light hand, and keeps the operating room quiet, he can do many operations under local anæsthesia without resorting to the more dangerous spinal form.

Dr. Charles F. Nassau believed with Dr. Ashhurst that if simpler means were tried the same results could be attained without treading on such dangerous ground in many cases. If one has persevered in obtaining a more or less extensive experience with local anæsthesia, infiltration anæsthesia, there are very few operations within reason to which the method cannot be applied. Hernias, bowel resections, exploratory sections, amputations of the arm and thigh can be perfectly well done under

local infiltration and nerve blocking. There is no objection to combining anæsthetics, for instance, in operating for a tightly strangulated femoral hernia, which is one of the more difficult types under local infiltration because it is a little hard sometimes to reduce the constriction without causing the patient some pain. In such a case the patient can be given a few breaths of nitrous oxide. One can benumb the patient thoroughly with morphine before beginning, and personally he would feel that while operation should never be refused if strongly indicated in the aged, yet he would go a long way before he would use spinal anæsthesia, the use of which may possibly result in later trouble. He knew of two patients who, he had been told, are wrecks from spinal anæsthesia used for the purpose of operating on hemorrhoids.

Dr. Robert G. Le Conte said that he had had very much the same experience as Dr. Hutchinson. When they were together some years ago at Tuffier's clinic, they were impressed by his method and technic of administering spinal anæsthesia and with the results obtained at the time of operation. Under this stimulus they tried it on a number of cases at the Pennsylvania Hospital. Their conclusions were that in old people, with bad arteries, bad kidneys, and poor circulation, this anæsthetic was the safest one that could be used. He had done a number of grave operations on patients of this type, without shock or variation in the pulse-rate. He had not had the good fortune to do major operations under infiltration anæsthesia with as little disturbance to the nervous system and to the circulation as under spinal anæsthesia. He had, therefore, become a firm believer in, and a strong advocate of, spinal anæsthesia in this limited group of cases.

Dr. George G. Ross thought one of the great difficulties with regard to stovaine is that there is no standardization of the dose with regard to the weight or age of the patient, and hence what would be an overpowering dose for one man may totally fail to anæsthetize the next one. He had seen one fatality under stovaine in a case of strangulated hernia; in this case he thought a local anæsthetic would have been preferable. The patient died promptly after the stovaine was thrown into the membranes around the cord. He had seen a number of cases where active and violent convulsions resulted from the combination of strychnine and stovaine. It took considerable time and prolonged artificial respiration to tide the patients over the immediate effects.

INDICATIONS FOR AND AGAINST THE OPERATIVE TREATMENT OF SIMPLE FRACTURES.

BY JOHN H. GIBBON, M.D.,

OF PHILADELPHIA,

Professor of Surgery in Jefferson Medical College; Surgeon to the Pennsylvania Hospital.

What I have to say on this important subject will probably cause my readers to place me among those who oppose the operative treatment of simple fractures; and although I should prefer this to being classed with those who recommend operation in practically every case, yet a careful consideration of what is said I believe will show that I belong in neither class. There has been so much written on the open treatment of simple fractures, and the technic has been so much improved lately, that I am afraid we have become too sanguine in regard to our results and too radical in both our teaching and practice. It is important to bear in mind that what follows has to deal only with simple fractures.

The first desideratum in the treatment of a fracture is the restoration of function, and the first step in accomplishing this objective is complete reduction and retention of fragments. Although improper reduction is one of the chief causes of loss of function, injury of the surrounding soft parts and the resulting adhesion of muscles and tendons is just as potent a factor, and when the open treatment is employed there must be more or less injury and adhesion of these structures, which will be in proportion to the mechanical and technical skill of the operator and the perfection of his asepsis. It is extremely important to bear these facts in mind before undertaking the open treatment of a simple fracture.

There are, of course, certain indications for the open treatment which we all recognize and follow, unless they are outweighed by equally positive contraindications, which will be considered later. In the first place, the situation of the bone or the type of the fracture may be a sufficient indication

for operation; this is the case in fractures of the patella, in many fractures near a joint, in an epiphyseal separation which cannot be perfectly reduced, in some comminuted fractures, in those where a muscle or tendon or other tissue is interposed between the fragments, where a nerve-trunk has been caught under one of the fragments, and in all fractures where a fair reduction has not been obtained *after the exhaustion of all rational non-operative means.* Emphasis is laid on this last condition, especially with students and those who look too lightly upon the risks of operative treatment. I say this because it is the beginner or the occasional operator who is often willing to run risks which the most experienced operator never runs, and neglect precautions which an experienced operator always takes.

One of the most valuable lessons which experience teaches is the estimation of risks and the value of precaution. It is the tyro whose boldness causes him to operate where an experienced surgeon recognizes danger, and it is the tyro who considers the refinements of an aseptic technic unnecessary or even looks upon them as fads. It is this type of surgeon who will operate on a fracture without having exhausted the less dangerous non-operative means of reduction, and one reason why he does so is because he sees many worse cases operated on successfully by others. It may be said that this applies to the whole field of surgery, and so it does, but I hold that it applies particularly to the open treatment of fractures, where success depends so largely on the operator's mechanical skill and his practice of an aseptic technic.

A conscientious practice of the rule of exhausting the non-operative means of reduction will obviate the necessity of operation in many so-called irreducible fractures. To prove this statement, one has but to consider a few types of fracture for which operation is frequently employed. First, let us take fracture of the surgical neck of the humerus with abduction and external rotation of the upper fragment, a fracture which by the older methods of reduction and retention gives but a limited restoration of function and a very

indifferent restoration of contour. A mistake commonly made here is that of trying to control the short upper fragment, which is practically uncontrollable, instead of placing the lower fragment or shaft in alignment with the displaced and uncontrollable upper fragment. In many of these cases the simple abduction of the arm with moderate traction even without an anæsthetic will result in an excellent reduction, which can be maintained by dressing the part in abduction on a triangular splint placed against the chest wall, the inner aspect of the arm, and the flexor aspect of the forearm; or by keeping up extension in the abducted position by placing the patient in bed and applying a Buck extension apparatus to the arm. Too frequent an error in these cases is that of fixing the arm against the chest wall and applying a bandage, usually a Velpeau, which makes upward pressure on the flexed elbow and downward pressure on the shoulder; in other words, a dressing which tends to crowd the fragments into angulation or to retain them in this malposition. Traction applied to the elbow with the arm against the chest wall also often corrects the deformity when operation may seem to be necessary. In a number of these cases where there was extremely bad position of the fragments, we have obtained a fair reduction and excellent restoration of function by keeping the patient in bed with an extension on the arm in the abducted position for a week or ten days, and then dressing the part on a triangular splint.

Transverse fractures of the humerus with overlapping can nearly always be reduced by continuous traction applied to the flexed elbow, with fixation of the arm to the chest wall while the patient is in the upright position, or, what is better, by keeping the patient in bed and applying extension by means of a Buck apparatus. Counter-extension should be made, of course, by elevating the foot of the bed and fixing the upper arm to the head of the bed by means of a pad and strap passed under the axilla. In the oblique and spiral fractures of the humeral shaft, the type of fracture which most frequently requires operative fixation, the large majority can be

reduced by the method just described. If it fails, probably due to the interposition of the soft parts, then operation is plainly indicated. The necessity for operation in supracondyloid and fractures of the condyles can often be obviated by the proper employment of the Jones position, which gives excellent functional results, although not such perfect contour as can be obtained sometimes by other forms of dressing and by operation.

Many fractures of the olecranon require operation because of the wide separation of the fragments and the extensive laceration of the ligaments. But here the simplest means possible should be employed; catgut suture of the ligamentous tissue, as in fracture of the patella, may be sufficient, and a plate in this position is seldom excusable.

In certain fractures of the shaft of the radius and of both bones of the forearm, we encounter some of our greatest difficulties, and may be driven to operation or to accept some deformity with considerable loss of function. In four or five such cases within the past twelve months I have been surprised and gratified to find what can be accomplished by continuous traction extending over a period of from two to ten days. One of the cases at the Jefferson Hospital, X-ray plates of which are shown, was most obstinate (Figs. 1 and 2). My assistant, Dr. Despard, twice tried under ether anæsthesia to reduce this fracture, but the overlapping radial fragments could not be put into line. He then applied a Buck extension apparatus below the fracture, fixed the upper arm to the head of the bed, and elevated the foot of the bed. This treatment, kept up for three days, had little apparent effect on the deformity, and the boy was then anæsthetized with the understanding that I would operate if failure again accompanied efforts at reduction. The treatment had done so much to overcome and stretch the muscles that without much effort reduction was accomplished, and the boy, now eight months after the injury, is playing on a football team, has perfect function, and it is impossible to tell by examining the arms which was the seat of fracture. In another case of

Fig. 1.

Fracture of both bones. Radius unreduced after two attempts under anæsthetic. Readily reduced after continuous traction of three days.

Fig. 2.

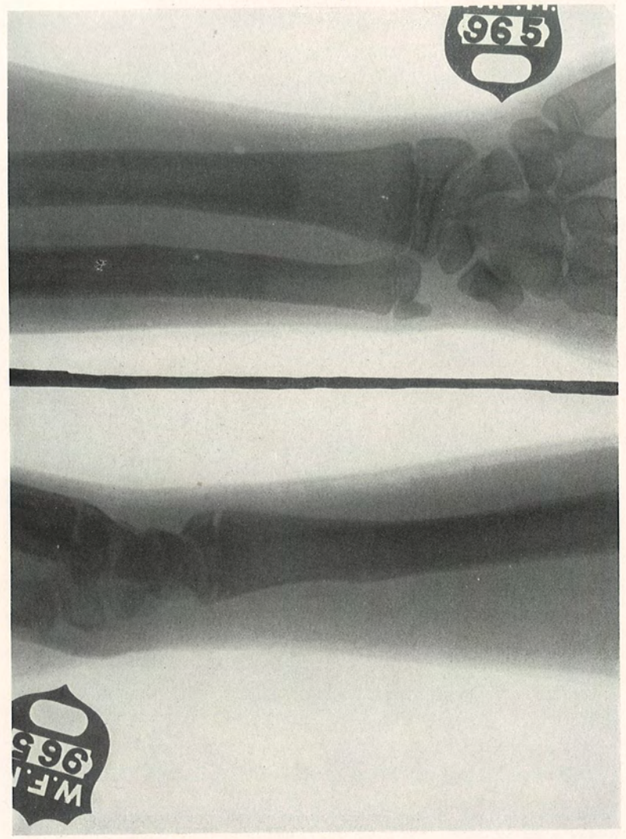

Same case as Fig. 1, eight months after injury.

Fig. 3.

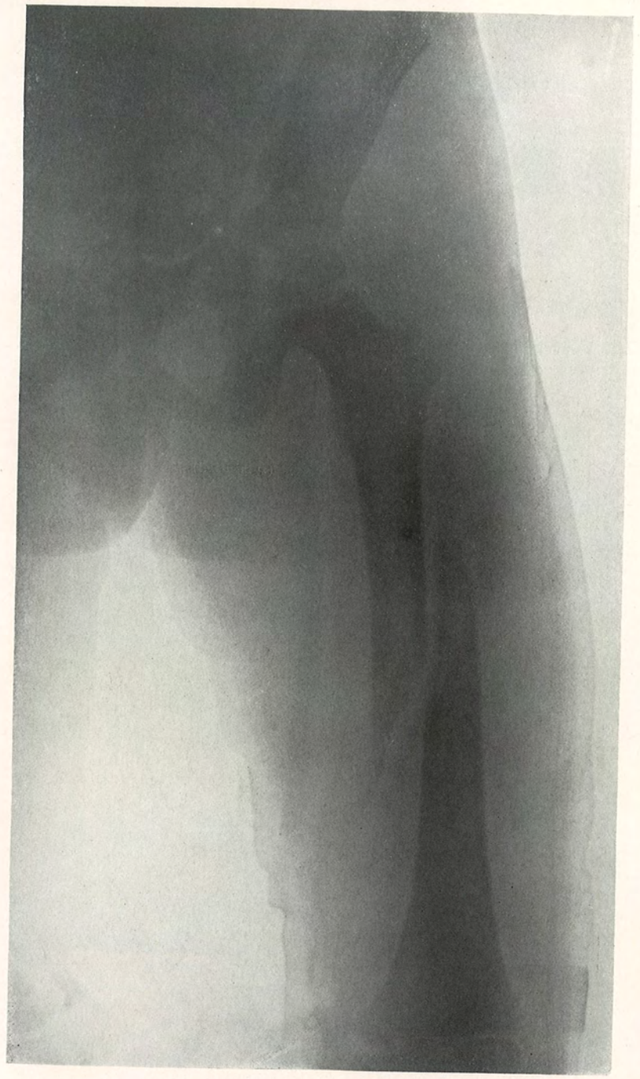

Patient admitted to Pennsylvania Hospital November 27, 1911. Discharged January 18, 1912.

Fig. 4.

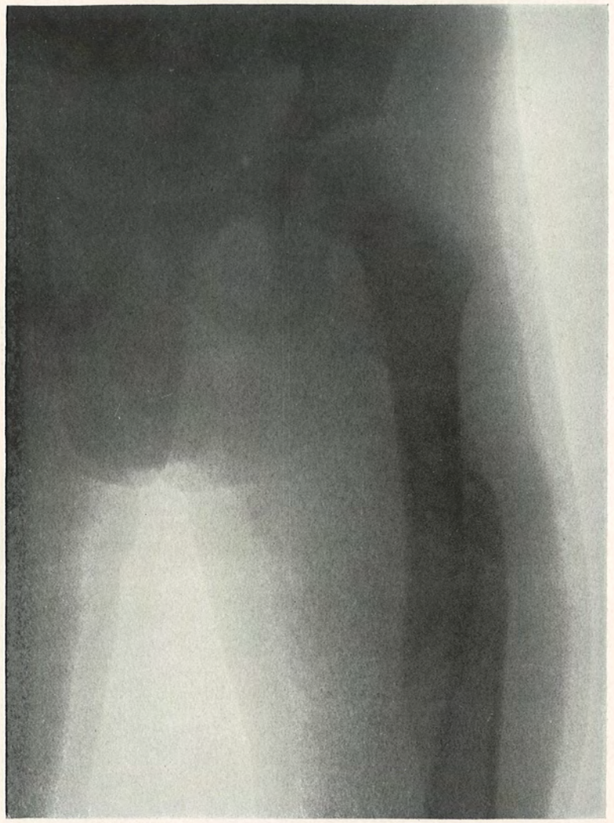

Same case as Fig. 3, taken ten weeks after injury. Excellent functional result.

Fig. 5.

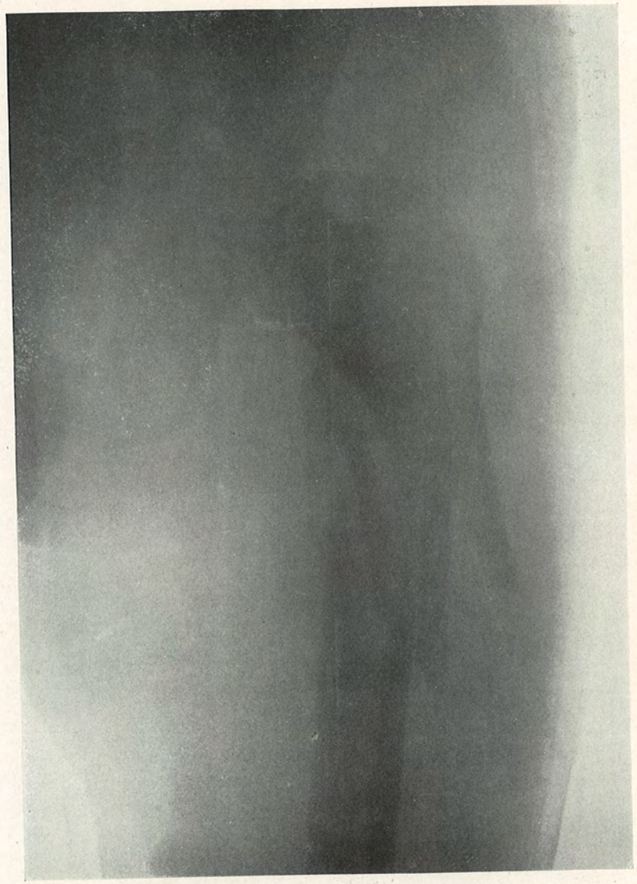

Patient admitted to Pennsylvania Hospital December 17, 1911. Discharged February 8, 1912, on crutches.

Fig. 6.

Same case as Fig. 5, taken one week before discharge. Shortening 2.5 cm. Excellent functional result.

overlapping of both bones of the forearm sent into the hospital from the out-patient department, where various efforts had been made at reduction and in which about ten days had elapsed since the injury, treatment by continuous traction for about two weeks resulted in fair reduction and good union. The ultimate restoration of function I have been unable to determine in this case. Other cases have responded much more quickly to the treatment, but these two were cases in which operation seemed inevitable, even after traction had been kept up for several days. This method of overcoming the indications for operation will not work in every case, but it should be tried faithfully before resorting to the open method, which certainly does not give its best functional results in fractures of the forearm and makes a scar which is disfiguring, especially in women. The bones here are closely surrounded by important structures which are apt to become bound down in the cicatrices; the bones are delicate and do not put up with the plates and screws so well as the more deeply situated and larger bones.

The femur is the bone upon which we most frequently have to operate, and yet as the results here cannot always be expected to be perfectly satisfactory, we should by every possible means try to obtain reduction before operating. In children, especially, persistent effort and time will do wonders in restoring the bone to approximately normal lines, and the functional results are often excellent even in the presence of considerable deformity. I have nothing particular to offer here as a means of avoiding operation in the adult, but I would call attention to the fact that in fractures of the upper third of the femur which are so troublesome because of the difficulty of controlling the upper fragment, extension in the abducted and elevated position has not been given one-half the employment it deserves. Most of us use this position in children, but many fail to realize its advantages in the adult. I have had as many as three of these cases in my ward at the Pennsylvania Hospital at one time upon which I have operated, but since I have used the extension with a little

more care and discrimination, and less according to rule, I have operated on fewer cases.

Of fractures of the patella I shall say but a word, as I believe that the indication for operation is clear if the fragments are separated, since bony union of the patella and good healing of the lateral ligaments will rarely take place without it. I have never operated on a fracture of the patella without finding the ligamentous tissue firmly adherent over one or the other of the fractured surfaces. The contraindications will be referred to later.

In fractures of the tibia of the oblique and spiral types, operation is frequently demanded, and yet I am confident that too many of these cases are submitted to operation, especially at the hands of inexperienced men, where better results could be obtained by non-operative methods. I admit that continued improvement in technic may cause me to change my opinion and practice, but I speak now rather from the point of view of a teacher of undergraduates. Greater care, personal effort, the proper use of extension, and constant watching of these cases, which we are apt to turn over to entirely inexperienced internes, will certainly keep out of our operative lists many of these cases. Here, particularly, the operator should understand that if after exposing the fragments he can reduce and maintain them in reduction by a proper dressing, he should not employ a plate or other mechanical device applied directly to the bone, as such is badly borne by the tibia on account of its thin covering. Non-union, especially where the position is bad, is a definite indication for operation, but the best operative results are obtained when the operation is done early; that is, as soon as it is evident that reduction cannot be accomplished. The open treatment of a Pott's fracture is rarely required except in old neglected cases, and here again the situation is not one suited to the use of a plate, the simpler methods of suture, nailing, etc., being better. The word "neglected" is used advisedly, because in the large majority of cases reduction can be accomplished and maintained with the expenditure of but a moderate amount of

care. A certain proportion of Pott's fractures apparently heal in good position, and then the deformity recurs after the patient begins to bear his weight upon the part, and it is this type of case which is most frequently submitted to operation. The redevelopment of the deformity can easily be avoided by following a suggestion made by Mr. Robert Jones, of Liverpool, who, when the patient begins to walk, sees that the inner portion of the heel and sole of the shoe is slightly raised; this gives the ankle an outward turn and prevents stretching of the recently healed ligaments. If every patient upon leaving our wards is instructed to have his shoes altered in this way for six months, there will be fewer cases operated upon in the future than in the past.

Just as I have tried to show that continued traction will often result in reduction where spasmodic and intermittent traction will not, Crile has suggested that with deep anæsthesia, which causes complete muscular relaxation, our attempts at reduction will be far more successful than when we simply employ the anæsthetic to the point of relief from pain and the production of unconsciousness.

The contraindications to the operative treatment may lie in the fracture itself, in the patient's general condition, or in the operator and his surroundings. The contraindications to be found in the fracture itself are few, if, after careful and intelligent effort, reduction has not been accomplished and enough deformity exists to interfere with subsequent use or to distress the patient by its appearance. Local disease and infection of neighboring structures may preclude operation. I have at the present time a fracture of both bones of the forearm, in which there is an infected wound communicating with the ulna, which is in excellent position, and I am prevented from operating on the radius, the fragments of which are overlapped, because of the infection in its neighborhood.

The indications against operation to be found in the patient's general condition are those which would make one hesitate to perform any operation of election. All these, however, must be considered carefully, and they should often make

us refrain from operation on a broken bone when we might operate for some other condition in which infection is less likely to occur, more readily overcome, or less disastrous in its results. A drain may, for instance, save another structure from infection, but we have learned that it has no place in the open treatment of simple fractures, rather inviting than preventing infection. My experience has taught me to look upon chronic alcoholism as a contraindication deserving of great attention, as is also an old syphilitic infection. The extremes of age may often constitute a contraindication, old age because the operation is more dangerous, and childhood because nature does so much in the subsequent growth of the bone to overcome the deformity resulting from fracture. The ultimate results secured in children, even where reduction was but partially obtained, were clearly shown in a series of pictures recently exhibited by Dr. Edward Martin before the Philadelphia Academy of Surgery. The accompanying picture (Fig. 3) of a spiral fracture of the femur in a five year old boy is one in which I expect to get a good functional result, even though I may fail in correcting the position. Such a fracture in an adult I should probably be obliged to subject to operation.

I also show plates of a bad fracture of the femur in an adult, when, in spite of the displacement of the fragments, an excellent functional result without apparent limp was obtained (Fig. 5).

The contraindications to be found in the operator and his surroundings I would emphasize. There are probably but few surgeons who operate upon fractures with the same impunity and confidence that they perform other surgical operations of an apparently more serious nature. If this is true, it behooves us to know the reason. First, I take it, the required mechanical skill is of a different sort from that necessary to the successful performance of most of the surgical operations, even of the most delicate character, and this is acquired only by careful study of the methods in vogue and by much experience; again, more care is necessary in this field

than in any other to avoid infection, as we are dealing with a tissue, the medullary portion of the bone, whose resistance is slight; and still further, it may be said that failure of the operation often leaves the patient in a worse state, a greater cripple, than if no operation had been done. No one realizes these facts more fully than he who does the greatest amount of work in this field, and consequently when we are inclined to imitate the accomplishments of others, we should see that we are equipped at least to some extent as they are, and by equipment I do not mean the special instruments which are, however, most essential, but rather with ability to meet and deal with difficulties and with an aseptic habit and an environment which can be relied upon. If we could feel the same assurance regarding aseptic wound healing in fractures as we do in abdominal operations, half of the difficulties of this work would be overcome, and our results would be ten times better than they are at present. We are apt to minimize our percentage of infections in any type of operation, but I ask a careful study of our own cases and the perusal of any honest report by others, and we will then find that this important question of infection takes first rank when it comes to the open treatment of fractures. In a recent article on this subject, Lund, modestly describing himself as a beginner, reports eleven cases in which he has used the Lane plate, and in four of these he was obliged to remove the plate. If a man of his experience and ability finds this work difficult, it then becomes those with less experience and ability to move in this field of surgery with judgment and precaution.

In concluding this rather discursive paper, I would say that our aim should be to overcome the indications for open treatment by a perfection of our mechanical measures, and to obtain better results when we must operate by improving our operative technic.

Dr. Richard H. Harte said that the operative treatment of fractures which has been so much before the profession of late years is largely the outcome of the imperfect treatment

accorded these patients. Again, it is largely due to lack of interest on the part of many surgeons who should know better how to treat fractures than they do; they rarely take but a passing interest in fractures until they find they are resulting badly, their attention being called to this fact by the house officer.

He was exactly in accord with Dr. Gibbon in regard to the treatment of special fractures. Take fractures of the shaft of the humerus, around the anatomical and surgical neck. Those of the anatomical neck are comparatively rare. There is very little disposition for entanglement and the question here is more of reduction and retaining the arm in position after reduction; a satisfactory result follows in the great majority of cases, particularly if the suggestions presented in this paper are followed. Again, the same thing may be said about the elbow-joint and in the shaft of the humerus. In the treatment of all fractures the question should come up with regard to the displacement: What is causing it, is it muscular, or is it a result of the bones being driven past each other by violence, or due to entanglement? In his experience, except where there is entanglement, one can usually reduce all fractures. By entanglement he meant pieces of muscle, fascia, etc., getting between the ends of the bones, and these can be eradicated only by exposing and removing the obstructing material.

There are certain bones and certain portions of bones in which entanglement is more frequent, each as in the central portion of the bones of the thigh because of the great masses of muscle surrounding them, in the forearm, and also in fractures of the tibia. In fractures of the shaft of the thigh Dr. Gibbon has very properly emphasized the importance of bringing the lower fragment to the upper fragment in fractures high up; Dr. Agnew laid stress upon this point years ago. He used a double inclined plane and made extension a little below the knee.

He was strongly of the feeling that if surgeons will carefully analyze their fractures and find exactly what the displacing element is, they will get better results than they are getting to-day. Often on taking an X-ray, when the fragments are apparently in position it is found that a great deal of displacement exists, particularly laterally; the plane of fracture is almost straight, but the bones are separated from one-half to three-quarters of an inch with tissue between; these cases should be operated upon. He did not know any class of surgery where the judgment of the surgeon

is more taxed than to say what cases should be operated upon and what should not. The reason ununited fractures occur is because a band of fascia or piece of muscle has gotten between the ends of the bones.

Another important point is the necessity of going into these cases before it is too late, not after subjecting them to extension for four, five or six weeks. The surgeon should find out as soon as possible whether he had gotten the fragments in position; then he should not wait too long, because it complicates the operation materially; the changes for repair are much better the earlier the operation.

With regard to Pott's fracture, he had seen such cases operated upon, but he did not think they should be. If treated intelligently, by carrying the foot well in a fracture box with two pieces of bandage and binding the leg around, or putting on the Dupuytren splint, one will get satisfactory results. It gives a chance for the deltoid ligament to recover itself, and a patient after a fracture of this sort should walk on the outside of the foot because the ligament will gradually give way, and in time if the foot is well carried in it will just about balance itself.

Dr. John B. Roberts said that he recalled looking a few months ago over a paper by a New York surgeon, in which were reported quite a large number of cases of fractures of the thigh bone operated upon because they had been united in malposition or because they could not be reduced. He read carefully his statements as to the previous line of treatment and in a large proportion the patients had never been subjected to efficient non-operative surgical treatment. Nearly all of them had been treated by long external wooden splints or other splints, or by an inclined plane, and not by extension with Buck's stirrup and pulley or other methods of maintaining traction. For one to operate on fracture of the shaft of the femur, because it could not be reduced, when he never had tried continuous traction with 25 or 30 pounds weight, is in his opinion an error. If he had previously seen these cases himself and treated them in a rational manner, doubtless operation would not have been considered necessary. He thought Dr. Gibbon to be entirely right in stating that the great majority of fractures can be treated by non-operative means; and that when this is not successful the failure is due to either the patient's own negligence, or to a want of mechanical sense and attention on the part of the surgeon.

It is often due to the fact that the after-treatment is conducted by young medical men or by nurses, who are not familiar with the mechanical principles involved and the anatomical displacements. Each individual case should be treated in accordance with the mechanical and anatomical problems involved. In a great majority of fractures of the humerus or the bones of the forearm and of the bones of the lower extremity, the surgeon will obtain good results without operation, if he has a mechanical turn of mind and gives intelligent and frequent supervision to the patients. It will not do, however, to leave them to doctors or nurses without experience and knowledge of non-operative methods. He discovered not long ago that fractures of the femur treated by him in a hospital had been accustomed to have a bedpan about two or three inches high put under them by the orderly while the broken limb was weighted with from 15 to perhaps 30 pounds. He only found it out by seeing the thing occur as he walked into the ward. That is the kind of thing that surgeons' indifference and negligence in fracture cases have allowed to go on in hospitals; and it perhaps accounts for the lack of good results in many cases. Dr. Gibbon is right, that attentive surgical observation will prevent many bad results.

It seems proper to lay stress on the treatment of fractures by gypsum splints. The average surgeon nowadays pays no attention to the use of plaster of Paris as a means of making a perfectly fitting splint.

The X-ray is a valuable adjuvant in diagnoses; but it is a most incorrect aid unless a surgeon supervises the taking of the picture and then uses his own fingers and clinical sense to act as a source of contrast and addition to the X-ray plate. In some hospitals the patients are taken out of bed, put on a stretcher, and taken to the X-ray laboratory by a probationer nurse or inexperienced resident. It is perfectly possible for the X-ray man to make almost any kind of a picture by changes in the line and angle of the rays. We are liable to pay too much attention to the X-ray picture and think we have a badly set fracture when the truth is that the appearances are factitious. It requires often the combined knowledge of the radiologist and the surgeon to correctly translate the shadow picture.

Dr. Gwilym G. Davis said that Dr. Gibbon's paper brings up one aspect of surgery that is suggestive, and that is the relation of the conservative to the radical, and the question of the conservative treatment of surgical affections of the extremities. When it comes to a discussion as to whether the treatment of certain cases shall be conservative or radical, it devolves upon the surgeon to be qualified to decide that question. In other words, he should know what can be done by conservative means; to be qualified to treat a part conservatively he should understand conservative methods and should be willing to take the time and trouble to become familiar with and carry out such methods. The tendency in the development of surgery during recent years has been toward visceral surgery; the consequence has been to drift away from extremity surgery. Visceral surgery has developed to such a tremendous degree that it has been practically impossible for many surgeons to keep pace with the developments of surgical science in conservative fields, and we therefore see them devoting their attention almost exclusively to operative and visceral surgery, the abdomen, brain, etc., to the exclusion practically of such things as fractures and other surgery of the extremities. Still retaining their position as general surgeons to institutions, these cases of fracture, etc., fall under their care although they have not kept pace with the development of the conservative side of the art. The consequence is that they must do one of two things, either relegate the treatment of these cases to others, or undertake them themselves. Some do one thing, some another. When they undertake the treatment themselves, they are confronted with the alternative of either treating them inefficiently conservatively, or else operating upon them, and likewise inefficiently, and it has been a matter of surprise to him that Mr. Lane's work, commendable as it is along some lines, has aroused such enthusiasm. No one could admire his technic more than the speaker, and yet the choice of his cases leaves much to be desired. Exactly what course will be pursued by the surgical profession is a matter of great interest. If the general hospital surgeon is going to treat fractures in the future, he will have to begin to study fractures from a conservative stand-point, and perhaps after the furor which has recently occupied the surgical world for visceral surgery has passed, there may be a reaction, and then these cases will again receive the attention which they deserve. In the meantime, however, some institutions are finding a solution of the problem by turning such cases over to the members of the staff who are accustomed to deal with things from a more conservative and mechanical stand-point.

Dr. John H. Jopson asked whether the amount of extension applied by Dr. Gibbon relatively to the arm and forearm and thigh. In the past he had often been content with an insufficient amount of extension in the treatment of fractures of the thigh, and lately he had been in the habit of increasing the weight with less regard to the age of the patient, until satisfied with the reduction obtained. He did not know whether in doing this the ligaments of the knee-joint might be injured. The question of the strength of these ligaments must be considered both in the treatment of simple fractures by Buck's extension, and in the newer methods of reduction, for example, that employed by Dr. Lemon of Milwaukee, which he recently demonstrated in this city. In Lemon's apparatus, one in which the mechanical details have been worked out in the nicest manner, the extension which is used to effect reduction is applied to the ankle by means of a special gaiter, which is removed after the plaster cast has set. The amount of extension employed can be carried up to 150 pounds. In Martin's method the extension is applied directly from the upper end of the lower fragment. Lemon's apparatus he applied for in one case and Martin's apparatus as modified and perfected by Eliason he has used very recently, and undoubtedly if there is no danger in the application of this very great amount of force below the knee-joint there is an advantage in the use of Lemon's apparatus, because in Martin's method you have to remove the retractor before pinning or plating the fragments.

Another question in the experience of the author is shock in operating on fractures of the femur, especially in the upper portion. As everyone knows there is oftentimes serious shock in operations on the femur, and in cases where the hemorrhage is slight may it not be that the traction itself can be responsible for this shock?

In spite of the opposition manifested in some quarters to the operative treatment of fractures, one must realize that in selective cases it has come to stay, and that we will be in the future less and less satisfied with incomplete and imperfect reduction of fractures.

Dr. John H. Gibbon (in closing) said that he thought highly of Lane's plates and that there is no technic better than his, but what he had seen is a plate employed in fractures and applied to bones where it should not be used; for instance, on the

olecranon, the internal malleolus, and the patella. Lane has done the best work of any man in the treatment of fractures. His selection of cases, however, seems bad, that is, he takes cases which we would not operate on. A great many of the cases which are reported by many operators are those which the surgeon has not seen until a resident or his assistant says, "We have a bad result and I guess you will have to operate," and this after partial union has taken place and a lot of callus developed. Such a case should have been operated on just as soon as it was discovered it could not be gotten into proper position. Late operations give bad results.

As to the residents: He finds residents get enthusiastic about the same things their chiefs get enthusiastic about. If one shows a certain amount of interest in fractures and demonstrates to the resident what he can do, for instance, in fractures of the upper end of the humerus by abduction, he will be impressed and become interested, and if, on the contrary, one pays no attention to the fracture cases, he will only call attention to them when they are in bad condition for operations and beyond mechanical correction. Surgeons want to familiarize themselves with the improvements that are made in the mechanical treatment of fracture just as much as the improvements in technic. General surgeons are competent to treat fractures, but when it comes to operating on them the man who understands this should be very familiar with such work.

There is one point he wished to emphasize, and that is the matter of continuous traction. Ten pounds kept up for a week will do more than 30 pounds for half an hour. Regarding the shock in thigh fractures, he thought that the shock accompanying and following fractures of the thigh is often one to fat embolism. He had no proof at all, excepting that large amounts of fat are eliminated in fracture by the urine. The student is to-day not receiving the amount of instruction in mechanical treatment of fractures that he should and it must be made up to him during his internship by those under whom he serves.

FRACTURE-DISLOCATION OF THE SHOULDER.

Dr. William J. Taylor reported the history of a man of 50 of lax fibre and poor muscular development, who in the spring of 1910 made a misstep and in jumping forward to regain his balance placed his foot upon a small rug lying upon a hard-wood

floor. The rug slipped and threw him forward, and in his efforts to save himself from falling, he extended his left arm, his hand coming with great force against a wall. A dislocation of the shoulder resulted. As the accident happened in the country, there was some delay before he could be seen by a physician. Finally a man of large experience and a most excellent practitioner gave him ether and after a careful examination reduced the dislocation without difficulty, using his foot in the axilla. The arm was then bandaged to the side. Forty-eight hours afterwards he came into town and was seen by Dr. Taylor for the first time. Patient suffered great pain; there was marked swelling, and the bandage was so tight that blebs had formed on the forearm. Dr. Taylor could feel the head of the humerus in its broken place, but the swelling about the shoulder was so great that an accurate examination was impossible. There was an extensive ecchymosis. The swelling gradually subsided, but pain was persistent and an X-ray taken of the shoulder showed the true nature of the injury. The anatomical neck, or rather the articulating surface of the bone, had been shelled off and remained against the chest-wall beneath the pectoral muscle.

He operated by making an incision along the posterior axillary fold and dissected down past the vessels well into the axilla. The piece of bone could be easily felt through the wound, but so near to the vessels and nerves that it was impracticable to remove it by this route for fear of doing serious damage. Through the same incision he now dissected below the vessels and toward the pectoral muscle and by splitting it the piece of bone was removed. The remainder of the head of the humerus was in place in the glenoid cavity and the capsule of the joint firmly united. The joint was moved freely and a drain of iodoform gauze introduced into the cavity from which the piece of bone had been removed. Convalescence was uneventful, and the patient has a perfectly useful arm and a movable shoulder-joint.

Dr. John H. Jopson said that he saw a case almost identical with this in an old colored woman in the Polyclinic Hospital Dispensary, with an injury of the shoulder which he diagnosed at first as fracture of the anatomical neck. The tuberosities were pulled upward so that no depression was felt below the acromion. The X-rays showed the head in the axilla, and he made an anterior incision and removed it.

Dr. Charles F. Nassau said that four years ago he had an

Fig. 4.

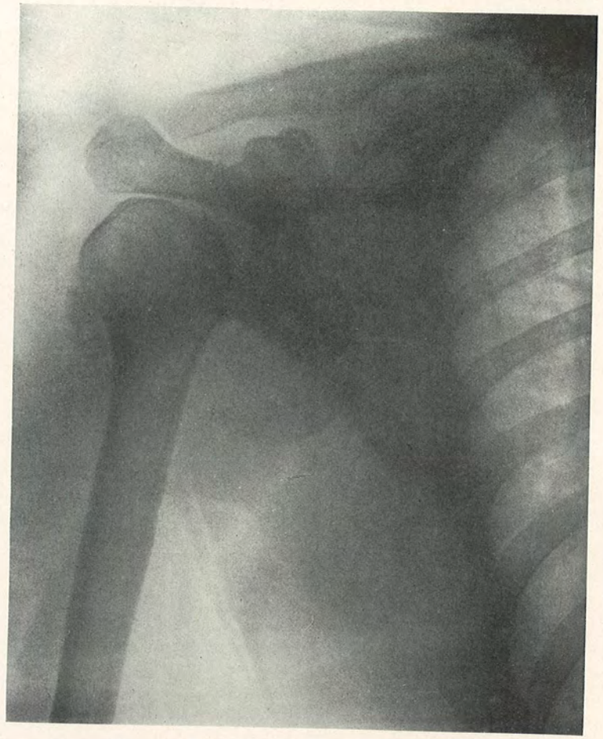

Fracture-dislocation of shoulder.

exactly similar injury occur to a patient of his. The man was very stout and flabby, extremely poor physical condition particularly due to dissipation, and he fell out of a low window to the porch, was brought to the city, and was supposed to have had a dislocation which was practically reduced, but the pain persisted. An X-ray was taken by Dr. Sweet, and it was after that that he came under his care. He feared very much to do anything with it, but the X-ray, although not good, was sufficiently so to show a thin "butter plate" torn from the head of the humerus and driven down between the head of the bone and the chest wall under the pectoral muscle. He made an incision through the anterior edge of the deltoid, smoothed the edges after removing the loose piece, and closed the wound with not more than three stitches. That man has a perfectly good arm. With persistent and long-continued massage he has obtained a good result with a freely movable joint.

Dr. Gwilym G. Davis said that when he was Dr. T. G. Morton's resident he came in contact with a case very similar to this, in which he made an incision just under the edge of the pectoralis major and withdrew the head of the articular surface as did Dr. Taylor. As a person grows older, the line of fracture recedes until it reaches through the anatomical neck, but in this case it has been a little lower and includes a little portion of the upper part of the tuberosity, and on the illustration will be seen a fragment which looks as if part of the tuberosity had been torn.

Dr. John H. Gibbon said that he had an X-ray picture taken of every fracture he treats. The time to take the picture is after the reduction. It is important to teach men that the thing they must do is to have a picture taken, and if not it is up to the patient, because so frequently patients turn up who never had a picture taken and have a bad position. Everyone taking a fracture must ask for an X-ray plate. As Dr. Harte has shown, it may sometimes mislead. He had seen two fractures that from a clinical point of view were perfectly apparent but which did not show in the X-ray plate because it was only taken in one line. With a stereopticon picture there is no excuse for a misinterpretation. We often do not need it as a diagnostic means, but rather as a confirmation of the proper reduction of the fracture; he does not consider it a criterion as to the result.

INDEX.

PAGE

ANNUAL ORATION—RECENT ADVANCES IN PULMONARY SURGERY—JOHN H. JOPSON, M.D. 1
Acetabulum, Fracture of the Floor of the 162
Actinomycosis 72
Active Immunization in Animals, Partially and Completely Thyroidectomized, Study of 75
Acute Appendicitis, Rational Treatment of 46
Abdomen, Evisceration through Stab Wound in the 92
Advances, Recent, in Pulmonary Surgery 1
Air and Ether, Experiences in Thoracic Surgery under Anæsthesia by the Intratracheal Insufflation of 112
Allied Lymph-nodes and Parathyroid Glands, Surgical Anatomy of .. 26
Amputation of Leg by the Method of Bunge 66
Anatomy, Surgical, of the Parathyroid Glands and Allied Lymph-nodes 26
Anæsthesia, Experiences in Thoracic Surgery under, by the Intratracheal Insufflation of Air and Ether 112
Anæsthesia, Spinal, Lithotomy under 174
Animals, Partially and Completely Thyroidectomized; Study of Active Immunization in 75
Appendicitis, Acute, Rational Treatment of 46
Appendix, Carcinoma of the 90
Appendix, Giant 122
Arthritis, Sacro-iliac, following Typhoid Fever 23
Arthritis, Tuberculous, of the Elbow 91
ASHHURST, ASTLEY P. C. 66, 68, 70, 75, 137, 157, 161, 167, 175
Astragalus, Excision of, for Fracture-dislocation 137

Bones, Fracture of the Sesamoid 168
Breast Carcinoma followed by Multiple Diffused Metastases 76
Bunge, Amputation of Leg by the Method of 66

Carcinoma of the Breast followed by Multiple Diffused Metastases ... 76
Carcinoma Mastitoides, Study of 80

PAGE

Carcinoma of the Appendix 90
CARMANY, HARRY S. 174
Chest, Stab Wound of 94
Child with Rudimentary Left Upper Extremity (Perobrachium) 173
Clinic, Surgical, of the Protestant Episcopal Hospital of Philadelphia. 124
Colon, Sigmoid Flexure of, Perforating Ulcer of 89
Comminuted, Compound, Fracture of the Forearm 90
Compound Comminuted Fracture of the Forearm 90
Congenital Elevation of the Left Scapula 68
Congenital Sacrococcygeal Tumor 97
Cord, Spinal, Laminectomy for Injury and Tumor of the 36

DA COSTA, J. CHALMERS 72
DAVIS, GWILYM G. 64, 138, 159, 161, 188, 193
DEAVER, JOHN B. 46
Diffused Multiple Metastases following Breast Carcinoma 76
Disjunction of Upper Epiphysis of Ulna 33
Dislocation of the Shoulder, Fracture 191

Elbow, Tuberculous Arthritis of the 91
Elevation, Congenital, of the Left Scapula 68
ELMER, WALTER G. 23
ELSBERG, CHARLES A. 112
Encephalocele, Frontal 96
End-to-end Suture, Excision of Urethra with 70
Epiphysis, Upper, of Ulna, Disjunction of 33
Epithelioma of the Mandible, Removal of, involving the Floor of the Mouth, the Contiguous Surface of the Tongue, and the Glands of the Digastric Triangle with Ligation of the External Carotid; Results after 100
Ether and Air; Experiences in Thoracic Surgery under Anæsthesia by the Intratracheal Insufflation of 112
Evisceration through Stab Wound in the Abdomen 92
Excision of the Astragalus for Fracture-dislocation 137
Excision of Urethra, with End-to-end Suture 70
Experiences in Thoracic Surgery under Anæsthesia by the Intratracheal Insufflation of Air and Ether 112
Extremities, Lacerated and Incised Wounds of, Treatment of 102
Extremity, Rudimentary Left Upper (Perobrachium), Child with ... 173

PAGE

Fever, Typhoid, followed by Sacro-iliac Arthritis 23
Flexure of the Colon, Perforating Ulcer of the Sigmoid 89
Floor of the Acetabulum, Fracture of 162
Forearm, Compound Comminuted Fracture of the 90
Fracture, Compound Comminuted, of the Forearm 137
Fracture-dislocation, Excision of Astragalus for 137
Fracture-dislocation of the Shoulder 191
Fracture of the Floor of the Acetabulum 162
Fracture of the Sesamoid Bones 168
Fracture, Sprain-, Study of 140
Fractures, Simple, Indications for and against the Operative Treatment of 177
FRAZIER, CHARLES H. 74, 122, 124

Gastric Ulcer, Perforating; Posterior Gastrojejunostomy Done Two Years after Operation for 91
Gastrojejunostomy, Posterior, Done Two Years after Operation for Perforating Gastric Ulcer 91
Giant Appendix 122
GIBBON, JOHN H. 31, 60, 63, 177, 193
GINSBURG, NATE 26
Glands, Parathyroid, and Allied Lymph-nodes, Surgical Anatomy of .. 26

HARTE, RICHARD 185
Hernia, Inguinal, Paraffin Injection as a Cure for 99
HEWSON, ADDINELL 75, 76
HUTCHINSON, JAMES P. 175

Immunization, Active, in Animals, Partially and Completely Thyroidectomized, Study of 75
Incised and Lacerated Wounds of the Extremities, Treatment of 102
Indications for and against the Operative Treatment of Simple Fractures 177
Inguinal Hernia, Paraffin Injection as a Cure for 99
Injection of Paraffin as a Cure for Inguinal Hernia 99
Injury and Tumor of the Spinal Cord, Laminectomy for 36
Intratracheal Insufflation of Air and Ether; Experiences in Thoracic Surgery under Anæsthesia by the 112
IVY, ROBERT H. 75, 100

PAGE

JOPSON, JOHN H. 1, 62, 92, 98, 122, 159, 192

KEEN, W. W. 121
KELLY, JAMES A. 102

Lacerated and Incised Wounds of Extremities, Treatment of..... 102
Laminectomy for Injury and Tumor of the Spinal Cord..... 36
LE CONTE, ROBERT G. 176
Left Scapula, Congenital Elevation of..... 68
Left Upper Extremity, Rudimentary (Perobrachium), Child with... 173
Leg, Amputation of, by the Method of Bunge..... 66
Lip, Lower, Plastic Restoration of..... 75
Lithotomy under Spinal Anæsthesia..... 174
Lower Lip, Plastic Restoration of..... 75
Lymph-nodes, Allied, and Parathyroid Glands, Surgical Anatomy of. 26

Mandible, Removal of an Epithelioma of the, Involving the Floor of the Mouth, the Contiguous Surface of the Tongue, and the Glands of the Digastric Triangle with Ligation of the External Carotid; Results after 100
MANGES, WILLIS F. 160
MARTIN, EDWARD B. 62
Mastitoides, Carcinoma, Study of..... 80
Metastases, Multiple Diffused, following Breast Carcinoma..... 76
Method of Bunge, Amputation of Leg by the..... 66
MILLER, MORRIS BOOTH 91, 92, 94, 96, 161
MÜLLER, GEORGE P. 36, 64, 138, 168
Multiple Diffused Metastases following Breast Carcinoma..... 76

NASSAU, CHARLES F. 175

Operative Treatment of Simple Fractures, Indications for and against 177
Osteotomy of Radius 72

PANCOAST, HENRY K. 162
Paraffin Injection as a Cure for Inguinal Hernia..... 99
Parathyroid Glands and Allied Lymph-nodes, Surgical Anatomy of.. 26

PAGE

Perforating Gastric Ulcer, Posterior Gastrojejunostomy Done Two Years after Operation for..... 91
Perforating Ulcer of the Sigmoid Flexure of the Colon..... 89
Perobrachium (Rudimentary Left Upper Extremity), Child with... 173
Plastic Restoration of Lower Lip..... 75
Posterior Gastrojejunostomy Done Two Years after Operation for Perforating Gastric Ulcer 91
Protestant Episcopal Hospital of Philadelphia, Surgical Clinic of.... 124
Pulmonary Surgery, Recent Advances in..... 1

Radius, Osteotomy of 72
Rational Treatment of Acute Appendicitis..... 46
Recent Advances in Pulmonary Surgery 1
Removal of an Epithelioma of the Mandible, involving the Floor of the Mouth, the Contiguous Surface of the Tongue, and the Glands of the Digastric Triangle with Ligation of the External Carotis; Results after 100
Removal of the Ureter with a Tuberculous Kidney..... 27
Results after Removal of an Epithelioma of the Mandible, involving the Floor of the Mouth, the Contiguous Surface of the Tongue, and the Glands of the Digastric Triangle with Ligation of the External Carotid 100
ROBERTS, JOHN B. 187
ROSS, GEORGE G. 30, 63, 89, 90, 91, 92, 140, 157, 160, 176
Rudimentary Left Upper Extremity (Perobrachium), Child with.... 173

Sacrococcygeal Congenital Tumor..... 97
Sacro-iliac Arthritis following Typhoid Fever..... 23
Scapula, Left, Congenital Elevation of..... 68
SCHUMANN, EDWARD A. 80
Sesamoid Bones, Fracture of 168
SHOBER, JOHN B. 29
SHOEMAKER, GEORGE ERETY 27
Shoulder, Fracture-dislocation of the..... 191
SKILLERN, PENN G. 33, 162, 173
Sigmoid Flexure of the Colon, Perforating Ulcer of..... 89
Simple Fractures, Indications for and against the Operative Treatment of 177
Spinal Anæsthesia, Lithotomy under..... 174

PAGE

Spinal Cord, Laminectomy for Injury and Tumor of the..... 36
Sprain-fracture, Study of 140
Stab Wound of the Chest..... 94
Stab Wound in Abdomen, Evisceration through..... 92
STEWART, LEVER F. 140
Study of Active Immunization in Animals, Partially and Completely Thyroidectomized 75
Study of Carcinoma Mastitoides 80
Study of Sprain-fractures 140
Surgery, Pulmonary, Recent Advances in..... 1
Surgery, Thoracic, Experiences in, under Anæsthesia by the Intratracheal Insufflation of Air and Ether 112
Surgical Anatomy of the Parathyroid Glands and Allied Lymph-nodes 26
Surgical Clinic of the Protestant Episcopal Hospital of Philadelphia. 124
Suture, End-to-end, Excision of Urethra with..... 70

TAYLOR, WILLIAM J. 98, 191
THOMAS, B. A. 75, 174
THOMAS, T. TURNER 139, 158
Thoracic Surgery under Anæsthesia by the Intratracheal Insufflation of Air and Ether; Experiences in 112
Thyroidectomized, Study of Active Immunization in Animals, Partially and Completely 75
Treatment, Rational, of Acute Appendicitis..... 46
Treatment, Operative, of Simple Fractures, Indications for and against 177
Treatment of Lacerated and Incised Wounds of the Extremities..... 102
Tuberculous Arthritis of the Elbow..... 91
Tuberculous Kidney, Removal of the Ureter with a..... 27
Tumor, Congenital, Sacrococcygeal 97
Tumor of the Spinal Cord, Laminectomy for Injury and..... 36
Typhoid Fever, Sacro-iliac Arthritis following..... 23

Ulcer, Perforating Gastric, Posterior Gastrojejunostomy Done Two Years after Operation for 91
Ulcer, Perforating, of the Sigmoid Flexure of the Colon..... 89
Ulna, Disjunction of the Upper Epiphysis of..... 33
Upper Epiphysis of Ulna, Disjunction of..... 33

PAGE

Upper Extremity, Rudimentary Left (Perobrachium), Child with... 173
Ureter, Removal of, with a Tuberculous Kidney..... 27
Urethra, Excision of, with End-to-end Suture..... 70

WHARTON, HENRY R. 91
WOODS, ALFRED C. 97, 99
Wound, Stab, of the Chest..... 94
Wound, Stab, of the Abdomen, Evisceration through..... 92

YOUNG, JAMES K. 74