much more common than are generally supposed, this point he had brought out in the paper; namely, that in cases of extensive injury to the brain where the sinuses were injured, the symptoms of sinus injury were often masked by the grave lesions of the brain. He questioned Treves' statistics as to the frequency of injury to the middle meningeal and great venous sinuses. Treves, of course, makes this statement as regards extradural hæmorrhage. Phelps refers to a great many deaths from pial hæmorrhage. The hæmorrhage in cases of rupture of the pial veins is usually subdural hæmorrhage. Phelps records in 300 cases of traumatism of the brain a great many fatal cases resulting from injury to pial vessels; so that this variety of hæmorrhage is a cause of death, combined with hæmorrhage from the venous sinuses.

TRANSACTIONS OF THE PHILADELPHIA ACADEMY OF SURGERY.

Stated Meeting, February 4, 1901.

The President, De Forest Willard, M.D., in the Chair.

THE BEST INCISION IN OPERATIONS FOR MAMMARY CARCINOMA.

By WILLIAM L. RODMAN, M.D.,

PROFESSOR OF THE PRINCIPLES AND PRACTICE OF SURGERY AND CLINICAL SURGERY IN THE WOMAN'S MEDICAL COLLEGE OF PENNSYLVANIA.

The increasing frequency of carcinoma of the breast, the demonstrated hopelessness of partial and incomplete operations for its relief, together with the more than reasonable hope of cure following a timely and rightly done operation, warrant me in asking the attention of the Academy to a paper briefly considering the relative merits of well-known operative procedures.

Before doing so, however, we should recall the anatomy of the gland, pathology of the disease, and its natural tendency to disseminate by means of the lymphatics. The lymphatic vessels are far more numerous and complicated than Sappey and former anatomists had led us to suppose; for, instead of all such vessels converging to the nipple and thence passing by main channels beneath the skin to the axillary nodes, we now appreciate, from the teachings of Mascagni, Langhans, Küster, Stiles, and Heidenhain, based upon injections, that there are several other important, if not as much frequented, channels. There are two superficial sets of lymph-vessels; in addition to the axillary set, so dwelt upon by Sappey, a second one drains the sternal half of the gland passing through the

second and fourth intercostal spaces, to discharge their contents into the lymphatic glands of the anterior mediastinum.

There are also three deep sets of lymphatic vessels. One, beginning in the mucous membrane of the milk-ducts and acini, drains the deeper portions of the axillary half of the gland, joining the superficial set in the axilla, and forming with it a network which surrounds the axillary vein, almost or quite up to the clavicle.

A second set drains the deeper portions of the sternal half of the gland, perforates the second and fourth intercostal spaces, following the course of the internal mammary artery, to finally empty, together with the superficial set, into the mediastinal glands. On the right side they intermingle with the lymphatics of the liver. Hence it is easy to explain the frequent and early implication of the mediastinal glands, which cause bulging of the bone or "sternal symptom" of Snow, in cancers originating in the sternal half of the gland.

A third deep set drains the middle of the base of the gland and retromammary tissues, then perforating the intercostal muscles and spaces to follow the course of the intercostal arteries to the spine; thereby affording a ready explanation of those cases ultimately complicated with spinal symptoms, even paraplegia.

It will therefore be at once appreciated how necessary it is to have in mind more than one avenue of possible infection.

This arrangement of the superficial and deep lymphatics also offers a ready explanation of the clinical fact, that carcinomata affecting the inner half or sternal quadrants of the gland are more quickly fatal than those occupying the outer half or axillary quadrants. I have rarely seen cancer of the inner half of the gland that was not quickly fatal, and have gotten to look upon the location of the growth and the age of the patient as the two most reliable *early* prognostic signs. While carcinoma is comparatively infrequent under thirty, when it does occur it is almost certain to run an unusually rapid course. I have operated upon only three cases of mam-

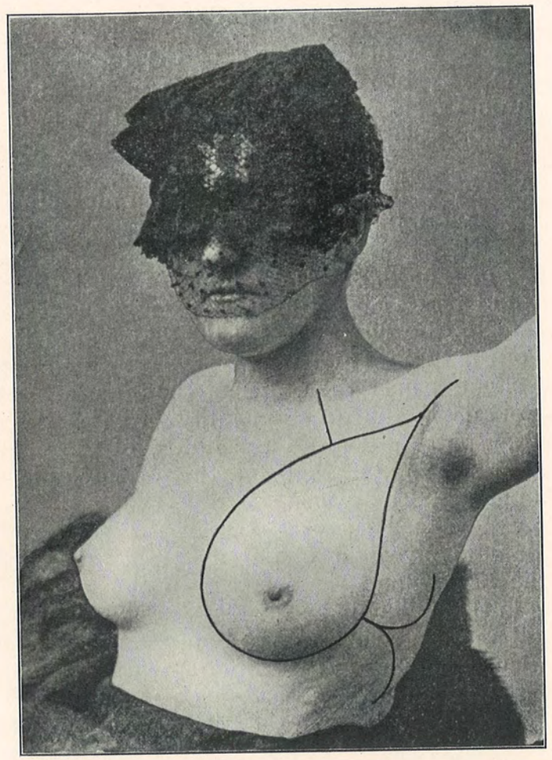

Fig. 1.—Warren's incisions in removal of breast for cancer. ("International Text-Book of Surgery.")

mary cancer in women under thirty, aged twenty-five, twenty-seven, and twenty-eight respectively. One died within six months after operation in spite of a seemingly complete Halsted procedure. Another died eleven months after operation, notwithstanding the fact that everything but her age indicated that a radical cure would be effected. The tumor was small, perfectly movable, and there was not extensive axillary infection; in truth, no enlargement of the glands could be made out before the axilla was opened. The case was such a border-line one, so far as diagnosis was concerned, that a pathologist was asked to be present at the operation, so that the tumor could be examined immediately and reported upon. It is not my practice to sacrifice the entire gland in young women with tumors demonstrably benign; and in cases of doubtful diagnosis, from a clinical stand-point, a competent pathologist is asked to be present and ready to make frozen sections and then give a reliable report, which can usually be done in less than fifteen minutes. I have taken this precaution for many years, and have been kept from making mistakes in at least two instances. An incision into the tumor with macroscopic examination is insufficient, and, now that we have a better plan, should not be relied upon. In a few minutes Professor McFarland reported back "cancer, undoubtedly." The entire gland with its covering of skin, and the fascia and superficial fibres of the pectoralis major, were removed, along with all axillary glands and fat. In September, 1898, ten months after the operation, she returned to Philadelphia to consult me, and I was amazed to find extensive carcinosis of the skin of the chest, and marked evidences of metastases in the lungs. She died about a month later. The third case is at present under my care, and, from the progress of the disease up to date, will probably end as the other two have done.

The cases referred to came close together in my experience,—one having been operated in December, 1897; another, in May, 1898, and the third in November, 1899. Until these cases were encountered, I had never seen carcinoma of the

breast prior to thirty, and therefore could not appreciate, so fully as I now do, that the malignity of the disease is directly proportional to the *youth* of the patient. Per contra, in the very old it frequently runs a relatively benign course.

Not only is the entire gland to be sacrificed in every case, but all outlying supernumerary glandular elements should be removed at the same time. Moreover, the *manner* in which the gland is detached is of importance, as it should be done from *above* downward instead of from *below* upward, the plan followed by a majority of operators. It is quite inconsistent to remove the gland from below upward and clear the axilla from above downward; yet this is usually advised by authors, and carried out by operators, on account of the supposed advantage of not having blood obscure the field as the lower part of the incision is made. The advantage of such a course is so slight, if it exists at all, that it is as nothing against the weighty reasons, anatomic and surgical, for the opposite one. The breast should be detached near the sternum first, and the dissection made towards the axilla, where a narrow tail of tissue will be cut last. The incision must include all the skin covering the tumor, and should embrace that over the entire gland. I will state it as my conviction that more recurrences are due to leaving infected skin behind than to any other one cause, and that a probability of such mistakes having been made will be furnished by a study of recurring cases. It has certainly been the case in my own practice, and I candidly admit it. I have also frequently seen other surgeons do a very complete operation so far as the axillary dissection and other steps were concerned, and yet have felt at the time that an abiding result was made next to impossible on account of the primary incision, which included between its lips only a small, elliptical piece of skin.

The mistake is always presumably due to the natural and very proper desire to secure immediate union on the one hand, and to avoid undue scarring of the patient on the other. There is, I believe, a prejudice against skin-grafting as a supplemental step in this operation which is shared by operator and patient;

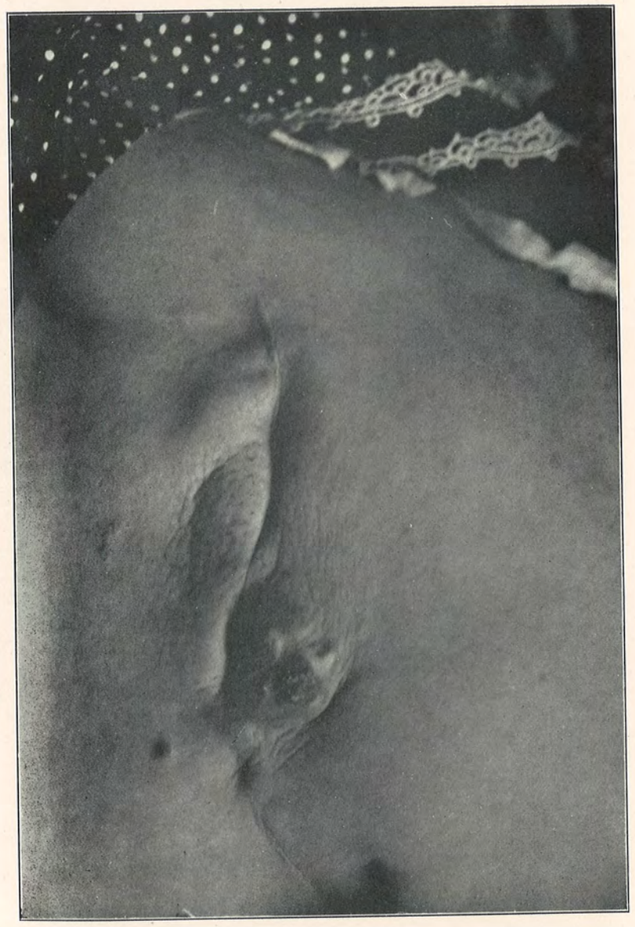

Fig. 2.—Showing Case I as it appeared before second operation.

the first, because it prolongs the operation and not infrequently fails to accomplish its intended purpose; the second, because it leaves unsightly scars. My private patients have usually objected to it. Women are very prone at best to delay seeking surgical aid for a mammary growth on account of the mutilation and asymmetry following excision. This very common operation—and I believe now becoming a life-saving as well as palliative procedure—should be stripped of every avoidable objection, so that women will be encouraged to such and submit to earlier operation: therein lies our only chance for real advance, as operative measures for breast cancer have been seemingly carried to the very Ultima Thule of surgical limits.

Remembering always the tendency to early contamination of the axillary glands, the primary incision must in every case be carried into the axilla, and this space, from base to apex, be thoroughly cleared of glands and fat, leaving, when the work is completed, vessels and nerves to stand out as plainly as in a dead-room dissection. The space of Mohrenheim, as well as the interval between the two pectoral muscles, must have careful attention in operations not contemplating their removal. It is very important to remove breast, lymphatic glands, and intervening lymph vessels in one mass, thereby avoiding cutting across lymph-bearing channels and liberating cancer cells to probably infect neighboring tissues and cause regional recurrences.

The researches of Heidenhain and Volkmann demonstrated that the fascia covering the great pectoral muscle, along with its most superficial fibres, should be removed in every case of carcinoma.

The fascia unquestionably acts as a barrier to the proliferations of the disease for a time, and in cases operated early, it is superfluous to remove the muscle. It has usually been my practice to remove both pectoral muscles only in cases of the third degree; that is to say, where the gland was adherent to the muscle beneath and immobile. There is a growing tendency with me, however, to remove the muscles in

every case, even though not visibly infected. I do it more because a free axillary dissection can be made with greater primary and secondary safety to the patient. One may reasonably question whether or not it is possible to clear the axilla of all glands and fat with the pectorals *in situ,* and the danger of hæmorrhage is probably too great for it to be attempted. Many of us have thought that we accomplished more than was done, and a comparison between two cases, operated by Halsted's and Kocher's methods, respectively, will undeceive any one. The latter operator and surgical genius practised and advised the removal of the pectoral muscles—major and minor,—if it seemed to be necessary, before the publication of Halsted's method. He did it exceptionally and not usually, however. In the Kocher operation, retractors are used to hold the muscles out of the way and assist in uncovering the axillary vessels and nerves.

There are, as we know, several excellent methods of removing the mammary gland, and each has its champions. The best of them are more or less imitations of Halsted's method,—the first complete operation as we now understand the term. The principles he taught were at once recognized and accepted in the main by surgeons everywhere. Many may, and do honestly, differ with him as to the necessity of this and that detail in his technic; but all agree that nothing short of a large wound and a thorough axillary dissection avails aught.

What are the essential features of the best incision in breast operations? I would answer by saying, in the first place, that it should be large enough to include all infected skin. Second, expose the pectoral muscles from origin to insertion. Third, it should uncover the axillary blood-vessels and nerves. Fourth, it should have regard for the future usefulness of the arm. Fifth, it should, if possible, admit of primary union without the necessity for skin-grafting. Sixth, the operation should be completed within a reasonable time. We may say in all fairness that most of the above conditions may be fulfilled equally by Halsted's, Kocher's, Shrady's, Senn's,

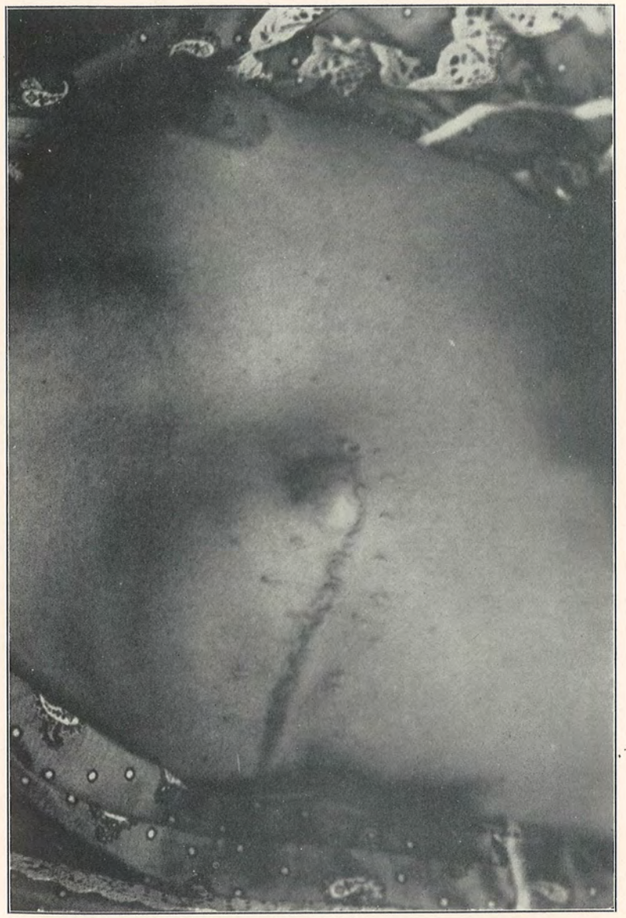

Fig. 3.—Before second operation in Case II.

Warren's, and some other methods; but I am impressed with the belief that we owe to Professor Warren a most valuable step in advance, inasmuch as we can by his method secure primary union even after the removal of the largest tumors, without the aid of skin-grafting. Of course primary union is desirable, and should be had with, if it cannot be had without, skin-grafting. Still, it is certainly better, in my judgment, to be able to bring the lips of the wound together if it can be done without too much tension, rather than close the gap by skin-grafting. Warren's device is simple, and in the three cases in which I have tried it, it was certainly satisfactory. I was able to close the largest wound I have ever made, or seen in my life, by this method slightly modified. The modification referred to consisted in making the curved incision, or what may be called the inverted Y, above as well as below the wound and undermining the flaps after the method first advised by Shrady, with the additional use of deep, relaxation sutures, which are shown in the photograph taken after the wound was closed. In each of the three cases where it was used primary union has occurred. None of them were in the hospital as long as a fortnight,—one leaving on the eleventh, one on the twelfth, and one on the thirteenth day after operation.

Another advantage that it undoubtedly has over Halsted's operation is that it takes less time, for at least thirty minutes will be occupied in cutting and placing grafts, should they be necessary. This, I submit, is an important element, more so than the sentimental one already referred to; especially is it so in elderly patients who have already been under the influence of ether from one to three hours.

The future usefulness of the arm will be as much interfered with by one operation as another. It is really surprising that none of these extensive operations are followed with as much interference with the arm as one would think. In all of my cases of Halsted's, Kocher's, and Warren's operations, the arm on the affected side has been fairly useful. Women are able to feed themselves, adjust their clothing, and even

comb their back hair, which is a crucial test, and most difficult to accomplish where there is much restriction in the latitude of motion.

Within a week I have received a letter from Dr. D. H. Keller, of Bangor, Pa., in reference to a case of his upon whom I did an extensive operation in October last for a recurring carcinoma of the left breast. In it he says, "Mrs. M. doing very nicely; can use her arm at all times; combs her hair, and does a great deal of the house work. Her health excellent; sometimes a shooting pain in her right mammary gland, but no enlargement whatever." The pain in the right breast must be neuralgia, as she has complained of it for more than a year. She called my attention to it more than once. Both muscles were removed in this case from origin to insertion, and a large amount of skin was sacrificed on account of a condition shown by the photograph here exhibited. A very large wound was made after the method of Warren,—larger than any I have ever made save the case already described; yet it united *per primam* in a woman not very robust, and past sixty-five years of age. She went to her home on the twelfth day after operation, and could have gone sooner.

DISCUSSION.

Dr. Neilson agreed with the author that the Warren incision offers a very simple solution of a difficulty which all have to encounter more or less often in closing the enormous gaps frequently left by the removal of large mammary growths. The flaps are so easily moved and brought into apposition, it is a wonder that the plan was not thought of sooner than it was.

Dr. G. G. Davis regretted that he could not state that he had always found it easy to close these wounds. As regards the procedure of Warren, he had used it on several occasions, placing the incisions, however, perhaps a trifle lower rather than extending them so far backward. In spite of the comparative ease with which the wound could be closed by means of Warren's method, it seems that Dr. Rodman had still found it desirable to add another incision to it, so that it shows that, in order for it to be efficacious, the undermining of the skin must be very extensive.

Fig. 4.—After operation.

As regards methods of operating, he did not think, with some, that the hundred odd hæmostats which are used by many in these operations were entirely useless. In fact, it was his practice to gather up all the hæmostats he possessed or could beg or borrow, and he found that he could put them all to profitable use.

The blood, of course, comes from various vessels, largely according to the methods of operating. If the surgeon goes in above, he will get the acromial thoracic artery at the upper outer corner of the wound; but the blood that comes from that region is not the only blood that troubles the operator; some of the blood comes from the anterior intercostal arteries, especially the second, third, and fourth branches of the internal mammary.

As regards the method of operating, after making his incision largely in the way that Halsted does, and raising the skin, he simply takes the handle of the scalpel, inserting it at the supraclavicular joint, between the clavicular and sternal portions of the pectoralis major muscle, and splits it clear out to the humerus; introducing the finger in that cleft, it is separated downward from the sternum, clamping the vessels on the side of the tumor and as they come from the intercostal spaces. Then, having loosened it from the sternum, it is turned outward and the pectoralis minor muscle divided. Then, as the apex of the axilla is exposed, prepare the vessels downward and outward, cut off the attachment of the insertion of the pectoralis major muscles, and then work along the subscapular vessels downward and backward to the scapula. Having detached the mass of the tumor from the side of the chest, he sweeps everything from above downward and removes it. Operating in this manner, a large number of hæmostats can be put to good service.

Dr. John B. Roberts said that he was particularly struck with the early date at which Dr. Rodman was able to discharge his patients with the wounds practically healed. He did not, as a rule, cover in the wound by a plastic operation, because it is possible usually to cover nearly the entire wound by means of strong sutures drawing the edges of the skin together. The integument should be loosened from the underlying structures by undercutting it. He had occasionally made crescentic flaps at the sides of the excision wound and used them to aid in covering the raw surface. He always raised a triangular flap in the supraclavicular region and removed the fat and lymphatic nodes before beginning the

operation proper. The entire breast and both pectoral muscles are then removed and the lymphatic nodes under the clavicle are extirpated. The fat and lymphatic nodes in the axilla are similarly removed. In making the triangular flap above the clavicle, he made the point of the triangle towards the acromion. If the point of the flap projects towards the middle line, the skin at the apex nearly always undergoes dry gangrene, because its arterial circulation is interfered with. He would be glad to know whether Dr. Rodman always removed the supraclavicular glands, and whether he excised the pectoral muscles. He looked upon these two steps in the operation as practically essential, if the surgeon is to give the patient the very best chance of non-recurrence of the malignant disease.

Dr. Rodman answered that it was not his practice to go into the neck unless the glands were visibly enlarged; and he would say further that he had never felt very optimistic about this part of the operation. If there is marked and extensive involvement of the supraclavicular glands, he questioned whether these cases were operable, since, if the supraclavicular glands were involved, the mediastinal glands would also, as a rule, be implicated.

As to the statement made by Dr. Davis, it is true that it was necessary to make this curve—the Y incision—above as well as below, and modify the operation to that extent; but it must be remembered that the case was a very unusual one,—a recurring growth with a large amount of skin infiltration. He had never seen so large a wound. In ordinary cases, it would not be necessary. In the other cases it is very easy to cover a large wound by making an inverted Y below. Dr. Warren, in a personal communication, stated that very frequently he only made one curve instead of two, and he is able to cover most of his wounds with it; two flaps will be necessary if the tumor is large and the space great.

In regard to the question of time, the colored woman left the hospital on the twelfth day. She was operated on the 19th of December last, and left on the 1st of January. She could have left earlier, if she had not had ether pneumonia. The white patient could have left on the seventh or eighth day very easily, but she had postoperative mania beginning thirty-six hours after operation, when she was found walking around the ward at midnight. It was thought, therefore, better to detain her in the hospital from

twelve to thirteen days. But she could have left on the seventh or eighth day easily, as her mental symptoms had disappeared and the sutures were all removed. This was not an extensive wound, as in the first case, and the union was firm in a week. He had had cases who had taken a railroad journey of two or three hundred miles a week after operation. He rarely failed to secure primary union, recalling but one such failure in five years. Mammary wounds unite quickly. He added as to the frequency of cancer of the breast in the colored race, there had been for many years a belief on the part of Southern surgeons that cancer of the breast was more rare in the negro, but that impression is fast passing away. It has been shown very clearly that the colored race suffers quite as frequently, if not more so, from cancer of the breast and uterus than the whites. He was convinced himself that mulattoes were more prone to cancer than the whites, as they inherit the weaknesses of both races and the strength of neither. He had encountered relatively as many cases of cancer of the breast in the colored race as he had in the white. Reference to the Louisville City Hospital records for thirty years, also the records of the City of Louisville Health Department, convinced him of this fact. There were more negroes dying from cancer of the breast and uterus in proportion to the population than whites.

TRAUMATIC THORACIC ANEURISM.

Dr. De Forest Willard read a paper with the above title, for which see page 48.

ANEURISM OF THE THORACIC AORTA OF TRAUMATIC ORIGIN; TREATMENT BY INTRODUCTION OF WIRE AND ELECTRICITY.

By DE FOREST WILLARD, M.D.,

SURGEON TO THE PRESBYTERIAN HOSPITAL.

J. S., aged twenty-three years; male; was injured in November, 1899, by a heavy box, weighing 500 or 600 pounds, which fell two feet, striking him upon the chest. He was unable to work for six weeks, but at the end of that time resumed his labor, complaining, however, of a tightness and pain in his chest, which he considered a heavy cold. He was able to work at intervals, though with difficulty, for more than six months, when the pain and pulsation of his chest, steadily increasing, disabled him. He was told at that time that his heart was injured, and he was put to bed. His cough soon became troublesome, and the pain in the chest was severe, especially at night. There was occasional expectoration of bloody mucus. Worked a little through the autumn. Admitted to the Presbyterian Hospital, Medical Ward, in charge of Drs. Musser and Stryker, December 9, 1900, being thirteen months after the injury to his chest. Married; one child; *no history of syphilis;* no palpable or visible change in arteries; only slight pulsation visible in neck; no tracheal tugging; no suprasternal pulsation along carotids, subclavians, or innominate.

Right Thorax Anterior.—Powerful distinct systolic uplifting over whole right thorax at each pulsation, most noticeable in thin area at junction of third and fourth ribs with their cartilages. Slight thrill. Right axillary vein distended. Respiratory sounds practically absent over right lung. Dulness on percussion over whole chest. Systolic blowing heard from first interspace, downward throughout entire chest, and outward to axilla.

Left Side Anterior.—Violent heaving pulsation of heart's apex diffused for three inches below the normal position. Loud systolic murmur and loud first sound over entire upper left thorax.

Posterior Right Thorax.—Decided pulsation visible and palpable over entire right chest. Long, loud systolic murmur over entire area, especially loud at base. Resonance of lung only feebly heard. Has bloody expectoration; cough; dyspnœa.

Skiagraph taken, but not satisfactory.

Patient was put at rest, with large doses of iodide of potassium and restricted diet, for five weeks. Ice-bags for pain. Dyspnœa, pain, cough,

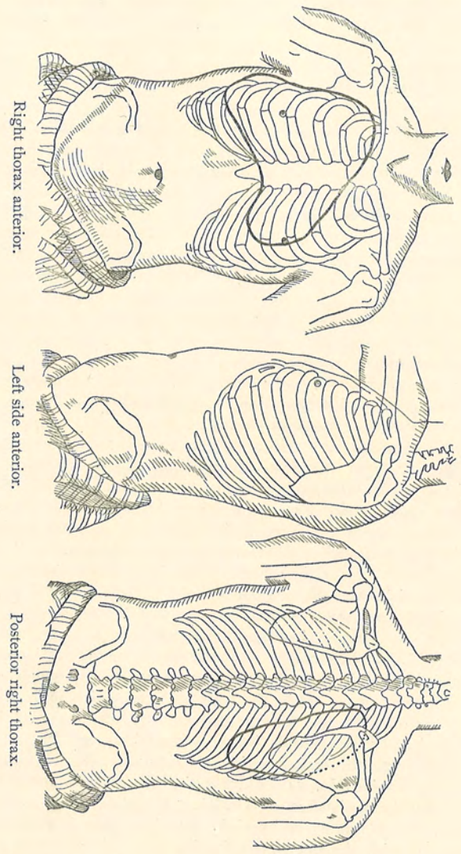

and bloody expectoration grew steadily worse, and the anterior wall became perceptibly thinner. Pain increased, depriving patient of sleep, even under large doses of morphia.

The position of the tumor, the absence of pulsation in the neck, and the character of the chest sounds enumerated above, indicated a traumatic lesion of the descending thoracic aorta rather than of the arch or of ascending portion, unless the dilatation was at the very origin of the vessel. As the conditions were growing worse, and rupture certainly approaching, the patient consented to accept the risks of the only operation that offered any chance of success, the introduction into the sac of a certain quantity of wire as a framework or skeleton, each coil of which might form a nucleus for coagulation, producing eddies in the sac and final consolidation. (Moore, 1864.) To facilitate coagulation upon and around this wire framework, the coagulating power of galvanism was brought to bear. (Corradi.)

Ligation was of course out of the question; in the ten cases in which the aorta has been ligated, the result has been uniformly fatal.[1] Scarification of the interior of so large a sac was not hopeful, and the simple introduction of horsehair or catgut certainly did not offer as reasonable chance of success as did the more complete method advocated by Corradi, D. D. Stewart, and others. Simple galvanopuncture urged by Cinicelli, since it leaves behind no framework for deposit of clot, was obviously less certain in its permanent results. The injection of about 300 cubic centimetres of a 1 or 2 per cent. solution of gelatin was considered, but rejected on account of the large size of the sac.[2]

In this operation of wiring, it is essential that strict asepsis be secured, and that no elements of suppuration be introduced, since sepsis and faulty technique are the most frequent causes of death.

In order to protect the skin and subcutaneous tissues external to the wall of the sac from the destructive effects of the electrical current, a vulcanite cannula (size No. 7, French catheter scale) was constructed with a steel trocar (size No. 4, French catheter scale). The thickness of the vulcanite made the introduction difficult, requiring a slight nick of the skin with a scalpel. (A veterinary hypodermic needle, three inches long, and of calibre of 24, is better. It can be insulated by several coats of shellac varnish, best French lacquer set by heat, or by a porcelain coating.) The trocar was introduced in the fourth interspace, the thinnest point of the sac, just outside the costal cartilage, and was driven well into the sac. Upon the removal of the trocar a current of blood spouted three feet into the air at each pulsation of the heart, which, owing to the size of the cannula, made the loss cf blood quite serious. It was, however, controlled by the finger until the wire was threaded in. Gold wire No. 35 had been procured, but proved entirely too fine, as it would not thread through the cannula without crinkling, and I was obliged to resort to silver wire No. 24. During the operation I fortunately had the benefit of the assistance of Dr. Guy Hinsdale, who furnished the following notes: "After six or eight feet had been inserted, the wire was connected with the copper conducting cord of the positive pole of a galvanic battery. The current was supplied by the electric lighting plant of the hospital, reduced by a current controller. A chloride of silver dry cell battery does well. The negative pole was attached to a large, flat, electrode sponge-covered pad, placed between the scapulæ. Five milliamperes were turned on at first, and the force of the current was increased by fives, the patient perceiving plainly each addition, and complaining of pain chiefly in his back, especially when new pieces of wire were connected. More wire was threaded in through the cannula until about twenty feet of coils were inserted. The strength of the current was increased until, during the last fifteen minutes of the hour, eighty milliamperes were measured; eighty-five only for a moment." In my judgment, the current used was too strong, and if equally good coagulation will take place under one of moderate strength, the danger of burning the walls of the sac is lessened. Finney obtained his results with only ten to twenty milliamperes. Coagulation of the blood in the cannula took place very soon after the current was applied, preventing further hæmorrhage, and, on withdrawal of the cannula, the wires having been pushed in as far as possible, there was no hæmorrhage. The opening was closed with gauze and aristolated collodion, and the patient confined rigidly to bed. Aside from the first shock at the sight of the spouting blood, the patient suffered no serious inconvenience, save for the pain in the back, at the negative electrode, and talked cheerfully throughout the operation. He slept the greater part of the night, the next day was much better, and in five or six days was anxious to sit up, although he was not permitted to do so. The only burns were at two areas, of the size of peas, upon the back. The cathodal negative pad should have been of larger size. In a week he could with difficulty be restrained in bed; was eating and sleeping well; had no pain; was able to stop the use of morphia, and had much less oppression. The pulsation in the thorax was lessened at the end of the operation; was still less on the following day, and in a week was diminished at least 25 per cent. His statement is that he is "twice as good as before operation." The original point of thinning anteriorly is much more solid, but laterally below the axilla the pulsation is slightly increasing, and will probably require a repetition of the operation.

In the third week a dilatation of the sac outward into the axilla gave torturing pains in right arm for two days, but this pain was speedily relieved, although the pulsation in axillary region has increased, and I propose to repeat the operation. His sac may be multilocular, or the coagulum in one district may have altered the direction of the blood current, causing dilatation of a new area. Nine weeks after the operation the man was so well that he could not be restrained, and he left the hospital in spite of my earnest protest. Good consolidation of the anterior portion of the sac at the seat of operation was positive.

Abstract from notes by Drs. Musser and Stryker, on admission: "Temporal artery not visible; neck full, only slight arterial pulsation; resonance in both supraclavicular fossæ; percussion resonance on right side beginning at eleventh dorsal spine, crossing to tenth rib at posterior axillary line; no distinct respiratory movements; vocal resonance and tactile fremitus greatly exaggerated, with bronchovesicular breathing over the compressed lung which lay posteriorly near the spine; outside and

anterior to this area respiratory sounds very faint, or lost. Anterior thorax very prominent on the right side over level of fifth rib and over sternum to anterior axillary line. Vocal resonance entirely lost anteriorly; upper thorax anterior, first sound soft and blowing, second sound faintly heard. Left side anterior, apex beat at fifth space from nipple to anterior axillary line exceedingly powerful. Auscultation at apex, loud systolic murmur with first sound; faint diastolic shock and prolonged diastolic murmur. Fourth interspace, fainter systolic murmur, louder second sound, with prolonged diastolic murmur; third interspace, short fainter systolic, long soft diastolic sound; second interspace, dull rough systolic, faint and prolonged diastolic murmur. Aortic, faint first sound; loud, clear second prolonged diastolic murmur. Left lung, respiration normal at apex; vocal resonance slightly increased. Tympanitic resonance from fifth interspace to axillary. With this saccular aneurism of the ascending portion of the arch there is evidently an aortic insufficiency, with hypertrophy and dilatation of the left ventricle."

The man returned to the hospital two months later suffering with increased pain and dyspnœa. The tumor beneath the pectoral muscle at the anterior border of the right axilla had decidedly increased in size, having evidently eroded the ribs. The principal suffering, however, was in the left chest posteriorly, probably from erosion of the vertebræ.

Twenty feet of No. 24 silver wire were inserted through a long hypodermic needle, and a galvanic current of eighty milliamperes applied for one hour. The patient bore the operation well and was relieved of pain even on the left side, owing probably to change in the direction of the blood-current. The wire, however, evidently failed to produce coagulation in the right thorax, and the tumor, having lost the restraining power of the ribs, increased rapidly in size, lifting the entire right pectoral. Although the walls became very thin the sac did not burst, and the patient died slowly from exhaustion four weeks after the second operation, five months after the first operation.

In spite of every effort I was unable to obtain permission for an autopsy, and the exact point of rupture of the aorta must remain in doubt.

Since the above report was written, Dr. Matas (*American Medicine*, June 22, 1901, p. 546. Transactions of the Southern Surgical and Gynæcological Association, 1900) has published an able article on this subject, and Dr. Leonard Freeman also read a paper before the American Surgical Association at Baltimore, May, 1901.

Remarks.

Technique.—The size of the wire should be thoroughly graduated to the calibre of the needle, which latter should be tested to ascertain the smoothness of its bore, as it is essential that the wire should slip easily through it. I see no practical difference between silver, gold, and platinum wire. Size 27

to 30 is probably about the best diameter. Finney uses silver alloyed with copper, 75 copper to 1000. This, when drawn down from No. 8 to No. 27, makes a close coil, is very pliable, and corrodes moderately with galvanism. Stewart,[3] who has given careful attention to this subject, found that iron wire was undesirable, for the reason that the passage of the current rapidly decomposed it and liberated iron chloride and oxide in such quantities as to be dangerous if washed into the vessels, with a probability of causing thrombi. Steel wire coils better than silver, but is too stiff, and may injure sac.

The amount of wire should be regulated by the size of the aneurism, its object being to form a skeleton for a clot; the amount should be so regulated that it will fully reach all portions of the sac, for which reason it should be previously wound so as to coil and snarl in different directions. The wire for a large aneurism can be wound upon a sterilized rolled towel, so as to make large spirals in the sac; for a smaller sac, it should be wound upon a glass or spool; in either case it should be carefully arranged and prepared so that there will be no delay or kinking during the process of feeding the wire in through the cannula. If the wire kinks, other needles may be inserted at different points of the aneurism, all the wires being attached to the positive current. The arrangement of the coils can be well observed by feeding the wire into a glass flask. If the wire is properly wound before operation, it is very improbable that the initial point will strike the opposite wall. If too large a quantity is used, pressure upon the sac from within might cause ulceration and rupture, and might also interfere with contraction of the sac; moreover, if coils lie against the wall and the current is too strong, the sac may be burned. Moore used as high as 108 feet, and Abbe, 150; Roosevelt introduced 225 feet of steel piano wire, applying a galvanic current of twenty-five milliamperes for thirty minutes. Probably five to twenty feet would be the proper amount.

It is very important that the tissues be protected from the galvanism, lest an open sloughing track be made into the

aneurism. For insulation of the needle, glass, sealing-wax, caoutchouc, etc., have been tried, but best French lacquer or varnish, set by heat, seems best. Lacquer will not stand boiling nor soaking in a carbolic solution, but it can be thoroughly sterilized by dry heat carried up to 300 degrees; then wrapped in a sterile towel. A long veterinary hypodermic is better than a trocar and a cannula, even of same size, since the wire can be inserted half-way into the needle before the puncture is made, and assists in controlling primary hæmorrhage when the needle is inserted.

There is always risk that the wire may enter the aorta, as has happened in several cases, and minute or larger clots may be washed off and form emboli.

Traumatism as a cause of aortic aneurism is not largely mentioned by authors, although cases are reported by Lancesi, Munro, Sansom, and others, even where the arteries were normal.

Traumatic aneurism of the thoracic aorta is rare (Brown, of St. Bartholomew's Hospital, found only eight among 228 aneurisms), since it is better protected than most of the vessels, and the arch is more liable to atheromatous degeneration.

Riesman[4] reported a case in which there was limitation of motion in the spinal column, with no tenderness over the vertebral spines, but with torturing pains. An exploratory incision was made over a tumor in the back, but finding that the tumor pulsated violently, the operation was wisely abandoned and the wound closed; the aneurism burst later into the left pleural cavity.

A traumatic thoracic aneurismal sac may leak slightly, as in the case which I reported[5] in which a man sixty-four years of age was injured by a bale of carpet weighing three hundred pounds falling upon his shoulders. He lived two days with a rent in his thoracic aorta one-half inch long. The outer coat or adventitia, however, was not perforated. The inner and middle coats having been torn, the blood dissected its way between the muscular layer and the outer coat

throughout the entire extent of the thoracic aorta, and down the abdominal for five inches. The only symptom was the intense pain in the thorax and back, aggravated by every movement, this pain slowly extending from thorax to abdomen. There was no cough. On the second day the outer coat gave way about one inch below the original rent in the inner coats, and the patient died in a couple of minutes from the gush of blood which entirely filled the left pleural cavity. The arch of the aorta was not atheromatous, and in the thoracic aorta the only point of visible atheroma was at the area which gave way.

In aneurism of the thoracic aorta there is usually urgent dyspnœa and a sensation of distress and fulness in the chest. In time there is nearly always an erosion of the bodies of the vertebræ, and a rupture may take place either into the mediastinal connective tissue or into the pleural cavity.

Stewart,[6] Hershey,[7] and Hunner[8] report twenty-three cases treated by this method, and my own makes the twenty-fourth. The article of Hunner is most complete.

Rosenstirn, in an aneurism of the ascending aorta in a member of a rowing crew, first tried iodide of potassium, Tufnall's rest treatment, and barium chloride, then used two feet of No. 28 wire, passing a current of seventy milliamperes for thirty minutes; two years later the man was reported in good condition.

Stewart in his first and unsuccessful case, in a huge aneurism of thoracic and abdominal aorta, occurring in a wrestler, six years' duration, inserted two and one-half feet of No. 23 wire (wound upon a two and one-half inch roll to make spirals), and passed a current of seventy milliamperes for one hour. The sac was firmer on the third day, but ruptured on the ninth. Firm clots were found in all portions of the aneurism, and it was difficult to separate the clots from the wire. He used a needle insulated with shellac varnish, but the coating became softened too much by hot water. The use of carbolized glycerin as a lubricant he also found disturbed the insulation. For the negative pad he used a large moist felt plate at the back. In his second and successful case (with Salinger) of aortic and innominate aneurism, size of a fœtal head, he used ten feet of No. 30 gold wire, passing a current of thirty to eighty milliamperes one and one-quarter hours.[9] Galvanism was applied to several wires introduced through hollow needles placed at separate points and connected to the same rheophore. Pulsation and expansion lessened on the second day, also thrill. Four weeks later, second opera-

tion in upper part of sac. The patient lived three and one-half years, although he had endarteritis with extensive renal and cardiac disease at the time of operation, was syphilitic and of intemperate habits. He died from a thrombus in the middle cerebral artery. A thoroughly consolidated organized fibrous clot was found deposited about the coils of wire, and the cavity of the sac was completely obliterated.

Stewart's[10] third case was a fusiform aneurism of the abdominal aorta, which was made more prominent by a retroperitoneal tumor, lifting it forward. An abdominal section was done by Drs. Deaver (H. C.) and Neilson, and ten feet of silver wire introduced. A current of fifty milliamperes was passed by the anode for half an hour. On the fifth day the patient died suddenly. Large amount of blood in stomach and upper bowel. A tumor springing from the bodies of eroded vertebræ surrounded the aorta at cœliac axis; thoracic aorta above dilated. There was a small saccular aneurism of the splenic artery. The wire had entered both the saccular dilatation and the dilated aorta, but no clots were found adhering to the wire. The case was evidently not a suitable one for operation.

His fourth case was a syphilitic, who for fourteen months had suffered severe pain in the chest, with pulsating tumor in left posterior thorax. Fourteen feet of gold were introduced. Galvanic positive current applied, increasing from twenty to eighty milliamperes for eighty minutes; immediate diminution of pulsation and great relief from pain and other symptoms for eight and one-half months, when death occurred. No autopsy.

His fifth case[11] (with Dr. Noble), a syphilitic drunkard, had suffered from severe abdominal pain for more than a year; was greatly emaciated. Celiotomy done by Dr. Noble, exposing an aneurism of abdominal aorta. Nine feet drawn gold wire, No. 30, introduced; galvanic positive anodal current sixty-five milliamperes passed for an hour. Improvement immediate and progressive, pain lessened, and, all symptoms of aneurism having disappeared, in five months resumed his work. Died at end of nine months of acute dysentery, with no symptoms of return of aneurism.

In another case, a large thoracic aneurism, Stewart introduced wire on three different occasions, with good temporary result. Man died in nine months from rupture of sac.

In another case, seen with Dr. Hare,[12] a syphilitic man with aneurism of transverse aorta, accompanied by pain, dyspnœa, and cardiac disturbance, nine feet of gold wire were introduced through an insulated needle, and the anodal current, seventy milliamperes, passed for an hour. Pulsation and bruit diminished at end of operation, and bruit disappeared at end of forty-eight hours. Five weeks later patient was sitting up without pain. Bruit, pulsation, and thrill had entirely disappeared, cough had ceased, and patient greatly improved. Died seven months later from pressure of sac on trachea.

Hare[13] reports another case, man, thirty-eight years of age, large aortic aneurism; patient in bed for seven months and had lost sixty pounds. Ten feet of gold wire, current up to 100 milliamperes for one

and one-half hours. Contraction of sac and great relief. Second similar operation at end of several months. Died in seven months from rupture of sac. No autopsy. Life prolonged and made much more comfortable.

Hershey[14] reports a case of aneurism of the innominate and aorta which had deep-seated pain in chest beneath and to right of sternum; dyspnœa and bulging. Treated by complete rest; Valsalva's diet; barium chloride, three-quarters grain, three times a day. Later he introduced wire, 14 carat gold, gauge 28; wire snarled in order that it might bunch rather than coil, wrapped on glass vial, placed in clear carbolic solution. Hypodermic needle, 22 gauge, insulated by layer after layer of shellac varnish, each layer set by heat. Thirty-celled galvanic battery; milliamperemeter. Wire kinked after two and one-half feet had been passed. Positive pole attached to wire; negative pole, flat sponge six by eight on on back. Pain in negative electrode considerable. Increased current to seventy, continued for one hour, then diminished to forty. On removing needle, wire was cut and pushed in. Evidences of immediate consolidation; patient able to sleeep that night; gain in flesh. Nine and one-half months later was living, with considerable pain in chest, but was able to work. Died at end of a year, rupture of sac.

Kerr, in an aneurism of aorta, inserted ten feet silver wire; galvanic current one-half hour; patient feeling as well as ever one year later.

Kerr, ascending aorta, six feet wire; current fifty minutes; death eighteenth day; firm clot about the wire.

Burresi, ascending aorta, wire No. 30, seventeen inches, current twenty-five minutes; immediate signs of consolidation; death in 100 days.

Barwell, ascending aorta, ten milliamperes, seventy minutes, in twelve hours had signs of consolidation, death on seventh day; had thick, firm decolorized clot in sac.

Roosevelt, aortic; 225 feet steel piano wire, galvanic current, twenty-five milliamperes for thirty minutes. Death on twenty-third day.

Abbe, innominate; 150 feet wire. Current reversed during later part of operation, which tended to disorganize the clot, an error in technique of vital importance as pointed out by Stewart. Death second day.

Halsted. Man, twenty-seven years of age, pulsating abdominal tumor. Celiotomy performed. Five feet of No. 27 wire introduced and anodal current up to 100 milliamperes passed for one and one-half hours. Died in forty hours from rupture into pleural cavity. Wire coils found to have pressed against walls, probably injuriously. Loose, easily detachable coagula upon the wire coils.

Reeve.[15] Aneurism abdominal aorta; epigastric tumor; great pain controlled by large doses of morphia. Celiotomy. Seven feet silver-plated copper wire. Eighty milliamperes for fifty minutes. Patient lived twenty-four hours. One loop of wire was found to have passed ten inches up the aorta, while a single strand had reached the aortic valve of the heart. Aneurism distinctly sacculated; opening into sac one inch in diameter.

Corson.[16] Man, aged thirty-one years; excessive user of alcoholics. Pulsating tumor in neck. Six feet wire. Eight cells of a dry battery

for two hours. Partial immediate consolidation. Died on second day. Wire found to have coiled closely in contact with sac, probably because pure silver was used and not drawn wire, which latter coils better.

Finney.[17] (Osler.) Aneurism; thrill and pulsation. Man, twenty-five years of age. Bookkeeper. No traumatism. Celiotomy; pancreas flattened over tumor. Five feet silver copper alloy (75/1000) wire, drawn from No. 8 to No. 27. Galvanic current increasing from thirty to seventy milliamperes; one hour. Thrill disappeared in one-half hour. Sac firmer; had pain after operation; required one-quarter grain morphia every two to four hours. Temperature 103.7° F., caused probably by slough from negative pad on back and infection of abdominal wound. Temperature remained high for two weeks. Died on twentieth day, from hæmorrhage through external wound from slough. Autopsy: Diffuse arterial sclerosis. Opening in aorta one and one-half centimetres in diameter. Aneurism was of the superior mesenteric artery. Wire had entered sac, and one loop had burned side of sac, causing hæmorrhage. Transverse portion of duodenum necrotic, from interference with circulation in superior mesenteric artery, and filled with bloody fluid where oozing had taken place. Clots about the wire and in aneurism fairly firm.

Finney.[18] Man, fifty-one years of age. History negative as regards syphilis. Sternum lifted at each systole. Pulsation extending to right. Was given nine gelatin injections of 250 cubic centimetres of 1 per cent. solution before operation, and sixteen of a 2 per cent. solution afterwards. Ten feet of silver wire alloyed with copper; current of ten milliamperes for one hour; twenty milliamperes for fifteen minutes additional. Pulsation diminished after third day, but on the twelfth day pain moved towards the left side. Gelatin injections recommenced. Two months later resumed work, but died six months afterwards at sea, presumably from rupture.

Finney.[19] (Osler.) Man, thirty-nine years of age, history of alcohol, tobacco, and syphilis; also a heavy eater. Bulging right side of chest; great cyanosis and dyspnœa. Several aspirations of right pleural cavity; withdrew blood-tinged serum. Diagnosis: Aneurism near the heart or in thoracic portion. Ten feet drawn silver wire alloyed with copper, ten milliamperes, one hour. Patient felt each progressive increase in the volume of the current. Condition improved greatly for fifteen days, but right pleural cavity required frequent aspirations. Similar operation twenty-four days later. Third similar operation nineteen days later. Died eleventh week after first operation, with symptoms of pressure upon trachea. No autopsy.

Finney.[20] (Osler.) Man, thirty years of age. Abdominal aorta. Celiotomy. Eight feet of highly drawn wire of sterling silver, ten milliamperes, one hour. Section of the overlying pancreas was avoided by drawing the liver to the right and making the puncture in the upper right quadrant of the sac. Aneurism probably of the superior mesenteric. Greatly improved in symptoms; not much change in physical signs at the date of his discharge from the hospital six weeks later.

In summing up this record, we find that permanent cures are few, as must necessarily be the case in so fatal a condition as aneurism of the aorta, yet in one-half the cases operated upon life was certainly lengthened, and all of those who survived the immediate effects were rendered vastly more comfortable. This result is certainly satisfactory when the fact is taken into consideration that these cases were necessarily fatal ones if untreated.

Ten cases undoubtedly had their lives shortened by the procedure, but several of the patients had fusiform aneurisms and were not proper subjects for the operation.

Rosenstirn's case was alive eleven years after the operation. The post-mortem of one of Stewart's patients made three and one-half years later showed a solidly coagulated tumor. Kerr's case at the end of ten months showed no signs of the aneurism. In Noble's patient all symptoms had disappeared, and another patient died of dysentery nine months after the operation. Finney's fourth case was at last report living, with great improvement in symptoms. My own patient at nine weeks is too recent to permit of any conclusion save that great comfort and relief from pain and dyspnœa have been secured.

Ten cases then have been positively benefited, one is uncertain, and while the remainder died at various periods within a year, yet nearly all of those that survived the immediate effects of the operation were rendered decidedly more comfortable.

This method, therefore, of dealing with a most serious condition seems to offer a more reasonable hope of success than any other plan at present discovered.

BIBLIOGRAPHY.

[1] Deutsche Zeitschrift für Chirurgie, 1879, Band xii, p. 405. Keen: Philadelphia Medical Journal, 1900, March 3, p. 470.

[2] Futcher: Journal of the American Medical Association, January 27, 1900, p. 204. Bulletin de l'Académie de Médecine de Paris, October, 1898.

[3] Stewart: British Medical Journal, August 14, 1897, p. 387.

[4] Riesman: Transactions of the Philadelphia Pathological Society, Vol. xx, p. 40.

[5] Willard: University Medical Magazine, Vol. iii, p. 622.
[6] Stewart: Philadelphia Medical Journal, November 12, 1898. American Journal of the Medical Sciences, October, 1892, p. 432. American Journal of the Medical Sciences, August, 1896, p. 170. British Medical Journal, August 14, 1897, p. 387. Transactions of the Philadelphia College of Physicians, 1897, p. 43. Transactions of the Philadelphia Pathological Society, Vol. xviii, p. 220.
[7] Hershey: Therapeutic Gazette, Vol. xii, 1896, p. 590.
[8] Johns Hopkins Hospital Bulletin, November, 1900.
[9] Stewart, D. D.: Transactions of the Philadelphia College of Physicians, 1897. British Medical Journal, 1897, p. 386.
[10] Philadelphia Medical Journal, November 12, 1898.
[11] Stewart, D. D.: Philadelphia Medical Journal, June 25, 1898, p. 1205.
[12] Therapeutic Gazette, May, 1898.
[13] Therapeutic Gazette, January 15, 1900, p. 9.
[14] Therapeutic Gazette, Vol. xii, September, 1896, p. 590.
[15] Reeve: Johns Hopkins Hospital Bulletin, November, 1900, p. 271.
[16] Corson: Johns Hopkins Hospital Bulletin, November, 1900, p. 271.
[17] Finney: Johns Hopkins Hospital Bulletin, November, 1900, p. 273.
[18] Finney: Johns Hopkins Hospital Bulletin, November, 1900, p. 274.
[19] Finney: Johns Hopkins Hospital Bulletin, November, 1900, p. 275.
[20] Finney: Johns Hopkins Hospital Bulletin, November, 1900, p. 276.

DISCUSSION.

Dr. D. D. Stewart said that he had been interested in this matter since 1890, when he did his first operation, and, as he had done quite a number since, naturally he had been able to draw some deductions concerning the best technique to employ, and he would speak in a general way as to the technique of the operation.

Almost invariably, before wiring, he introduced a fine canulated needle to assist in determining the thinnest part of the sac wall, and that least protected by clot. He preferred to introduce his needle and wire where the sac was least protected. He did this at the time of operation, or shortly before. He not only punctured before, but subsequent to the operation. He had been very much interested in determining, a short time after the operation, the difference between the depth to which he had to introduce his needle, before spurting of blood occurred, prior to the operation and subsequently. In some cases the difference had been very marked indeed. In one instance, the specimen of which he afterwards showed before the College of Physicians (the operation had been done three and a half years before death, which had resulted from another ailment), needling showed a sac wall scarcely over

two lines in depth, at the point of puncture, unprotected by clot. (See *American Journal of the Medical Sciences*, August, 1896.) Four weeks after the operative procedure, "a needle of quite large calibre was thrust into the sac to a depth of two inches in several situations, in which, at the time of operation, blood spurted at its introduction when apparently only beneath the skin. The needle in this second attempt was found to firmly engage the clot, though thrust perpendicularly up to its hilt in the sac. It could not be circumducted save with effort, and escape of even a drop of blood at any depth did not occur; nor was the needle or wire (which last it had been attempted to reinsert through the needle) blood-tinged when withdrawn. This beautifully demonstrated the solidification of the aneurism." This case was one of very large innominate aneurism, concerning the specimen of which Dr. John Ashhurst made the following remarks: "It shows that the cavity of the sac was as completely obliterated by the contained clot as it could have been by either the Hunterian or the Amyllian operation; in fact, as far as this part of the artery is concerned, the circulation was as completely obliterated as it could have been even by extirpation of the whole aneurismal sac." (See *Transactions of the College of Physicians*, Vol. xix, 1897, p. 43.)

He had never had ill results from needling or wiring aneurisms. He adopted antiseptic precautions. His first case was a very large aneurism, involving both the thoracic and abdominal aorta, which had eroded the bodies of several dorsal vertebræ. The sac was twelve inches in oblique measurement. In his later operations he employed as a medium for passing the wire and subsequent electrolysis insulated gold needles, of rather small calibre, and made of gold insulated with porcelain.

The wire that he employed was either gold or silver. He had been using gold wire in preference to silver because he could have it more tightly drawn. It is important that the wire that is used shall assume spiral coils, one that may not easily be deflected by loose coagula in the sac. He used wire drawn to twenty-eight or thirty gauge. Silver wire he had used on a number of occasions, but he preferred gold wire. He had never introduced more than fifteen feet at one operation. It is of the utmost importance that there should be a relation between the amount of wire introduced and the size of the aneurism treated. There cannot be expected subsequent contraction of the aneurism to the extent

desired, that is, obliteration of the sac cavity, if too much wire is introduced. It is extraordinary the amount of wire that some of the earliest operators used, both without the employment and with the employment of galvanism. For instance, in a case operated upon by Roosevelt, he introduced 220 feet; and in one by Abbe 150 feet were introduced subsequent to the passage of 150 feet of horse-hair. He introduced two or more insulated needles, and passed the wire in equal quantities through each. By this means the whole interior of the sac is better reached by a smaller quantity of wire. If the wire is passed through but one needle, it may go in but one direction, being deflected by loose clot, and not reach so well all parts of the cavity, and none of it tend to lie against the sac wall itself, even if portions of this are unprotected by clot. An important result which may follow contact of portions of wire with the unprotected sac wall is the formation of wall, or white, thrombi, due to the electrolytic action of the current on the endothelial lining of the sac wall. White thrombi may be expected to later form here by the deposition of leucocytes from the abraded vessel wall and from the blood-stream. From these thrombi organization would tend to proceed to the red thrombi formed about the wall within the aneurism. Thus may be obtained the results of Macewen's operation by needling, plus that obtained by wire and the electrolytic action of the galvanic current on the contained blood.

If it is intended to introduce a definite quantity of wire through but one needle, and in process of passing the wire kinking occurs, a second needle should always be at hand for the passage of the additional quantity, and this needle is better introduced in a portion of the sac somewhat remote from the first needle. Of course the wire from the various needles should be all joined to the same, the *positive,* pole. It should be a rule that has no exception, to use only the positive pole within the sac. The reason for this he had entered into very fully in his various publications on this subject. If the negative pole is connected with the needle, the clot is always soft and friable. Bubbles of hydrogen tend to accumulate about the negative needle and assist, also, in softening the clot. If the negative pole is used after the positive, which has sometimes been done, it will tend to dissolve the already formed clot. Although he had pointed this out again and again, yet this point is not often attended to by operators.

Concerning the amount of current strength, 120 is the highest amperage he had used. He had continued for an hour and a half with a current strength of sixty-five milliamperes. A large current strength should not be continued too long. He had noticed in several cases operated upon that visible signs of coagulation in the sac appeared rather early, and then were not so marked after an increase in the current strength which had been continued for a longer period. It seemed as if coagulation had occurred, and that the coagulum tended to again become softer. He did not now, as he once did, favor the long application of the current, nor of the very high current strength that he at first used. He was inclined not to use a greater current strength than sixty to eighty milliamperes, and not to continue this for too long a time. The current is started from zero and gradually run to the number of milliamperes desired, say eighty, and this is reached in about ten minutes. The current is here maintained for nearly the requisite time, and then gradually diminished to zero. It is of course unwise to turn on a great degree of current suddenly. It has occurred to him on several occasions that the patient had accidentally moved from the large negative plate, thus interrupting the current, and before the current could be switched from the battery it had been closed by his again lying against the plate. Nothing had happened as a result of this, but of course it was very undesirable that it should occur. He used as the indifferent or negative pole a large clay pad, upon which the patient commonly lies. If desired, in operating on the thoracic aorta anteriorly, this pad may be laid upon the abdomen.

As to the use of iron wire, it has been advocated, but he did not recommend it. Some ten years ago he made experiments as regards the effects of different current strengths passed through iron wire, and he found that, as mentioned in his first paper on this subject (*American Journal of the Medical Sciences,* October, 1892), a large amount of detritus always results from the passage of a galvanic current of even low amperage through iron wire. An amount of ferric oxide and chloride is thus formed, which might result very injuriously through the passage of some of this detritus as emboli into the blood-stream.

He regarded it as of importance that the patient should be prepared for the operation. His physical condition should be as good as possible. It is of the utmost importance that the heart

should not be overacting, and that the blood-pressure should be low; in other words, that the condition should be favorable for the formation of clot within the sac. It is desirable that the patient should be thoroughly reassured prior to the operation that little or no risk attends the procedure, and that practically no pain is experienced. He administered morphia hypodermically prior to the operation, and if the blood-pressure was very high, aconite was given a few days before the operation. In the last case he operated on a few months before, good immediate results were apparent, although, despite the use of morphia and aconite, the heart's action could not be quieted. There was a pulse of about 180 during the operation, and yet the impulse in the sac became less marked as the current passed, and the aneurism more firm. This immediate effect from the operation had been noted by himself and others in several of his cases, and there seemed no doubt that the coagulation does occur during the operation through the passage of the current. In one of his cases that he operated on for Dr. Salinger a number of years ago, at the Philadelphia Hospital, the immediate result of the passage of the current was remarkable. This was demonstrable to all present. The needle had been introduced into the weakest part of the sac, and fell unless upheld, so utterly unprotected was this part of the sac by clot. Towards the end of the electrical session the needle was supported by the newly formed clot, and remained firmly perpendicular.

He never made an incision into the skin for the introduction of the needle, which he inserted by gentle pressure and spiral manipulation into the sac wall. Were he to use a cannula, and make a primary incision through the skin, he should be afraid to attack the weakest part of the sac wall. Before the wire is introduced, the blood spurts from the needle, and continues to leak during the passage of the wire until the current is turned on. As soon as a few milliamperes of the current have passed, bleeding ceases, and does not recur. Concerning the removal of the wire, he cut the wire close to the needle, and then simply spirally twisted his needle, making counter-pressure with the fingers until the needle was withdrawn from the sac, pulling the wire out a little. The wire was then close to the skin, and the skin pulled forward over the wire, after which the site of puncture was sealed with iodoform and collodion.

In answer to a question as to the greatest length of time that

the patient has lived after such a procedure, Dr. Stewart said that one of his cases lived three and a half years, and died from an affection distinct from the aneurism. In this case, that operated on for Dr. Salinger, before referred to, the cure was complete. The aneurism was completely solidified. It was of this case that Dr. Ashhurst made the remarks referred to.

Dr. De Forest Willard added that he had been concerned by the puncture at the thin portion of the sac. When a surgeon feels an aneurism of the size of a child's head pulsating directly underneath the skin, he naturally hesitates to make a puncture at that point, lest he weaken the sac and hasten rupture. It was for this reason, also, that he feared, if he did not thoroughly insulate the wire, that there might be destruction of skin and subcutaneous tissue by the current of electricity that would open the aneurism a few days later and cause a rupture. In removing the cannula he was careful to push the wire down thoroughly underneath the skin and into the sac, so as not to have the wire lead the blood out from the aneurism through the skin, or permit infection of the sac, along the wire from without. The point of puncture was supported thoroughly with collodion and aristolated gauze. There was no bleeding at the time of the withdrawal of the cannula, and there had been no bleeding since. That point of the sac is now apparently stronger than several other areas. The weakest point at the present time is under the axilla; yielding, he feared, was extending in that direction. He proposed, in the course of one, two, or three weeks, if the patient was as well as he was then, to repeat the operation, and endeavor to secure more clot in the outer and upper portion of the sac.