TRANSACTIONS

OF THE

PHILADELPHIA ACADEMY OF SURGERY

STATED MEETING, HELD JANUARY 6, 1908.

The President, JOHN B. ROBERTS, M.D., in the Chair.

GUNSHOT WOUND OF STOMACH, WITH POSTERIOR DRAINAGE.

DR. EDWARD B. HODGE, JR., presented a man, aged 19 years, who was admitted to the Presbyterian Hospital on November 12, 1907, in the service of Dr. J. H. Jopson. Two hours before he had been accidentally shot with a BB bullet from an air rifle from a distance of 100 feet. The bullet penetrated a wire screen-door, shirt and undershirt, making a small wound 2 inches below the ensiform slightly to left of median line. Patient had taken no food for 5 or 6 hours, had not vomited and was in good condition. Temperature, 98.8°; pulse, 84; respiration, 26.

Immediate operation by Dr. Hodge. Incision through wound showed penetration through left rectus ranging toward left. A perforation in anterior wall of stomach near lesser curvature and nearer cardiac than pyloric end was closed with silk purse-string suture, reinforced by interrupted silk Lemberts. Little soiling of peritoneum. Air and blood were noticed behind gastro-colic omentum. This structure was torn through, and a perforation found on the posterior wall of the stomach toward the cardiac end. This was closed in a similar manner. No other injury could be found, but in view of the wound of the posterior stomach wall and a possible pancreatic lesion, posterior drainage was considered wise. Through a small incision in the left ileo-costal space a long forceps was pushed into the lesser peritoneal cavity and a medium-sized rubber tube withdrawn. The gastro-

colic omentum was closed over this after dry sponging of the peritoneum. A small cigarette drain was inserted to the anterior stomach wound and both incisions closed with interrupted silk-worm gut.

For 24–36 hours the patient gave considerable anxiety on account of marked restlessness, rapid pulse, 130–160, and respiration, 30–40, with some distension of the upper abdomen. After the second day convalescence was smooth. On day after operation there were 3 dark tarry stools, and for 10 days 1–3 of similar though lighter color. Tube was gradually shortened on account of moderate purulent discharge. Stitches removed on tenth day and patient discharged in 4 weeks.

Dr. George G. Ross said that, several years ago, at the Germantown Hospital he saw an Italian who had been shot. The ball went in the lower chest wall between the lower ribs, ranged downward and inward. The skiagraph showed the bullet resting against the vertebral column. The man was shot when his stomach was absolutely empty. There was reason to believe from his bowel movements that the bullet had gone through both walls of his stomach. He absolutely refused operation. He developed quite a cough and violent peritonitis, but finally got well without operation or drainage. Dr. Ross believes that there was a reasonable doubt as to perforation of the stomach, although it was thought there was from the clinical facts.

STAB WOUND OF THE DIAPHRAGM.

Dr. Francis T. Stewart reported the case of a man, aged 22 years, colored, who was admitted to the Pennsylvania Hospital December 14, 1907, in the service of Dr. Gibbon. The patient had been stabbed in the left mammillary line with a penknife, which entered the sixth interspace, cut through the seventh costal cartillage obliquely downward and outward and severed the muscles of the seventh interspace, the resulting wound being 3 inches in length. Through this wound protruded a portion of the stomach about the size of an orange. The pulse was 100, the temperature normal, and the respiration quiet. There was considerable pain in the region of the wound, rigidity of the left side of the abdomen, but no vomiting, displacement of the heart, or pneumothorax. Under ether anesthesia an incision was made through the left rectus abdominis. That portion of the stomach which

protruded through the external wound was then pushed into the thorax, and the opening plugged with gauze in order to prevent the entrance of air. The stomach was then drawn upon from the abdominal cavity, but owing to the negative pressure in the thorax, reduction was found to be rather difficult until assisted by pressure from above through the thorax. The stomach was uninjured and there were no other visceral lesions. The hole in the diaphragm was about 2½ inches long and ran in the direction of the muscular fibers, from the pericardium downward and outward. After pushing the diaphragm upward with the hand in the abdomen the wound in the diaphragm, the edges of which were about ¼ of an inch in thickness, was sutured, through the seventh intercostal space, with catgut without resecting a rib. The severed costal cartilage and the intercostal muscles were sutured with catgut, the skin with silkworm gut, no drainage was employed, and the diaphragmatic region was immobilized with adhesive straps. During the operation some air entered the thorax, but later there was no displacement of the heart and only a slightly higher pitch in the percussion note over the thorax. The lung was neither seen nor felt during the operation. The following day there was some pain and slight dyspnœa, both of which subsided in the course of 48 hours. The wounds healed by primary intention, and the patient left the hospital on the sixteenth day.

Dr. John N. Gibbon recalled a case of his own at the Pennsylvania Hospital several years ago, that of an Italian who was stabbed in the back and when he was seen by Dr. Gibbon shortly after the injury there was protruding through a wound at the lower angle of the scapula quite a mass of omentum, as large as three or four fingers. In this case Dr. Gibbon resected a rib, ligated and removed a portion of the omentum, returned the stomach to the abdominal cavity and closed the diaphragmatic opening. The knife the patient was stabbed with was a small one which passed between the ribs, and one rib acting as a fulcrum the knife cut a 2½ inch opening in the diaphragm. Dr. Gibbon opened the abdomen because he was afraid there might be an injury of the stomach but nothing was found and the abdominal wound was therefore closed. The patient did well for 24 hours but then developed a double pneumonia, and the man died 6 or 7 days after the receipt of his injury. An autopsy was per-

formed and the pneumonia on the side where the patient had been injured was found to have practically subsided. His wound had completely healed and the active process was all on the opposite side.

Dr. Harry C. Deaver said that in subdiaphragmatic abscesses complicating appendicitis he had resorted to drainage by resecting the tenth rib posteriorly and making the incision in the diaphragm, stitching it to the muscles of the chest wall. He has found this very successful and also that it gives good drainage. Subdiaphragmatic abscesses are very hard to drain. In the last case upon which he operated, relieving the abscess in the way described, he depressed the liver and ran a large drainage tube between it and the diaphragm. This drained very nicely and there was no unpleasant results from stitching the diaphragm to the muscles of the chest wall.

Dr. John B. Roberts said that a good many years ago when he did his first nephrotomy he punctured the diaphragm by accident. He could hear the whistling of the air in the chest. The patient, however, recovered satisfactorily.

PRIMARY TUBERCULOSIS OF THE CÆCUM.

Dr. John H. Jopson reported the case of a man, aged 26 years, who was admitted to the Presbyterian Hospital, October 14, 1907. His family history was negative. Six weeks before admission he had been knocked down by a horse, and a wagon ran over him, the wheel passing over the left thigh just below the hip, and across the right iliac fossa. He had considerable pain in the abdomen and in the left hip, which lasted about three days, when he returned to light work. Pain continued, but of mild degree, until a week later, when he attempted heavier work, and from that time he suffered more severely, until 2½ weeks before admission, when he had to quit his work. He then detected a mass in the abdomen, which he thinks has increased in size, and since then has become the seat of increasing pain. Three weeks before admission he says he passed blood by the bowel for three days. Since then there have been daily bowel movements, sometimes loose, sometimes constipated. He has only vomited once. His appetite has been poor, and his only nourishment of late has been milk. Previous to his injury he had been in good health.

On admission his temperature was 100°, pulse 120, respiration 28. He was in good condition, well nourished, although of rather spare physique; nothing of note in the chest. There was a mass in the right iliac region about the size of a small orange, moderately sensitive, and the seat of pain. Leucocyte count, 18,100. His temperature fell below normal the day after admission, and continued below normal, between 97° and 98°. The pain and tenderness lessened, and the mass decreased apparently in size. On the 21st, one week after admission, the leucocyte

Fig. 1.

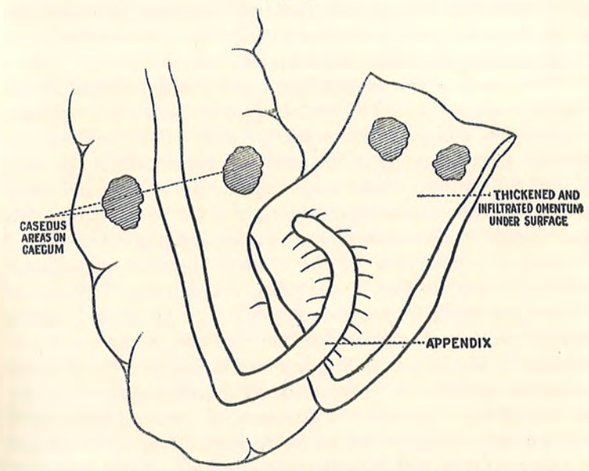

Primary tuberculosis of cæcum. In this sketch the diseased portion of omentum has been separated and turned over, showing the relationship of the appendix.

count was 14,000, and three days later 9,700. Operation October 25, 1907. Incision over the tumor showed it to be intra-peritoneal. The mass was formed of a portion of the end of the large omentum, overlying and adherent to the anterior wall of the cæcum, and the entire mass was fastened to the peritoneum over the inner wall of the false pelvis. The cæcum and adherent omentum were peeled off, which disclosed a few caseous areas on the underlying peritoneum. The omentum was stripped from the cæcum to the anterior surface of which it was adherent. Examination of the under section of the portion of omentum so liberated

showed the appendix adherent to it, small, short, and stripped of its peritoneal coat. Two caseous areas, about ⅓ inch in diameter, marked points on the cæcum adhesion (Fig. 1). The rest of the peritoneal coat of the cæcum was inflamed and thickened. There was no gross enlargement of the cæcum, however, and the neighboring intestines were normal in appearance. The adherent omentum was much thickened and altered in appearance, for a distance of 2½ inches by 1½ inches, and was ¾ of an inch in thickness. It was ligated from the rest of the omentum, and removed with the appendix fastened to it after ligation of the base of the appendix. Iodoform gauze strips were packed over the raw surfaces, and the wound partially closed.

Convalescence was uninterrupted, and the wound was healed in about three weeks. The temperature remained normal, and no induration was present beneath the scar. Pain was entirely relieved. Careful physical examination before discharge was practically negative. There was a slightly duller note and some increase in tactile fremitus over the right apex, but no râles. He gained weight and strength, and was discharged in good condition.

Careful examination of the excised omentum showed on microscopic examination a caseating, tuberculous infiltration. This was confirmed by microscopic study. Serial sections of the appendix were made, which from its position in the mass was suspected to be the seat of the primary infection. These failed to show the presence of tuberculosis. The pathological diagnosis was, therefore, a primary tuberculosis of the cæcum, which would be included under the entero-peritoneal type of Hartmann and other writers, and secondary tuberculosis of the omentum. The omentum had well fulfilled its function of "abdominal policeman" in covering over the primary focus and assisting in the prevention of more extensive peritoneal infection.

Dr. Jopson added that Henry Hartmann, in an address on the "Surgical Forms of Ileo-Cæcal Tuberculosis," before the Medical Society of London, December, 1906 (Brit. Med. Jour., 4-13-1907), gives a clear and concise review of the subject and an analysis of cases operated upon. Charles Greene Cumston has recently covered the subject very thoroughly in connection with a report of two cases (Annals of Surgery, Nov., 1907). Hartmann points out that the cæcum is the commonest seat of tuberculosis in the entire intestine, and that when the only

portion of intestine involved it is usually a primary infection. Tuberculosis of the cæcum attacks by preference adults between 20 and 40 years of age. The cases admitting of surgical treatment are divided into the entero-peritoneal and hyperplastic types. In the first the cæcum, and with it frequently the ileum, is the seat of ulcers, and around it develop secondary peritoneal inflammation, adhesions, abscesses, and oftentimes fistulous tracts opening externally. The hyperplastic type, on the other hand, which is the most important surgically, is generally limited to the cæcum, beginning near the valve, and when it spreads, does so toward the colon; it is marked by an increase in size of the cæcum with great thickening of its walls, and oftentimes the formation of a fibro-adipose enveloping mass. It is commonly non-adherent; its cavity is greatly decreased in size, frequently the site of stricture, and the mucous membrane is usually ulcerated. The appendix is often involved in the inflammatory exudate, but is usually patulous. As Hartmann points out, the infection may simulate one of two commoner conditions; viz., appendicitis and malignant tumor. The first-mentioned is commoner as a symptom-complex in the entero-peritoneal form; the second in the hyperplastic variety. Appendicial symptoms are preceded in the enteroperitoneal form by symptoms of enteritis, diarrhœa, bloody stools, etc., and later the mass, with localizing symptoms of pain, tumor, etc., appears in the right iliac region. Abscesses and fistulæ form, and pulmonary tuberculosis oftentimes develops later. It will be noted how closely the symptoms in the case here reported resemble those of the typical entero-peritoneal class. The diarrhœa, bloody stools, and later developing local symptoms were all present. The history of traumatism helped to mask their importance. How much the traumatism had to do with causation of the condition is a question.

Attacks resembling sub-acute appendicitis may develop in the course of hyperplastic cæcal tuberculosis, but the symptoms in general are those of slowly developing malignant tumors, with incomplete obstruction, alternating constipation and diarrhœa, colic and digestive disturbances. A tumor is usually present, and the course of the disease is toward a fatal issue in from 2½ to 3 years.

Resection is the operation of choice in the hyperplastic form. In the enteroperitoneal form, where the peri-cæcal infiltration is

such a prominent and early lesion, resection is generally inadvisable. Simple laparotomy has resulted in a cure when the peritoneal lesions were few in number and intestinal ulceration absent. In severe cases, or when adhesions are very extensive, the operation of intestinal exclusion, unilateral, or, in the case of fistula, bilateral, performed on the cæcum, is indicated for the enteroperitoneal type.

Hartmann analyzes 229 operations for cæcal tuberculosis, with a death list of 46. Since 1900 the mortality has been but 12 per cent.

DIAGNOSIS OF RENAL DISEASE AND SUFFICIENCY.

BY BENJAMIN A. THOMAS, M.D.,

OF PHILADELPHIA,

Assistant Instructor in Surgery in the University of Pennsylvania; Assistant Surgeon in the Out-Patient Department of the University Hospital.

MODERN surgery furnishes no more striking evidence of the keen desire for increased accuracy and advancement in diagnosis and prognosis than that to be found in the laborious and persistent efforts which have been made in order to place before the profession thoroughly trustworthy methods for the estimation of renal disease and sufficiency.

Until recent years, surgeons have been content in their examination of the kidneys of patients to note the mobility, sensibility, and size of the organs, and to rely upon this, together with a more or less careful analysis of the urine, for the diagnosis of renal disease or an estimation of the renal function. Such information as may be based upon these factors alone must be somewhat variable, and in many instances positively unreliable.

It is my object within the limited scope of this article, to direct attention to the value of the routine employment of the cystoscope supplemented when indicated by ureteral catheterization for purposes of diagnosis in the symptomatology of genito-urinary diseases. Naturally, it is not only superfluous but impossible to enter into a detailed description, in a paper of this length, of the asepsis and technique demanded by cystoscopy.

It is extremely interesting to note the progress made by the indefatigable efforts to perfect renal diagnosis. The earliest attempts to catheterize the ureters were made by Axel Iversen,[1] Guyon,[2] Albarran,[3] and Harrison,[4] resorting to operative procedures of the nature of laparotomy and perineal section. Emmet[5] and Bozeman[6] accomplished the same end

by colpocystotomy. About the same time it was recommended (Hegar,[7] Sänger,[8] Warkalla,[9] Czerny[10]) to place a temporary ligature around one of the ureters from the vaginal route, while in the male sex the diseased kidney was exposed and a renal pelvic fistula established. These practices were soon condemned because too radical and serious, and led to the introduction of the clamp and compression methods of Tuchmann[11] and his contemporaries. Noteworthy advances were made by Fenwick[12] and Kelly[13] in the employment of suction, air distention and direct inspection. Of the segregators or separators the Luys[14] instrument deserves first choice and has proven itself of great value where ureteral catheterization was impossible; unfortunately in the presence of certain vesical conditions, as a medianly located ulcer or area of suppuration, any separator is manifestly useless. Although to Simon[15] and Pawlick[16] is due the honor of priority in catheterizing without intravesical illumination the ureters per urethram in women, it remained for Nitze[17] in the year 1879 to place cystoscopy, in the true sense of the word, upon a practical basis. Since that time, rapid strides have been made in this special method of technical examination, until now in many of the foremost hospitals and urological clinics of the world, it has become a routine procedure. The diagnostic advantages attending the routine use of the cystoscope are so evident, so numerous and so important that further emphasis of the merits of this most important aid in the diagnosis of urinary disorders would seem almost unnecessary.

The cystoscopes commonly employed are the direct vision cystoscope using air distention and the direct and indirect lens cystoscopes, using a transparent fluid medium. Of these methods the first has been almost entirely discarded because of the greater liability to burns, increased pain on account of heat, small size of visual field, inability to measure constantly the amount of inflation, greater danger of infection and limitation of usefulness to the female bladder. In the lens instruments direct and indirect, using always a known definite amount of sterile solution, the degree of distention of the

bladder is constant and the anatomical landmarks of the interior are invariable, the visual fields are large, clear, and distinct, there is less pain and burns are unknown. Unfortunately for the direct method the entire bladder cannot be explored, an act readily performed using the indirect illumination. Naturally, any operator will have the greatest success with that form of instrument with which he has had the greatest experience. The extensive use of the indirect lens cystoscope over other forms speaks more than words for the superiority of this instrument.

Many surgeons are inclined to regard the cystoscope as an electrical toy, possessing no distinct advantage. The routine use of this instrument in difficult renal and vesical differential diagnoses cannot be too strongly urged, and indeed in many genito-urinary clinics, cystoscopy is routinely employed. By adopting such a practice, frequently with the simple cystoscope it will be possible not only to make the differential diagnosis between diseases of the bladder and kidneys, but also by noting the conditions and certain abnormalities in and about the ureteral orifices, decide which kidney is diseased, rendering ureteral catheterization unnecessary. Illustrative of this statement, allow me to cite two cases, in the service of Dr. Chas. H. Frazier, to whom I am indebted for the privilege of these reports.

Case I.—A. L., female, aged 30, was admitted to the University Hospital, May 29, 1907, complaining of a growth in her right abdomen. The social, family and previous medical histories are entirely negative, patient being throughout her life always strong and well. Five months prior to admission she noticed some discomfort when lying on her right side, and consulted a physician who informed her that she had a "tumor." On admission patient felt well, slept well and had a good appetite, but stated that she had lost weight slightly. On the right side in the region of the kidney a large, very freely movable mass was palpable. It was not painful upon pressure and motion, not connected with the liver, and seemed to be located behind and above the colon. Urinalysis demonstrated the presence of a trace of albumen, an

occasional hyaline cast, few erythrocytes and a number of leucocytes. The count of the white blood corpuscles numbered 12,300. There was no response to the tuberculin test. Temperature fluctuated between 98° and 100°. Opinion as to diagnosis was divided between a malignant growth and pyonephrosis.

On June 10, I made a cystoscopic examination and observed a cylindrical plug of inspissated pus protruding into the bladder from the ureteral orifice of the right side, rendering the diagnosis of pyonephrosis indisputable. In Fig. 1 are seen colored drawings depicting the cystoscopic findings.

On the same day Dr. George P. Müller, exposed the kidney by Israel's incision, and found it to be about 40 cm. in length and adherent to surrounding structures. These adhesions were so firm and dense that it was impossible to deliver the kidney and nephrotomy followed by the evacuation of much thick pus and drainage was performed.

Case II.—A. C., female, aged 31, was admitted to the University Hospital, November 6, 1907, complaining of pain in left side of abdomen. Aside from the facts that she had had diphtheria, and one sister had undergone operation for tuberculous cervical lymphadenitis, the previous family and medical histories were negative. Two and one-half weeks prior to her admission patient was awakened during the night by pain in the left side of the abdomen and lumbar region which was persistent, and severe enough to "double her up," on the fourth day radiating down groin to genitalia. This was accompanied by tenderness anteriorly and posteriorly and followed by vomiting, continuing for a week, of a greenish material. No urinary symptoms were present at any time. On admission the complaint was merely a dull ache and tenderness in the left lumbar region. The abdomen was soft, and flabby, and on the left side a palpable slightly tender mass, movable with respiration, extended to within one inch of the median line. The urinalysis was essentially negative, the absence of leucocytes being especially noteworthy. Blood count showed the white blood cells to number only 11,200, and the temperature was never over 98.3–5°.

Three days after admission I made a cystoscopic examination with the expectation of catheterizing the ureters to determine the functional sufficiency of the supposedly normal kidney, in view of the contemplated nephrectomy of the diseased organ, and

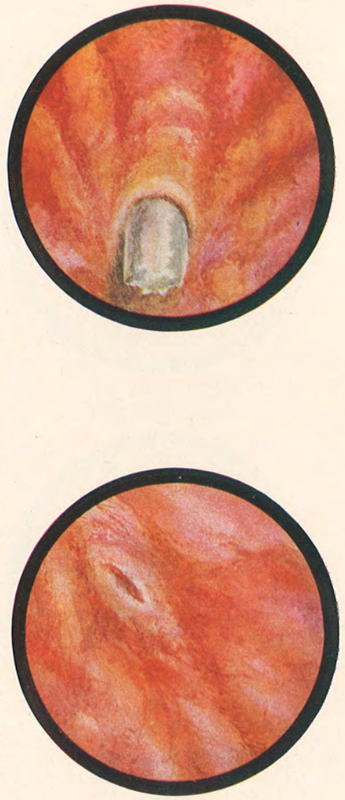

Fig. 1.

On the left is seen a ureteral pus cast, protruding into the bladder from the ureteral orifice. On the right the ureteral orifice appears normal, but as on the other side the mucous membrane is generally in a state of marked inflammation.

FIG. 2.

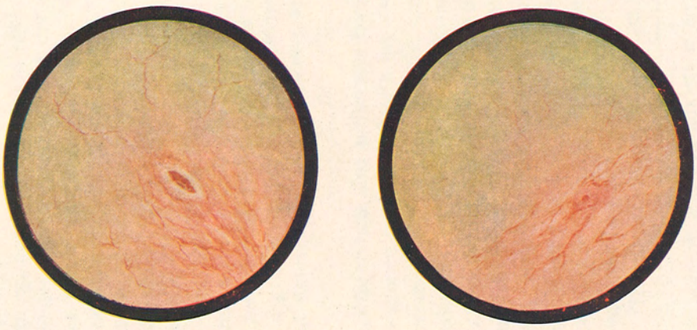

The picture on the left demonstrates a perfectly normal mucous membrane and ureteral orifice. On the right the ureteral orifice will be observed to be small, round, atrophic and functionless. This was confirmed by catheterization of the affected ureter, when no urine was obtainable.

found the left ureteral orifice to be very small, atrophic and round, instead of presenting the usual spindle-like appearance. The conditions found are well portrayed by the submitted colored drawings in Fig. 2. It was evident that the left ureter was no longer functionating, and this opinion was confirmed when no urine was collectable after catheterization of the affected ureter. In this case the simple cystoscopic findings demonstrated the uselessness of catheterizing the normal ureter to determine the functional capability of the supposedly normal kidney, inasmuch as it had already proved itself competent to care for the entire urinary excretion.

Five days later Dr. Frazier performed a nephrectomy, at which time merely a shell of kidney tissue was found, the entire kidney having been destroyed and supplanted by a suppurating sac filled with a greenish yellow pus. Laboratory examination of the pus and tissue failed to demonstrate any evidence of tuberculosis.

It is of interest to note also in this case that the cystoscope showed no evidence of cystitis, and with the absence of leucocytes in the urine, confirms the point that extensive pyonephrosis may exist in the total absence of pyuria.

In surgical operations, and especially in those connected with the urinary organs, a failure of the renal function is responsible for a certain proportion of the death-rate. Kümmell states that whereas he had six deaths from insufficiency of the second kidney in his earlier work, he has had no deaths from this cause since he has employed the modern methods of diagnosis. The consciousness of this fact is a source of anxiety to the surgeon who proposes to operate where known renal disease is present, and this anxiety is accentuated when the operation concerns some part of the urinary tract; it becomes acute when a nephrectomy is to be performed.

To-day, we are in a position, through the efforts largely of Pawlick,[16] Kelly,[18] Brown,[19] and Nitze,[17] especially the last in 1894, by dependence upon the so-called functional renal diagnosis, based upon bilateral catheterization of the ureters, to estimate the comparative function or sufficiency of one or both kidneys. It may be claimed that such men as Casper,

Kümmell, Rumpel and Zuckerkandl [22] are enthusiasts in this line of work and over-exaggerate the value to be derived from these difficult and technical procedures. However, the results obtained and to be observed in their clinics dispels any thought of doubt. Time forbids a detailed discussion of the technique and indications for the various methods entering into the determination of the functional capability of the kidneys. Suffice it to say that these, in addition to the usual physical, chemical and microscopical examinations, are *cryoscopy,* the *phloridzin test, urea determination,* the *indigo-carmin test, methylene blue test,* and the *electrical conductivity of the urine,* of which the last three are least important and generally superfluous. Many are prone to consider, on first thought, functional kidney diagnosis and cryoscopy as synonymous. Nothing, however, could be more erroneous. Cryoscopy, or the determination of the molecular concentration of the blood and urine, is merely one of the several methods of ascertaining the functional sufficiency of the kidneys. Dependence upon the results of cryoscopy alone has led naturally in many cases to grievous errors in diagnosis.

The following is the preparation and routine method of examination employed in the treatment of a given case for the determination of the renal function:

Previous to the examination, the patient is given a definite diet, namely, a breakfast consisting of 5 oz. of milk, a roll and two soft eggs. This restricted ingestion of fluids is given because of the occasional occurrence of nervous polyuria and diuretic influence of phloridzin. A thorough cystoscopic examination precedes and not infrequently renders a catheterization of the ureters unnecessary; sufficient evidence being demonstrable in the bladder to explain the symptomatology.

After thoroughly irrigating the bladder, always under the most aseptic precautions, both ureters are catheterized employing the double-barreled ureteral cystoscope. The first few drops of urine should not be saved, owing to the fact that the end of the catheter may have taken up pus cells or other matter from the content of the bladder during its passage through the same; or

because of trauma and diapedesis at the time of manipulation, a few red cells may have found their way through the eye of the catheter. After one to three c.c. of urine have been collected in tubes, carefully designated *right* and *left* to avoid confusion, these are replaced by two others. If the urine is now dropping from both catheters, desirably *one centigramme* of phloridzin is injected intramuscularly. At the end of 15 to 20 minutes two more tubes are substituted and a few additional c.c. of urine collected. We now have six tubes containing urine. The first pair serve for the microscopic examination; the second pair for the determination of the freezing point and urea; the third pair for the estimation of the artificially produced sugar.

Cryoscopy of the blood, on which formerly so much stress was laid, is falling into disrepute as a valuable diagnostical aid, although Kümmell and Rumpel still attach no little importance to this procedure in urinary surgery. But even they no longer assert a lowering of the freezing point of the blood to —0.60° to be the limit for nephrectomy. Albarran,[20] Casper,[21] Israel,[25] Senator [23] and Koranyi [24] are all unanimous in the following conclusions:

1. The lowering of the Δ of the blood to —0.60° and beyond may be independent of any renal lesion. Kümmell and Rumpel themselves recognize the possibility of this happening in various circumstances; in lost cardiac compensation, anæmia, diabetes, eclampsia, epileptic attacks and in large intra-abdominal tumors. In all these cases accumulation of carbonic acid in the blood from respiratory insufficiency may determine the lowering of the Δ of the blood.

2. The normal Δ of the blood —0.56° does not indicate that the renal function is insufficient.

3. When the kidney is diseased the Δ of the blood may be —0.60°. Great molecular concentration of the blood has been observed in cases of unilateral hydro- and pyonephrosis, cancer of the kidney and even in renal colic.

4. When the two kidneys are diseased, the Δ of the blood may be normal. A single kidney is sufficient to maintain the normal degree of concentration of the blood, and this work

may, perhaps, be performed by the parts of the parenchyma of each kidney that are still intact. Each of those kidneys considered alone would be insufficient.

Albarran [20] and others believe that the study of the molecular concentration of the blood is only of practical interest in exceptional cases. When the Δ of the blood is below —0.58° or —0.60°, it may raise a suspicion of a bilateral lesion, but in the greater number of cases, we can arrive at a precise diagnosis by other methods, and notably by analysis of the separate, simultaneously collected urines of the two kidneys. When from any reason it is impossible to study separately the urines of the two kidneys, the investigation of the blood has a real interest. Upon the two repeatedly demonstrated hypotheses that, *normally, both kidneys, at a given time, excrete identical urines, and that sugar is normally equally excreted by both kidneys after "phloridzin" injection, are founded the beliefs of the advocates of modern kidney diagnosis.* This naturally necessitates the synchronous bilateral catheterization of the ureters for the collection of urine over a given period of time. According to Casper [21] this is the all-important point, and it is only by a comparative study of the simultaneously catheterized specimens of urine that an indisputable judgment can be formed as to the sufficiency or insufficiency of the corresponding kidneys. On the other hand, there are some, including Israel,[25] Kapsammer [27] and Albarran [20] who deny that the composition of the urines of the two healthy kidneys at a given time is identical. Their objection, however, is vastly overweighed by the positive assertions of Casper,[21] Richter,[26] Zuckerkandl,[22] Friedrich Strauss,[28] Fedorow,[29] Bardier,[30] Frenkel [31] and others. Many errors have arisen because of the attachment of too much importance to very small differences. Again, there has been a tendency just as is so often the case in other conditions, medical and surgical, to seek for some sign or test disregarding all the associated diagnostical aids and procedures, and to make functional renal diagnosis bear the entire brunt of the burden, whereas it is, and only should be, a link in the chain of diagnostic evidence.

In order to illustrate forcibly the great value of modern renal diagnostical methods relative to the estimation of renal sufficiency, allow me to record the following cases:

Case III.—M. H., female, aged 39, was admitted to Dr. Frazier's service at the University Hospital on October 16, 1906, complaining of dysuria with frequency and urgency of urination and some tenderness in hypogastric and appendiceal regions. Although she has never been of robust development, the family and previous medical histories were negative save that one sister died of tuberculosis, and that for the past eight years there has been occasional frequency of urination and an attack of "malarial fever" of three weeks duration during the previous summer. On admission patient had the above subjective complaints, at times associated with a heavy pulling sensation and some tenderness in the right flank, just beneath the costal margin. Recently, leucorrhœa following urination and loss of weight have occurred. In the right flank, extending about two inches below the costal arch, is a firm, smooth, readily palpable mass, very slightly movable and only moderately tender on manipulation. Temperature did not fluctuate and never rose over 98°. Leucocytic count numbered 4,560. Urinalysis of catheterized specimen demonstrated presence of albumen and a large quantity of pus containing the bacillus tuberculosis.

Two days after admission I catheterized the left ureter using the Kelly instrument to determine the functional condition of the left kidney. During this procedure large quantities of pus were observed to flow from the right ureteral orifice. The urine collected from the right side upon analysis proved to be normal and was productive of no lesions upon inoculations into guinea pigs, conducive therefore to a favorable prognosis following nephrectomy.

Shortly afterward Dr. Frazier performed nephrectomy and ureterectomy of the affected side, and a kidney the seat of advanced tuberculosis both macroscopically and microscopically was removed.

Case IV.—Male, 34 years; family history negative; in early life frequently had cervical lymphadenitis; syphilis ten years previously; nephritis two years ago. No pains although almost continuous hematuria; never colic or tenesumus. Patient was

very well nourished; no fever; liver palpable; lungs showed no demonstrable lesions; abdomen not tender. In left hypochondrium an indistinct resistance, not tender to palpation was recognizable. Urine: cloudy, bloody, albumen positive, no sugar, sediment demonstrated blood and pus, no casts, no tubercle bacilli. Urination painless but every three to four hours; more frequently by night.

Cystoscopy showed a bullous œdema of mucous membrane about neck of bladder, and in places the mucous membrane was studded with slightly elevated yellowish nodules. Ureteral orifices presented no especial changes.

Functional Examination by Ureteral Catheterization:—

	Right.	Left.
Appearance	Clear	Cloudy
Amount	13 c.c.	12 c.c.
Sp. g.	1.026	1.010
Δ	1.64	0.43
U	2.0	0.2
Sac.	2.4	0.2
Alb.	0	Moderate
Sed.	—	Pus and red cells

A glance at the comparative determinations of freezing points, urea, sugar, albumen, and characters of sediment, reveals the unmistakable functional sufficiency of the right kidney. Nephrectomy of left kidney demonstrated a *nephrolithiasis* with *pyonephrosis*.

Case V.—Male, aged 60, in childhood had inflammation of the lungs. About a year ago experienced pain in left side following spring over ditch. Four days later had hematuria of short duration without pain. Sometime later, again hematuria, this time with pain in left side. Recently patient had lost weight (28 lbs.). Never fever, colic, or passage of stones. Abdomen soft. Right kidney palpable. Under left costal arch, distinct ballottement of a tumor extending from mammillary line to umbilicus; movable with respiration, smooth and tender on pressure. Lateral position rendered the findings of palpation more distinct. Urine: cloudy, sediment contained pus, no casts, but a few R.B.C., small amount of albumen, no sugar.

Cystoscopy revealed a normal bladder, save a slight trabecular hypertrophy and minute blood coagula.

Functional Examination by Ureteral Catheterization:—

	Right.	Left.
Sp. g.	1.020	1.010
Δ	1.29	0.92
U	1.8	1.1
Sac.	0.6	0.05
Sed.	—	Pus; red cells
Alb.	—	Moderate

Here again the importance in the estimation of the functional integrity of the right kidney is manifest. Nephrectomy revealed a *hypernephroma* of the left side and the patient passed through an uninterrupted convalescence.

Although urological surgery has not attained to the full development of its possibilities, and although few noteworthy advances may have been made during the past decade, as claimed by the opponents of functional renal diagnosis, nevertheless concensus of opinion indicates that important strides have been made and still greater ones are destined to occur along the line of functional kidney diagnosis.

BIBLIOGRAPHY.

[1] Axel Iversen. Beitrag zur Katheterisation der Ureteren beim Manne-Zentralbl. f. Chir, 1888, No. 16.

[2] Guyon. Cathéterisme des urétèrs. Annal. des malad. des org. gén. urin., 1891, p. 744.

[3] Albarran. Cathéterisme permanent des urétèrs. Annal. des malad. des org. gén. urin., 1891.

[4] Harrison. Lectures of the Surgical Disorders of the Urinary Organs. London, 1887.

[5] Emmet. New York Medical Journal, 1884.

[6] Bozeman. Renal Tenesmus, a Result of Chronic Cystitis and Ureteritis; Successful Treatment by Colpo-uretero-cystotomy, etc. N. Y. Med. Jour., 1888, August.

[7] Hegar. Kaltenbach-Operative Gynäkologie, 1 Aufl., p. 456.

[8] Sänger. Über Tastung der Harnleiter beim Weibe. Archiv. fur Gynäk., 1886, xxviii, p. 54.

[9] Warkalla. Über Absperrung der Harnleiter von der Scheide her zu diagnostischen Zwecken. Archiv. f. Gynäk., xxix.

[10] Braun. Über Nierenexstirpation (Klinik Czerny). Deut. med. Wochen., 1881, No. 31–33.

[11] Tuchmann. Die diagnose der Blasen und Nierenkrankheiten mittels des Harnleiterpinzette, Berlin, 1887.

[12] Fenwick. Suction of the Male Ureters. Lancet, 1886.

[13] Kelly. Catheterization of the Ureters. Annal. of Gynæk. und Pædiatrics, 1893, vi. Bull. Johns Hopkins Hosp., 1893, No. 35.
[14] Luys. La séparation de l'urine des deux reins. Gaz. hebdom de méd. et de chir., 1902, 11 Dez.
[15] Simon. Volkmanns Sammlung klin. Vorträge, 1875, No. 88.
[16] Pawlick. Suction of the Male Ureters. Lancet, 1886, Sept. 18, and Archiv. f. klin. Chir., 1888, Bd. 33.
[17] Nitze. Diagnostisches Lexikon, Wein, 1894.
[18] Kelly. Amer. Jour. of Obst., Jan., 1894.
[19] Brown. Bulletin of the Johns Hopkins Hosp. Balt., Sept., 1893.
[20] Albarran. Annales des maladies génitourinaires, 1899.
[21] Casper. Handbuch der cystoskopie, 2 Auflage, 1905.
[22] Zuckerkandl. Handbuch der Urologie, 1904.
[23] Senator. Deut. med. Wochen, 1900, No. 3.
[24] Koranyi. Berliner klin. Woch., 1899.
[25] Israel. Berliner klin. Woch, 1899.
[26] Richter. Diskussion in der Berliner med. Gesellschaft, des. 14, 1898.
[27] Kapsammer. Quoted by Casper (see 21).
[28] Strauss. Quoted by Casper (see 21).
[29] Fedorow. Quoted by Casper (see 21).
[30] Bardier. Quoted by Casper (see 21).
[31] Frenkel. Quoted by Casper (see 21).

Dr. John H. Gibbon asked if Dr. Thomas could tell how many cases there have been of infection of the primarily healthy kidney from ureteral catheterization. It was his opinion that there was a certain amount of danger. For instance in the case of a patient with a tuberculous kidney with secondary involvement of the bladder there would be a certain amount of danger in carrying the infection into the well ureter unless the greatest care was exercised in cleansing the bladder thoroughly and in manipulating the catheter. Dr. Gibbon believes that the indiscriminate and careless use of ureteral catheters may result in injury of a perfectly healthy ureter and its corresponding kidney. He considers this a method of diagnosis which is of undoubted value, but it is only one means, and he thinks that if a diagnosis can be arrived at by means of a cystoscopic examination of the ureteral openings, as was done in two of the reported cases, it is better, especially in the presence of a bladder infection.

Dr. Gibbon referred to a case of a physician who had blood and pus in his urine, frequent micturition; he had no abdominal symptoms, no tumor or tenderness over the kidney, but he gave a history of having what he thought was an attack of appendicitis, which passed off. This attracted Dr. Gibbon's attention to the right kidney; he used a cystoscope on his patient with very little

satisfaction, which he thought was due to the presence of blood. He then did a suprapubic cystotomy and found a large ulcerated area involving the right ureteral opening. The other ureteral opening was apparently normal. The bladder wound was healed in less than two weeks, and Dr. Gibbon then exposed the left kidney in order to determine its condition, as has been recommended by Leonard Freeman. This required only about ten minutes, and demonstrated a perfectly normal kidney. The right kidney, which was the seat of an extensive tuberculosis, was then removed. Within 48 hours after the removal of the kidney the patient could hold his urine for quite a little time, much longer than before the operation. He made a prompt recovery and before he left the hospital had to empty his bladder only once at night. At the present time the bladder function is perfectly normal, and the patient has resumed active practice.

Dr. Gibbon also referred to ureteral catheterization in cases of ureteral calculi. He recalled two instances where the ureters had been catheterized by experienced men, and in which no ureteral stone could be definitely located. In one of these cases Dr. Gibbon removed a stone 18 months after catheterization, and in the other 6 months after catheterization. He believes that in these cases the X-rays are of far more value than ureteral exploration. Probably in the hands of an experienced man the use of the wax-tipped catheter might be relied upon in such cases.

Dr. B. A. Thomas replied that personally he had never seen a case of infection that could be ascribed to catheterization of the ureters. A couple of years ago he had an opportunity to visit Zuckerkandl in Vienna, where a great deal of work is being done along this line, and he took the opportunity to ask him whether he had ever seen a case, and much to Dr. Thomas' surprise Zuckerkandl replied in the negative. Dr. Thomas had expected that occasionally some such condition might arise. He thinks the danger can be reduced to such a minimum by thorough irrigation of the bladder with a sterile solution and thorough asepsis in instrumentation, that it is hardly worthy of consideration.

With reference to ureteral calculus Dr. Thomas said he thought that the catheterization of the ureters is probably not of so much value in the determination of this condition as the employment of various so-called chromo-cystoscopies, or the employment of the X-ray.