

### STATED MEETING HELD JUNE 4, 1906.

The Vice-President, ROBERT G. LE CONTE, M.D., in the Chair.

#### GENERAL PURULENT PERITONITIS.

DR. GEORGE G. ROSS reported eight cases of generalized peritonitis, as follows:

CASE I.—Miss Alice H., aged twenty-one, was admitted to the German Hospital, August 18, 1905, with the history that for twenty-four hours before admission she had suffered with severe abdominal cramps, starting in the right iliac fossa, later becoming general, and accompanied with nausea and vomiting; bowels open. On admission, her abdomen was distended and moderately rigid. There was general abdominal tenderness, with the greatest intensity over the appendix region. By the following day, the distention, rigidity, and tenderness were markedly lessened, the bowels had moved, and flatus was passed freely. On the second day, the symptoms had become localized to the right iliac fossa, and on the following day, the third after admission, she was operated. The leucocyte count on the day of admission was 16,200; and on the day of operation, 14,800.

On opening the peritoneum, a thin, blood-streaked pus was found to the outer side of the cæcum and in the pelvis. The abscess cavity was not confined, however, to these localities; as there was infection of the greater part of the general peritoneal cavity.

No attempt was made to remove the appendix. She was thoroughly drained by a glass tube in the pelvis, a rubber tube in the loin, and gauze wicks. She lived sixteen days. On the fifteenth day, the leucocyte count showed 13,400. On the day of her death, she expectorated a large quantity of fetid pus.

Post-Mortem Report.—Plastic peritonitis about the site of the appendix; a large abscess between the right lobe of the liver and the diaphragm, which had ruptured into the right pleural cavity, and thence into the right lung. The pathological diagnosis was septic bronchopneumonia.

CASE II.—Miss Annie C., twenty years of age, was admitted

to the German Hospital September 27, 1905, with an acute attack of appendicitis of twenty-four hours' duration. There was some general distention and tenderness. The point of greatest tenderness was over the right iliac fossa, extending outward to the crest of the ilium. Vomiting and pain were severe and persistent. The leucocyte count was 24,800.

Operation was performed on the day of admission. On opening the peritoneum, free pus escaped. The peritoneal cavity was walled off with gauze-pads, in the hope that the peritonitis was diffused, but not general. When the gauze was removed it was saturated with pus, proving that the general cavity had been invaded. The appendix was removed, and the peritoneal cavity drained with a glass tube in the pelvis and three pieces of gauze. It was not irrigated. Fowler's position and rectal transfusion were used. There was an uninterrupted recovery.

CASE III.—Mrs. Ida A., twenty-eight years of age, was admitted to the German Hospital August 12, 1905, with an attack of acute appendicitis that had begun three days before, but had become severe only the day before admission. The abdomen was distended, tender, and rigid, the tenderness being exquisite over the right iliac fossa, and the rigidity most marked in the lower quadrant of the abdominal walls. There was no palpable mass. The leucocytes amounted to 5,650.

Operation was performed on the day of admission. An incision was made through the right rectus. There was free pus in the peritoneal cavity, in large quantity. The appendix was removed, and found to have perforated, liberating a fecal concretion and pus. The peritoneal cavity was thoroughly washed with sterile salt-solution, and glass drainage was introduced into the pelvis. A counter opening, to the outer side of the rectum, was made for gauze drainage to the bed of the appendix. Fowler's position was used, together with salt-solution by the bowels, every four hours, a pint being used each time. The patient made an uninterrupted recovery.

CASE IV.—Mr. K., twenty-six years of age, was admitted to the German Hospital August 17, 1906. He had been sick two days with an acute attack of appendicitis exhibiting the classical symptoms and signs.

On admission, his abdomen was moderately distended, with



bilateral rigidity and tenderness—most marked, however, over the appendix. On the following day, the abdomen had become softer and less distended, and a mass could be mapped out toward the right iliac crest. The leucocyte count was 16,100. The man was operated upon on the fourth day after admission.

The peritoneal cavity, which was infected, was packed with gauze. A localized abscess to the outer side of the cæcum was opened. The appendix, which was gangrenous, had perforated, liberating three concretions. It occupied a position behind the cæcum, running upward toward the liver. It was removed. There was about 250 c.c. of foul-smelling pus in the pelvis, yellowish-white in appearance, and thin in consistency. Drainage was secured with a glass tube and gauze.

The patient lived but twenty-four hours after the operation, profound and continuous sepsis being the cause of death. The postmortem showed a secondary abscess beneath the liver, and fibrinopurulent peritonitis.

CASE V.—Miss A. B., twenty-four years of age, was admitted to the German Hospital August 29, 1905. She had been ill for five days. The attack began with pain in the right iliac fossa, becoming general. Vomiting began on the third day of the attack. The bowels moved freely.

On admission, her abdomen was moderately distended and rigid. There was dulness on each side below the umbilicus. The flanks were tympanitic and very tender, the greatest tenderness being over McBurney's point. The leucocyte count was 24,000.

The patient was operated upon on the day of admission. On opening the peritoneum, about 750 c.c. of yellowish-gray pus escaped. The intestines were injected, and in places covered with plastic exudate. The appendix was perforated one centimeter from its base. Through this perforation a fecal concretion, pus, and fecal matter had escaped. The pelvis was full of pus.

The pelvis was drained with a glass tube and gauze, four pieces being used. The following day, the woman's temperature was 99.4°; pulse, 116; abdomen, soft. The bowels were moved in forty-eight hours, and gas passed freely. The patient was discharged one month after the operation, with a granulating wound of the abdomen.

CASE VI.—Llewellyn B., sixteen years of age, was admitted to the Germantown Hospital January 18, 1906, complaining of

pain in the right iliac region. The attack had come on twelve days before, with some pain and vomiting. The patient felt better after this, but was not entirely well; although he went to school regularly. Tuesday night, two days before admission, he had a second attack of pain and vomiting. A nearby physician made a diagnosis of indigestion and gave some peppermint preparation. The next day the patient went to school.

The same day, the regular family physician was called, and found the boy suffering but little. The abdomen was soft; the temperature was but slightly elevated; and there was some pain in the appendiceal region. The diagnosis of probable appendicitis was made. Salts were given in repeated doses; and the parents were instructed to notify the physician at once, if the patient showed any symptoms of getting worse. At ten o'clock the patient vomited; but he slept the greater part of the night, according to the statement of his father, who did not consider him very sick. He tossed about some, but this was thought to be due to the salts.

Early on Thursday, the family physician saw the patient again, and a diagnosis of appendicitis was made.

The boy was admitted to the Germantown Hospital the same day. On admission, he complained of pain in the right iliac region, but he could not definitely put his hand upon the spot. The rectus was rigid; tongue, slightly coated; mental condition, dull. He was slow to answer questions, and was apparently somewhat excited by the examination. He did not know about his bowel-movements lately, but told about his attending school.

Immediate operation was advised. A lateral incision was made through the right semilunar line. Pus oozed from the wound. The area was thoroughly packed in every direction with large gauze sponges. The omentum was tied down in the region of the appendix; the lowered end was thickened, and a dark mass of it was found surrounding the appendix. This was tied off and amputated. The appendix on being lifted up, was found to be perforated and dark. Out of the perforation rolled a large concretion. The appendix was ligated and removed; and the stump was inverted and closed over with Lembert sutures. Removal of the gauze pads showed creamy pus in every direction. A glass tube, packed around with iodoform-gauze, was placed



in the pelvis. A rubber tube was inserted through a lumbar incision to drain the region of the stump. Three pieces of iodoform-gauze were placed to drain the abdomen; and a fourth piece was used as a cofferdam. Morphin sulphate was given before the patient came out of the ether.

The patient was discharged February 17, with a strip of gauze in the lumbar wound. The fascia was brought together with sutures two weeks before discharge.

CASE VII.—Robert A., twenty-six years of age, was admitted to the Germantown Hospital October 16, 1905, service of Dr. A. D. Whiting, complaining of pain in the lower abdomen, which was tense, rigid, and tender to palpation. Rectal examination showed a fluctuating mass in the right side of the pelvis.

The patient was etherized. A small incision was made through the right rectus. In the right side of the pelvis was an immense abscess, containing a large quantity of greenish-yellow, foul-smelling pus. This was allowed to run out; and the cavity was then sponged and irrigated with normal salt-solution. The appendix was not removed. A glass drainage-tube was inserted into the pelvis. Iodoform drains were placed at the side of the tube, running into the pus-cavity. The patient recovered from the attack, and was sent home.

He was readmitted March 6, 1906, service of author, for appendiceal abscess with intestinal obstruction; pulse 104, respirations 28, and temperature 99.6°. There was severe aching pain in the lower abdomen, which had lasted three or four days, during which time the patient had had no bowel-movements, notwithstanding that purgatives in heroic doses had been given him. The pulse, temperature, and respiration remained normal until after the operation. The abdomen was distended, and had a saggy, doughy feel. There was very slight tenderness in the lower abdomen. The patient had vomited several times but there was no fecal vomiting. The general condition, with the history, was strikingly suggestive of obstruction of the bowel; and the patient was operated on, March 7, for that condition.

An incision was made, cutting out the scar of the previous operation. Numerous adhesions, binding the bowel down, were found. These were broken loose, and in doing so an abscess was found in the right pelvis. This was opened and drained, pus flowing freely. The general peritoneal cavity was involved in

the infectious process, giving rise to the obstructive symptoms. Four strips of iodoform-gauze were left in as drains, and pushed up toward the liver and spleen; and others, into the right and left pelvis, respectively. A glass drainage-tube was pushed to the bottom of the pelvis. The patient made a satisfactory recovery, after a prolonged convalescence.

CASE VIII.—M. W. was admitted to the Germantown Hospital on February 12, 1906, evidently in the second week of typhoid fever. His previous history is of no importance. Twelve days after admission he complained of a sudden severe, cutting pain in the abdomen, in the region of the appendix. The right rectus was rigid, there was tenderness, and the patient was sweating profusely. The pulse jumped from 98 to 104; the respirations, from 24 to 34. The temperature dropped from 101° to 99.6°.

Operation was performed seven hours after perforation had occurred. The perforation was six inches from the cæcal junction, completely sealed off by omental graft. There was diffused peritonitis. A glass tube and gauze drainage were inserted. The tube was removed in five days, and was replaced by a rubber tube. Fecal fistula occurred on the seventh day. Diarrhoea was the only bad symptom. Death occurred on the 26th, and was preceded by abdominal pain and tenderness, but no vomiting. The temperature rose to 108°; the pulse was uncountable. Perforation took place through the original opening, which had been closed by omental graft. The gut around the opening was gangrenous, as was the gut in touch with the area of the drainage-tube. The peritoneum of the pelvic walls and the parietal peritoneum were gangrenous. General peritonitis was present, and death took place fourteen days after the operation.

DR. ROSS, remarking upon these cases, said that it is evident that general purulent peritonitis is not necessarily fatal. Murphy claims thirty-three cases of perforative peritonitis with one death. The statistics of other operators show various rates, from 50 per cent. to 70 per cent. of recoveries. In this short series, two out of seven cases due to appendicitis died—a death-rate of about 30 per cent.

The outcome of a case of general purulent peritonitis depends on the character of the infection, the quantity of the infection, and the area involved, rather than on the treatment



instituted; although this treatment is a necessary adjunct to recovery in the majority of cases.

Operation should be performed early, and should be minimized to essentials,—*i.e.*, the abdomen should be opened rapidly, the focus of infection at once located and removed, the cavity of the pelvis and the area of original infection thoroughly and rapidly drained, and the wound dressed. The average time for these maneuvers should not exceed ten minutes. Time and the amount of anæsthetic are of great importance. These cases do not stand prolonged anæsthesia and handling of the viscera.

These are some cases in which irrigation is indicated—the cases of late operation, when the pus is thick and creamy. When irrigation is used, it should be thorough. His method was to place one hand in the cavity of the peritoneum, and have an assistant pour salt-solution from a pitcher as fast as it will run into the incision. The hand in the cavity is constantly working and agitating gently the abdominal viscera. This requires an extra five minutes, but is justifiable in these circumstances.

Fowler's position; rectal transfusion, continuous or periodical; and morphin, are important adjuncts to the treatment after operation.

The class of appendix cases most to be dreaded are those in which the organ occupies a retrocæcal position, toward the outer side and behind the cæcum, with the tip of the organ in proximity to the liver. These are the cases that die of sepsis. They develop symptoms early; the symptoms of general infection are severe, rapid, and out of all proportion to the local signs; the organ is so deeply placed that the signs are obscured; and drainage and removal of the appendix does not seem to reach the avenue by which the infection is traveling toward the liver. Even drainage of the retroperitoneal space does not prove satisfactory in all cases.

DR. FRANCIS T. STEWART, although he agreed with Murphy, Le Conte, and others regarding the principles of the so-called Murphy treatment of general peritonitis, in his own experience results before its adoption were just as good as those since it has been employed. Such results may, however, be accidental and not to be attributed entirely to treatment.

DR. ROBERT G. LE CONTE differed with Dr. Stewart as to the value of the Murphy treatment. He (Le Conte) has had a small

series of cases of general peritonitis and has obtained a vastly better percentage of recoveries since adopting the Murphy treatment, the increase being 50 per cent. or greater. In the previous cases he did not employ any one method. Sometimes he irrigated, sometimes he sponged, and consequently the treatment varied. Formerly his mortality at the Pennsylvania Hospital was 70 to 80 per cent. His results now are not so good as those of Murphy but they are at least twice as good as they were previously. Whether or not this showing is accidental he cannot say. He is not prepared to state positively, but he believes the results are due to the treatment. The rationale of the method appeals to him very strongly, and he regards Murphy's method as the ideal way to treat cases of diffuse septic peritonitis.

DR. ROSS agreed with Dr. Le Conte as to the value of the Murphy treatment; it is founded on good surgical principles. It is true that of his seven cases he irrigated two and both recovered, but in them the character of the pus was different. It was thick and creamy, like that found in ulcers. Such cases are not to be feared as are those with thin, blood-streaked pus. The character of the infection is consequently of great importance in cases of peritonitis. In a class of cases mentioned, namely those with the appendix posteriorly and high up, the circulation carries the infection through the liver and the mortality is very high; no method of treatment can save most of these cases. When Dr. Ross is operating and sees free pus he at once puts in ten or twelve gauze pads around the site. These absorb pus while he is removing the appendix and thus save time by withdrawing the pus when later they are taken out.

#### CONGENITAL FISTULA IN TONGUE.

DR. GEORGE G. ROSS exhibited a man who since birth has had a fistula two inches deep in the median line of the tongue. From this can be pressed pus-like material containing no epithelial cells nor special bacteria. The cavity holds two drachms of pus. It has been suggested by Dr. Jopson that the condition is one of lingual fistula due to the congenital presence of thyroid tissue at the base of the tongue.

DR. ROBERT G. LE CONTE thought the condition to be one of congenital thyroglossal duct and that misplaced thyroid tissue may be at the end of the sinus. His procedure would be



to inject the fistula with colored fluid and then dissect toward it from the submental region until the sinus is reached. This can be followed to its base and the entire affected area removed. Within the past six weeks Dr. Le Conte has seen at the Pennsylvania Hospital a case of different origin but of somewhat similar character. It was a case of complete, branchial fistula. The external opening was at the anterior border of the right sternocleidomastoid muscle and the internal at the posterior part of the right tonsil. The case was treated by injecting the sinus with methyl blue through the skin opening, which was about the size of a hypodermic needle. The sinus was dissected out parallel to the sternomastoid muscle and the duct ligated one-fourth inch from the mucous membrane of the pharynx. Two weeks after the operation the patient was again seen; the wound had healed, and there was no sign of a return of the condition. Dr. McCoy examined the throat of the patient before the operation to see if the internal opening could be detected; the mirror failed to reveal it. That the fistula was complete, however, was shown by the fact that material passed through it when the child swallowed.

NORMAL PYLORUS SEVEN YEARS AFTER A SIMPLE PYLOROPLASTY FOR STRICTURE.

DR. JOHN B. ROBERTS reported the case of a man fifty-five years of age who was admitted to the Polyclinic Hospital on February 27, 1899, complaining of gastric symptoms for fifteen or eighteen years. He had pain after eating, which continued until the stomach was emptied by vomiting. He was weak, emaciated and anæmic. Investigation of the stomach by lavage and other clinical methods caused a diagnosis of stricture of the pylorus with gastric dilatation to be made. On April 4, 1899, Dr. Roberts did an ordinary pyloroplasty by making a horizontal incision through the pylorus and uniting the wound in a vertical direction. There was no tumor of the pylorus and the condition was considered to be a fibrous contraction. The patient immediately had relief from the pain and vomiting and gained greatly in weight. He was discharged cured about six weeks after operation.

During the next six years he consulted the reporter on two occasions complaining of some gastric distress, which was attributed to a recurrence of the contraction, and it was suggested that he return for investigation, treatment and probable repe-

tition of the operation. After each of these conferences, he, however, disappeared from view. He was a man of limited intelligence.

In April, 1906, he entered the Polyclinic Hospital for the relief of dysuria, under the care of Dr. F. T. Stewart. At the Hospital he complained of no gastric trouble and was able to eat and digest even meat. Dr. Stewart found a mass in the pelvis, which interfered with the voiding of urine, and made an exploratory abdominal incision on May 18. He found a mass, probably carcinomatous, involving the rectum, sigmoid colon and bladder, which was inoperable. The patient died two days later unexpectedly, probably from uræmia.

At the autopsy there were found a few old adhesions between the old celiotomy wound and the anterior wall of the stomach. The adhesions were in some parts quite dense, though most of them were easily broken up. The pylorus, according to Dr. John M. Swan, the pathologist, showed no sign of the former operation, except that the pyloric ring was not as distinct as usual. There was no thickening in this region and the pylorus admitted several fingers. There was some evidence of chronic gastritis with moderate dilatation. The specimen was not preserved for presentation with this report.

Dr. Roberts said that he presented this report to the Academy because it seemed to him to be interesting to have an opportunity to examine a simple pyloroplasty seven years after operation and to find that the mechanical effect of the operation continued to be all that was desired. There has been some discussion as to the value of this procedure, but, in the case under consideration, it certainly was the means of saving the patient's life. It is possible that the condition, for which the operation was done, was a spasm of the pylorus rather than a fibrous contraction. The latter condition was the lesion however which he believed to be present at the time he examined the pylorus and operated upon it.

DR. CHARLES F. NASSAU gave the detail of a similar operation he performed five years ago. The patient was a woman who suffered from constant vomiting until she had become markedly emaciated. She was in the Presbyterian Hospital for six weeks, where she was seen by Dr. Hughes. She grew progressively worse, the vomiting being uncontrollable by any method of treat-



ment, and rectal feeding became necessary. No mass was felt in the abdomen and repeated stomach examinations were practically negative. Finally Dr. Hughes thought he felt nodular thickening along the right ureter, though there were no symptoms referable to the kidney. Exploratory laparotomy was performed and no explanation for the condition of the patient was at first found. A peculiar condition of the small intestine was that every three or four inches were fecal balls. These were not scybalous, being easily indented, and between them the intestine was collapsed, giving it a bead-like appearance. The little finger could not be passed through the pylorus and the operation as described by Dr. Roberts was performed. After a stormy convalescence the patient improved very greatly, gaining twenty-five pounds in a relatively short time. Her present condition is good. At certain times if she hurries after a meal she vomits, but she is in very good health for a nervous woman. In the absence of over-exertion the stomach functionates satisfactorily. It is difficult to say what the real condition in this case was, but relief by operation was fully demonstrated. This operation gives a mortality far lower than that of gastro-enterostomy, particularly when there is no dilatation of the stomach to justify the latter procedure.

#### PERITONEAL EFFUSIONS RESEMBLING BILE IN COLOR.

DR. GWYLYM G. DAVIS said that four cases had recently come under his notice bearing on the question of the origin and character of wound and peritoneal effusions resembling bile in color.

The first case occurred in a man about twenty-eight years of age while under treatment for gonorrhœal arthritis of the knee in a chronic stage. He was suddenly seized with severe pain in the abdomen about twenty-four hours before Dr. Davis saw him. It became rapidly worse and when seen by the reporter his abdomen was distended, evident peritonitis, slightly more tender at McBurney's point than elsewhere, but with no mass or dulness to indicate that the trouble was mainly at that point. Through a transverse incision over the appendix it was found to be somewhat hardened and injected, but not gangrenous nor perforated and apparently not sufficiently diseased to be the cause of such a widespread peritonitis. There was a

large amount of dark, grumous peritoneal fluid and only a slight amount of lymph, but the sponges used (gauze) were stained by the fluid a golden yellow color. Thinking this color might be due to bile, after removing the appendix, the wound was closed and another made over the gall-bladder along the edge of the ribs. The gall-bladder was found bathed in the same dark effusion but healthy. The incision was then prolonged toward the median line and the anterior wall of the stomach examined, with a negative result. An opening was then made through the gastrocolic omentum and the posterior wall of the stomach and pancreas, with the cavity of the lesser omentum, were explored, but nothing was found. The wounds were closed and the patient made a perfect recovery and was soon as well as ever.

The second case was in a young boy with a compound separation of the lower epiphysis of the femur. Several days after the injury the white gauze dressings showed the same golden yellow color as in the first case. He progressed favorably.

The third case was in a man about fifty years old who was brought to the hospital almost *in extremis* with diffuse general peritonitis. An examination showed an injected appendix otherwise apparently healthy. Purulent lymph through the intestines and a large amount of grumous, dark, peritoneal effusion staining the gauze sponges golden yellow. A hasty examination of the gall-bladder showed it to contain bile and it had a patch of purulent lymph on it. It was not at all thickened by inflammatory action but entirely normal in consistency. The stomach was normal. Both wounds were drained but the man died some hours later.

The questions arise as to what causes the peritonitis and why was the effusion golden yellow in color? In the first case the appendix was almost certainly the cause of the disease, as its removal and cleansing of the abdomen cured him. In the third case either the appendix or gall-bladder could be possible causes but neither was perforated; and it seemed more likely that here again the appendix was the primary focus. The pancreas was not the source in either case. Both cases lead one to think that the most virulent types of peritonitis can be produced by a diseased appendix with no adhesions, no perforation, and only showing a slight injection.



As regards the peculiar color of the effusion it was due to disorganization of the coloring matter of the blood. That it was not due to bile in the first case was shown by its absence being demonstrated by a chemical examination of the effusion. In the second case, as it was one of compound separation of the epiphysis of the femur, it was evident that bile could have had nothing to do with it. In the third case the gall-bladder was found to contain bile which did not exude through any perforation of its walls when subjected to pressure, hence it was probably not the source of the bile-colored effusion.

These facts should teach us to be chary about attributing to effusions which stain gauze sponges a golden yellow color a biliary origin.

In a case recently of rupture of the liver, as soon as the abdomen was opened black liquid and clotted blood poured out; when this was rapidly cleansed away the intestines were seen stained over a large area a dirty yellowish-brown color. They were positively stained and not, as in the former cases, of a red color and bathed in a dirty liquid.

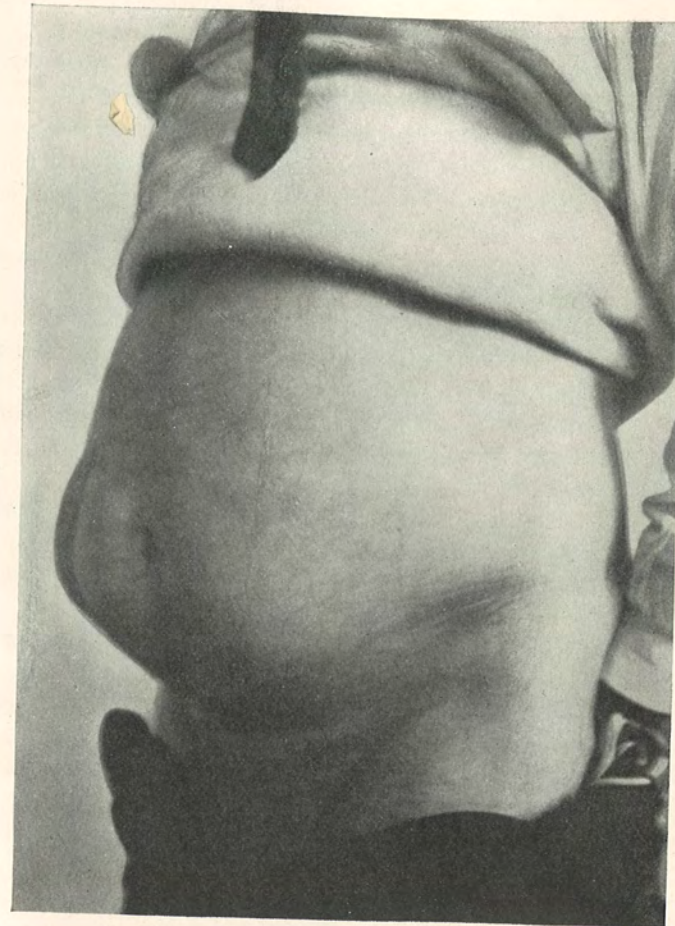
On examining the liver a deep rent was seen to the right of the gall-bladder, extending completely through its substance from the transverse fissure on its lower surface up through the free edge to the coronary ligament on top. This man died four days later, possibly of biliary toxæmia but not of hæmorrhage or peritonitis.

#### THE WEAKENING EFFECT OF A LONGITUDINAL INCISION THROUGH THE RECTUS MUSCLE.

DR. GWILYM G. DAVIS reported the case of a man about forty-six years of age, who had been operated on for appendicitis about a year previously. It was a suppurative case, with drainage, and the incision was made through the right rectus muscle about an inch from its outer border. It extended from an inch and a-half above the umbilicus to three inches below. He was a stout man and wore an abdominal belt. After recovery the rectus muscle in the region of the wound began to protrude and particularly when the belt was off gave him considerable discomfort. He applied for treatment because during the past two months the protrusion had markedly increased.

On examination the scar was found firm in its full extent;

FIG. 1.





there was no parting of the muscle with hernial protrusion through the line of incision. There was no ventral hernia but the whole rectus muscle opposite the level of the incision bulged forward. The line of the incision can be distinctly seen in the photograph (Fig. 1), not as a protrusion but as a depression with the bulging of the paralyzed muscle alongside. In this case it is probable the tenth, eleventh, and twelfth thoracic nerves were divided. The patient was treated by widely excising the scar and sewing the anterior and posterior layers of the sheath of the rectus and the muscular fibres together in separate layers.

In the January 1906 issue of the *ANNALS OF SURGERY* he had published a paper in which he had advocated a transverse incision for the operation of appendicitis and gave as one reason the avoidance of injuring the nerve supply to the rectus muscle. This case is illustrative of that point. The popularity of the incision through the rectus can only be accounted for by the belief that the amount of paralysis of the rectus which is produced is unimportant.

That this is so, at least to a considerable extent, when the incision is quite small, may be admitted, but frequently what are expected to be easy cases prove to be more difficult. The desirability of additional room causes the incision to be enlarged and also sometimes pus necessitates drainage and then the incision is not so innocuous and conditions such as shown in this case occur as sequelæ.

DR. CHARLES F. NASSAU said he had a great deal of interest in the subject of abdominal incisions as during the past eight years he had studied the effects of many rectus incisions in his gynæcological work at the German Hospital. He has become convinced that a large percentage of abdominal cases are followed by paralysis of the abdominal wall or by hernia. We say that if wounds heal by first intention there will be few hernias, and this has been well shown by Maurice Richardson. But while it is true that primary suppuration of a wound exercises a great influence on the subsequent occurrence of hernia, at the same time we often see hernias when the appearance of the scar indicates that union by first intention had occurred. The appearance of the scar may be misleading, but when this is reinforced by questioning the patient as to the length of time in bed and the



number of times the wound was dressed, the conclusion must be reached that hernia occurs even in wounds that heal by first intention. Unquestionably these cases are due to paralysis of the inner side of the rectus muscle which has been deprived of its nerve supply. Analogous cases are those known as crutch paralysis, wrist drop, etc., which follow interference with nerves, and prove that paralysis may be due to such injury. If the nerve supplying a muscle be cut, the muscle becomes valueless and gradually gives way with resultant hernia. All surgeons who have performed kidney operations necessitating extensive incisions have noted that afterward the entire side of the abdominal wall hangs pendulous. When Dr. Nassau makes a median incision he cuts the sheath of the rectus muscle and then pulls the muscle from the median line and avoids cutting it if possible. He began using the method advised by Dr. Davis before his paper appeared and has become convinced that if one employs this method or a modified McBurney, going toward the median line and downward when it is necessary to get into the pelvis, that paralysis will not follow. He operated on a patient last fall and through the incision determined there was no tubal or ovarian disease and also that there was no distention of the gall-bladder and there has been absolutely no paralysis since. When surgeons used the incision known as Sonnenburg's they recognized that the farther out it was made the less danger there was of hernia. This was due to the fact that in the latter instances none of the nerves supplying the internal oblique were cut. One can make the wound by the Davis method large enough to allow of any reasonable manipulation and yet by suturing layer to layer secure a firm wall if there be healing by first intention. If such incision be used in bad cases of appendicitis, not of the desperate type but those in which there is a question of drainage, the wound may be completely closed after a small wick is placed under and passed out posteriorly in the loin. Surgeons will find this incision more satisfactory the oftener it is employed. A second incision is of course necessary when the gall-bladder is diseased. An advantage of the Davis incision is that one can go down to the rectus muscle, pull it to the inside, and thus secure a great deal of room. Then if it be necessary to go into the pelvis the incision can be prolonged along the rectus because this will be below the nerves. On account of the frequency

with which this is necessary in women, Bloodgood often starts with a U-shaped or boomerang-shaped incision in the skin. One of course should not employ the incision if suspicious of pelvic disease in women, but in men it serves every possible purpose.

DR. ROBERT G. LE CONTE said he did not like to disagree with the proposition of Dr. Davis, but that he had performed hundreds of operations through the right rectus muscle, with and without drainage, and with perhaps two exceptions he has no knowledge of subsequent hernia. It is true that the patients at the Pennsylvania Hospital belong to a nomadic class and the statement does not mean that hernia has not occurred more frequently but that he has no knowledge of it. He incises the fascia fully and then tears the muscle fibres apart with his fingers. In tearing through the muscle the nerves are usually stretched but not lacerated. If the incision is more than three inches in length one or two nerves may be seen as white flaccid cords, traversing the incision. He frequently separates the muscle bundles above or below these little threads in the wound. There is no paralysis of the rectus from this incision. He is of the opinion that the incision recommended by Dr. Davis does not give much more room than does the McBurney incision unless muscle fibres are cut across.

## ACUTE HÆMORRHAGIC PANCREATITIS.

DR. FRANCIS T. STEWART reported two cases of acute hæmorrhagic pancreatitis. For the privilege of operating upon and reporting Case I he was indebted to Dr. Robert G. Le Conte, and for Case II to Dr. T. G. Morton.

CASE I.—J. H., female, aged forty-eight was admitted to the Pennsylvania Hospital May 1, 1906. About sixteen years ago she had an attack of jaundice, which left as a legacy a severe indigestion characterized by more or less continuous epigastric pain, worse after eating, and attacks of vomiting. There has never been any blood in the vomitus or in the feces. The patient has lost considerable weight and has become a morphin habitué. During the past few years she has also had several attacks of "kidney trouble," *i.e.*, the lower extremities would become cedematous and the urine dark and reddish. Two days



before admission the pain became agonizing and the vomiting continuous.

On admission the temperature was 99 F., pulse 92, the respiration 36, and the expression anxious. There was excruciating pain in the epigastrium reflected to the back and to the left shoulder. The whole epigastrium was tender and the muscles moderately rigid. Beneath the muscles could be felt a mass stretching across the epigastrium. An incision through the right rectus muscle revealed scattered areas of fat necrosis on the great omentum and one spot on the jejunum. The pancreas was exposed by tearing through the gastrocolic omentum; it was twice the normal size, indurated, inflated with blood, and covered with areas of fat necrosis, one of which was excised and proven to be necrotic fat on microscopic examination.

There was no free blood in the lesser peritoneal cavity. A horizontal incision about four inches long and about one-quarter of an inch in depth was made into the pancreas and packed with gauze for the purpose of drainage; there was very little bleeding from this incision. The gall-bladder, which was tensely distended with dark bile, was drained, it being fastened in the upper angle of the wound. No stones could be found. Cultures from the pancreas and gall-bladder made at the time of operation were sterile. No pathological lesion could be detected in the stomach. Urine yellowish red, cloudy, whitish sediment, acid, S. G. 1022, considerable amount of albumin, no sugar, many hyaline and rather coarsely granular casts and leucocytes, and a few epithelial cells. Hewitt's test for lipose negative. Several subsequent urinary examinations were made with practically identical results.

Subsequent to operation the pain was markedly relieved but did not wholly disappear for three weeks. The gall-bladder fistula closed in three weeks, but there is still a small sinus at the lower angle of the wound marking the site of the pancreatic drain; pus from this sinus shows the ordinary pyogenic bacteria but no necrotic fat.

Case II.—C. W. female, aged fifty years, was admitted to the Pennsylvania Hospital November 25, 1899. She had never been ill before. The present illness began three days ago with sudden sharp pain in the epigastrium and vomiting. Previous to this the bowels moved regularly each day but since there has

been absolute constipation. Purgatives and enemata were given each day without result. On the second day of illness the pain shifted from the epigastrium to the left iliac fossa and the vomitus became black and foul-smelling. On admission the temperature was 99 F., pulse 120, and weak, and the respiration 36. The countenance was pinched and covered with perspiration, the tongue red with a white strip down each side, and the breath fecal. The abdomen was distended and most tender in the left iliac fossa. Vaginal and rectal examinations were negative. Diagnosis, intestinal obstruction, Immediate operation, Median incision below the umbilicus revealed disseminated fat necrosis.

The patient's condition at this time was so serious that the wound was hurriedly sutured. Death at the completion of operation.

Postmortem made through the abdominal wound by Dr. J. A. Scott. Omentum speckled with round, yellowish white, slightly raised areas varying in diameter from one eighth to one-fourth of an inch. The mesentery but not the intestine showed the same spots seemingly following the blood-vessels. On microscopic examination these areas are found to be composed of fat droplets, granular material and many crystals. The pancreas is covered by a bloody plastic exudate, is indurated and about three times its normal size. The peripancreatic fat is necrotic in numerous places. The pancreas itself is deep red in color and shows numerous necrotic areas; it is infiltrated with blood, the hæmorrhages being most marked in the body and tail.

Urinary examination revealed albumin and casts, but no sugar.

DR. STEWART stated that one point was worthy of discussion. The general advice in textbooks is to open and drain, but they do not say whether the pancreas should be punctured or incised, or if the lesser peritoneal cavity alone should be drained. Laboratory workers say to avoid incising the pancreas because the secretion exerts an untoward effect upon adhesions, the surrounding fat, and even upon other tissues. In the case reported he incised the pancreas. Is this the proper procedure? It did no harm in this instance, at least.

He recalled a case of gunshot injury of the pancreas, the bullet going also through both walls of the stomach. It occurred



soon after Park advised posterior drainage in such cases, but the wound was so clean and the peritoneum in such good condition that he did not drain, even after reading Mikulicz's statements on the subject. The patient recovered, hence leakage could not have been great. Park, Körte, and others advise posterior incision below the lower pole of the left kidney for drainage after the first incision has been made in front, the latter being usually done in order to make the diagnosis. In some instances they close the anterior wound after draining posteriorly. In his case he drained anteriorly.

STATED MEETING, HELD OCTOBER 1, 1906.

The Vice-President, ROBERT G. LE CONTE, M.D., in the Chair.

LYMPHANGEIOMA OF THE CHEEK

DR. FRANCIS T. STEWART reported the case of an infant, who was seen by him with Dr. Robert Pitfield soon after birth. The whole right side of the face was occupied by a soft semifluctuating mass which extended from the mid-line of the upper lip back over the parotid, and from the orbit down over the lower jaw (Fig. 1), and which bulged into the mouth. The right eye was

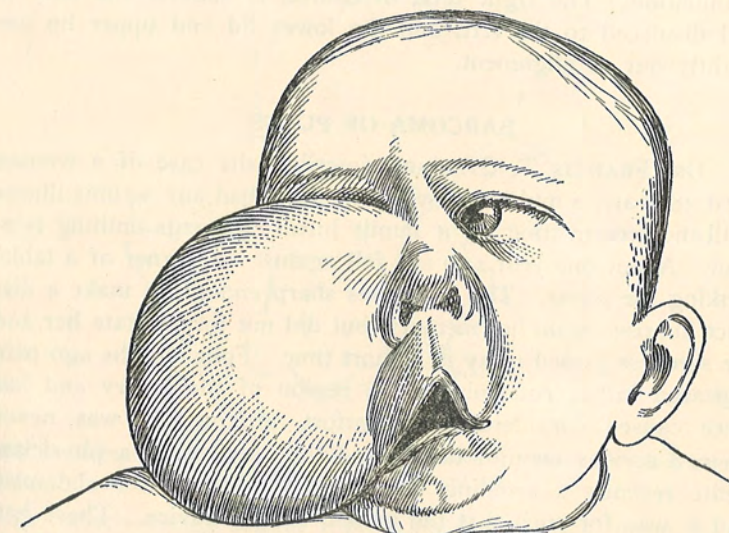


FIG. 1.—Lymphangioma of cheek.

closed, the nose displaced to the left, and the mouth distorted. A hollow needle passed into the cheek withdrew a small quantity of straw-colored fluid. The skin was exceedingly thin and contained a few dilated veins but was not adherent. It was thought advisable to postpone operation as long as possible in order to give the infant a firmer hold on life. At the end of four months, however, the swelling had distinctly increased in size and there