new bone would form from the periosteum after excision of the head and neck of condyle, which would subsequently lessen the range of motion. The results in these two cases and in the others reported demonstrate that this danger is scarcely to be apprehended, and that it is perfectly safe to make a subperiosteal excision.

STATED MEETING, MARCH 2, 1903.

The President, Richard H. Harte, M.D., in the Chair.

PAPILLOMA OF THE VULVA IN A CHILD.

Dr. George Erety Shoemaker reported the case of a girl, aged six, who was seen with her physician because of a bleeding growth protruding from the vagina, accompanied by a persistent irritating discharge. The general health of the child had been impaired for a year, and adenoids of the nasopharynx had been recently removed by another surgeon. About eight months before a white vaginal discharge had appeared, and had since resisted treatment at the hands of various physicians. Bleeding had appeared six weeks before his visit, but the growth had been noted only for a few days, and had increased decidedly.

Examination showed several soft, easily bleeding, prominent papillomatous masses occluding the vulvar cleft. There was no involvement of the skin surfaces, or of the anus. The masses were pale pink in color, sharply elevated, pedunculated, and quite fragile, while some were flattened from side to side and serrated on top like the comb of a cock. One rounded portion half an inch in diameter sprang from within the urethra by a stem. Smaller growths sprang from pits beside the urethra, while inside the posterior commissure the bases of others, which were large and irregular, were attached. None appeared higher in the vagina. The discharge showed diplococci within the cells of typical gonorrhœal character.

After twisting off the growths, their bases were burned with the thermocautery, the one springing from the urethra being, however, tied off to avoid contraction. Protargol solution was ordered for the discharge. Recovery was prompt. The reporter added that these vascular tumors of the urethra were said by Pozzi to occur in poorly nourished children, and to be due to irritating discharges. They are more common in the adult. It is not thought necessary by some authors to consider them venereal in origin, though they are apt to accompany gonorrhœal or

syphilitic disease. Two varieties are described, the flat condylomata which are of syphilitic origin and frequently spread over the perineum and about the anus. The acuminated variety assumes a more typical papillomatous form and is the variety seen in this case.

The theory that they may occur independent of gonorrhœa is quite doubtful. Gynæcologists who have had occasion to make systematic microscopical tests of apparently innocent vaginal discharges have been many times impressed with the impossibility of excluding gonorrhœa by the macroscopical appearance of the surfaces involved or of the discharge; and if they were subjected to careful search, it is probable that all cases would show the gonococcus at some period of their history.

Boldt says (Keating and Coe, "Clinical Gynæcology," page 528) of these condylomata that observation has shown their occurrence even in children, though bacteriologists have not yet succeeded in proving the presence of gonococci in pointed condylomata. This case would seem to prove the presence of this exciting cause. Dr. J. Dutton Steele, of the Pathological Laboratory of the Presbyterian Hospital, kindly examined the growths and pronounced them papillomata with round-cell infiltration at some points.

The child was remarkably submissive to free exposure and examination, which suggested the possibility that she had been accustomed to handling, and that gonorrhœal infection might not have been accidental.

THE DRAINAGE OF THE CHEST IN EMPYEMA WITHOUT THE USE OF TUBES.

Dr. Leon Brinkman read a paper on the above subject.

After reviewing the state of present knowledge and practice in cases of empyema of the thorax, he continued with a description of a method whereby immediate adequate drainage could be secured without the use of drainage tubes.

He said that the operation advocated by Estlander, while a distinct advance in the treatment of empyema, is a very extensive one, and does not present any advantage over the method described below. Among twenty-seven cases in which it had been applied by him there were several in which, had it not been adopted, he would have been compelled to do the Estlander operation, entail-

ing as it does a greater amount of manipulation, destruction of tissue, and a great mortality.

Dr. Carl Beck had devised a method somewhat similar to the one advocated by the author, differing, however, in several vital points. He was not aware of the operation advocated by Beck until in September, 1902, when it was brought to his notice by Dr. Gibbon, of Scranton. He had since gone over the literature carefully, and had found that Dr. Beck had reported his experience with suture of the pleura to the skin as early as 1894; he, however, introduced a drainage tube after three days to avoid hæmorrhage.

The operation recommended by Beck consists in making an incision over the seventh rib, parallel to the rib, reflecting back the superficial structures, denuding the rib of its periosteum, introducing a special scissors beneath the rib, which also served the purpose of a periosteal elevator, and excising four inches of the rib.

The great point of difference between the operation advocated by Beck and the one he was about to describe is, that in the latter additional facility is afforded to manipulate within the chest cavity; that with each inspiratory movement of the chest wall a wider range of lung expansion is possible; a freer inspection of the chest cavity is permitted, making it easy to avoid the formation of pockets and doing away with the necessity for packing the chest cavity.

His own operation for immediate drainage of the chest for empyema is performed after the following manner. The patient having been prepared, a vertical incision is made in the mid-axillary line down to and exposing the fifth, sixth, and seventh ribs, more if necessary. The skin, superficial fascia, and muscles are dissected back on either side of the wound, so as to expose at least two inches of the ribs; the periosteum is freed from the anterior surface of the ribs, to permit the introduction of the periosteal elevator beneath the ribs. An elevator is then carefully introduced beneath each rib successively, denuding them of their periosteum and underlying structures. The ribs are divided; the pleura is protected from injury by a special elevator, which performs a twofold function,—elevation and fixation of the ribs,—so as to facilitate division of the ribs with bone-cutting forceps.

The pleura having been exposed, a small vertical incision is

made in it at the lower angle of the wound, at about the middle of the space, to permit the more gradual escape of the purulent secretion. Upon the complete evacuation of the purulent contents, the incision in the pleura is continued upward until it reaches the upper angle of the wound.

A free inspection of the interior of the chest cavity is now possible by retraction of the wound; if the lung is found fixed and collapsed in the upper portion of the cavity, an attempt should be gently made to separate the adhesions; if these are too firm to permit this, then they must be incised and blunt dissection resorted to, avoiding unnecessary force, which might produce extensive laceration of the lung tissue.

When the condition within the chest cavity is complicated by encysted pockets of pus, either interlobular or between the lung and the posterior chest wall, it may be necessary to go as high as the third rib in the excision.

The operation is completed by stitching the pleura and the skin together around the entire wound, thus offering a large, free opening for the escape of the succeeding secretion. In order to avoid injury to the diaphragm, all incisions are made with this organ in view.

A serous membrane like the pleura, which under normal circumstances has great absorptive powers, is capable of taking up a toxic amount of drug from any fluid thrown into the chest cavity which would contain a sufficiently strong antiseptic to alter the character of the pus. Although the character of the membrane is altered by the inflammatory process, still it is capable of absorption.

In commenting upon the practice of irrigation of the chest cavity, the dangers of this procedure should be well borne in mind; fatal syncope and hemiplegia are prominent among these. From experience, he had found that irrigation of the chest cavity does not diminish the amount of discharge, but rather, on the other hand, favors an increase.

The periosteum must be carefully dissected away, otherwise, during the process of repair and closure of the wound, pain-creating masses of fibrous and calcareous tissues are formed.

During the past five and a half years he had spent considerable time and thought in perfecting the detail of the immediate method of drainage without tubes, and had had an opportunity to

compare it with excision and tubular drainage. The total number of cases operated upon for empyema was forty-seven, twenty of which were by excision and tubular drainage, the remaining twenty-seven were by the immediate type of drainage, stitching the pleura to the skin. The results in the latter method had been so conclusive that he believed the benefits from it were unquestionable. Of the twenty-seven cases treated by this method of drainage but two had had a protracted convalescence, and these would have occurred under any method employed. The first was a young girl with a tubercular empyema complicated by extensive tubercular involvement of the base of the right lung. It is now two years since she was operated upon. Her condition at the present time is as follows. A small discharging sinus is seen at about the middle of the scar of the former operation, from which a slight amount of semipurulent material makes its escape. Microscopical examination of the discharge from the sinus and of the sputum fail to reveal tubercle bacilli. Her general condition has improved in the past four months to a remarkable degree, her weight having increased thirty pounds. The area of lung involvement in the impaired lung has decreased to one-half its former dimensions.

The other case occurred likewise in a young female. The empyema was a secondary complication to pneumonia. In addition to the empyema, there was a localized patch of gangrene in the anterior pleural surface of the lung, which upon separation developed into a bronchial fistula. With the gradual decrease in the size of the wound, there has been a perceptible decrease in the amount of discharge and of the air making its escape through the sinus. At the present time there is scarcely any discharge, and air can only be forced through the sinus when the breath is held and forcible compression of the chest wall made. It is now seven months and two weeks since she was operated upon.

The remaining twenty-five cases by this method have all done well, the shortest time for a cure to be established was three weeks and the longest five months.

It will be found necessary in some cases to freshen the edges of the wound and bring them together with sutures, so as to hasten the closure. This was done in five of the twenty-seven cases, the discharge having ceased after three weeks.

Dr. Henry R. Wharton said that he had found simple

incision with the insertion of tubular drainage very satisfactory, especially in cases of empyema in children, though in later years he has often excised a rib. He rarely excises more than one rib, and only from one to two inches are removed. The success of these operations in children depends on the elasticity of the chest wall. Preliminary aspiration is wise in many cases, this being done some hours or even days before the radical operation. He has never practised the operation recommended by Dr. Brinkman, but thinks the only objection to the operation is the time required, for time is a very important element in operations for empyema in children. The danger from irrigation in these cases is very great, and it should not be employed. Decortication of the lung, recommended by Fowler in the case of adults, is theoretically a very good method; but hæmorrhage is apt to be profuse, and the time consumed is necessarily so great as to make the operation dangerous. Resection of ribs and tubular drainage, or stitching the pleura to the skin if that is preferred, are probably the best operations that can be done for the patient. It is a mistake to drain without having broken up adhesions. The incision should be made large enough to allow search for and breaking of adhesions, as prolonged suppuration is often due to their presence.

Dr. John H. Gibbon said that the operation recommended by Dr. Brinkman appealed to him, and had in it many points to be commended. In one class of cases, however, he does not think it practicable, namely, the acute empyemas of children. These cases he believes will do as well with tubular drainage as when operated on by the method advocated by Dr. Brinkman. In adults, and where the condition is not so acute, the latter method is no doubt a good one. Dr. Gibbon briefly reported two cases. The first was that of acute empyema in a child of twelve months, which he thinks is an unusually early age for that affection. The child had been extremely ill from pneumonia for a number of weeks. Prior to operation, which consisted of simple incision with tubular drainage, six ounces of pus were aspirated from the pleural cavity. The child was well in six weeks. The second case was one of sudden death in a child during the application of a dressing three weeks after operation. This case was reported because we generally hear of sudden death in these cases as being due to irrigation. In this instance irrigation had never been employed. The case was one of double empyema, operation upon

which illustrated very well the advantage of chloroform anæsthesia and the necessity for rapid operation. Resection of one rib on each side and the opening of an abscess of the shoulder were performed in eleven minutes. The child was taken from the hospital against advice, but was dressed at home by a competent physician. Three weeks after operation the child was turned from one side to the other while being dressed, and died at once. In reply to Dr. Gibbon's question as to age incidence of empyema at the Children's Hospital, Dr. Wharton said that the youngest patient he remembered operating upon was eighteen months of age. The child did perfectly well under simple incision and tubular drainage. Empyema is certainly unusual in children under one year of age.

Dr. Richard H. Harte said that as to technique he was convinced that there is nothing better than the straight, mid-axillary incision, provided it gives perfect access to the cavity. Time is of the greatest importance in these operations. With care two or more ribs can be rapidly exposed and a suitable director passed underneath them separating the costal pleura. Then by introducing a heavy pair of bone forceps a section of the ribs can be readily cut and removed, and it is rarely necessary to apply any sutures to the bleeding vessels. The patient can then be turned over on the side, the costal pleura broken through, and the chest contents drained, thus avoiding all the annoyance of air being drawn into the pleura and the unnecessary soiling of the patient by the escaping pus. The greatest care should be taken after the pus has escaped that all masses of fibrin are carefully removed from the pleural cavity with a suitable pair of forceps, since, if masses of fibrin are left, great annoyance will be occasioned by the blocking up and occluding of the drainage tube. This drainage tube should be double and of as large a size as can be obtained. It is advisable to use two tubes side by side, and retain them in position by the suture which is used for closing the skin wound. Care should be taken that the ends are not allowed to irritate the lung, and therefore the tubes should be used either just passing through the costal pleura or else sufficiently long to drain over and pass down deeply into the pleural cavity, thus avoiding the ends of the tubes coming in contact with the lungs, which is always a source of irritation and discomfort to the patient. In Dr. Harte's experience nearly all cases of em-

pyema heal in a comparatively short time, provided the cases are seen early and before the lung has an opportunity to become tied down by old adhesions, which prevent its expanding and close the pleural space.

Dr. Brinkman, in rejoinder, said that Dr. Wharton's method would suffice for acute empyema in children. His experience has been mainly with late cases, in which his own method is more applicable. By this method, adhesions, especially those between the lobes, can be easily separated, and the lung allowed to expand, which is the secret of success in these cases. Patients will get well if only a simple incision be made, but the method described facilitates recovery. The operation can be done in from fifteen to eighteen minutes. He thinks the death reported by Dr. Gibbon was due to shock or to an embolus in the brain. Shock is now recognized as the cause of deaths which occur during irrigation. The writer knows of no deaths from chloroform, but has heard of one resulting from struggles during etherization. The straight incision is undoubtedly the best. If it is carried below the seventh rib, the diaphragm is apt to be injured, but the finger can be carried down much farther. Dr. Brinkman has seen one case where the patient wore a silver tube in his side for fifteen years. Removal of the tube was followed in a week by healing of the cavity.

THE SURGICAL TREATMENT OF EXOPHTHALMIC GOITRE.

BY JOHN B. DEAVER, M.D.,
Surgeon-in-Chief to the German Hospital.

It is now nearly a century since exophthalmic goitre was first described by Caleb Parry and seventy years since Graves wrote his classical essay upon the subject, and yet the treatment of the disease has never been satisfactory, in most instances merely alleviating the symptoms. The clinical picture of exophthalmic goitre is so typical that the diagnosis is always easily made unless exophthalmos is absent, when careful inquiry of the early symptoms and course should correct any doubt as to the true condition.

Miss A. B., aged twenty-four years, referred to me by Dr. Charles K. Ladd, of Towanda, Pa., was admitted to the German Hospital on December 30, 1902. The family history is quite interesting; her father is living and well, but is frequently nervous and irritable; her grandmother and mother died from heart trouble, and were also of nervous temperaments. A brother died from heart disease, chorea, and rheumatism. She had measles, whooping-cough, and varicella when a child; menstruated first at fourteen, continuing regular and without dysmenorrhœa until last summer, when she missed several periods. There is a history of frequent convulsions up to the age of eight, but their nature could not be determined. At the time of beginning menstruation there was distinct enlargement of the thyroid gland, lasting about one year and disappearing under the use of electricity. There was no palpitation nor dyspnœa at this time, but she had a number of fainting spells. She suffered from slight rheumatic attacks during girlhood.

Four years ago the thyroid gland became enlarged and the eyeballs prominent, with attacks of indigestion, abdominal colic, and nervousness. The goitre continued with a gradual increase in the symptoms of indigestion until March, 1902, when the entire

symptom complex of exophthalmic goitre manifested itself. Her neck increased in size, with resulting dyspnœa and inability to wear a collar or anything tight around the neck; she became nervous, irritable, and easily upset; worried over trifles, always anxious to finish anything undertaken, and restless until the task was finished. Palpitation of the heart was present and increased by exertion. She became breathless and weak after climbing stairs, and suffered from frequent spells of profuse perspiration over the entire body, most marked over the chest, neck, and arms.

Her appetite became capricious, and for two months she suffered from diarrhœa. There has never been any jaundice present. These symptoms have been continuous until admission, when the following observations were made:

The eyes are prominent, easily irritated with frequent lachrymation, widely dilated pupils, and an injected conjunctiva; winking is infrequent. The palpebral angle is widened, but the sclera is not visible below the upper lid, and the lid readily follows the movements of the eye. No lagophthalmos can be observed, nor is there corrugation or wrinkling of the eyebrows when the patient looks up. There is slight internal convergence.

The thyroid is symmetrically enlarged, without a thrill, and by auscultation a venous hum can be heard over the struma and the carotid vessels. Slight hoarseness is present, the patient's voice becoming husky after talking to any extent. Tachycardia is present with arrhythmia.

The pulse averages 120 when quiet, but increases with the slightest exertion up to 160. The apex beat is in the fifth interspace, diffuse, and seen beyond the nipple; the impulse is moderately forcible, and a slight initial systolic murmur can be heard, transmitted to the axilla.

The lungs and abdomen were negative. A tremor of the fingers can be seen upon extension of the hand, especially noticeable when the patient becomes excited.

There was no polyuria, the urine containing a trace of albumen, but no sugar or casts. The blood count showed no anæmia, with 10,320 leucocytes and an eosinophile of 10.5 per cent. The temperature was always normal before operation, the respirations ranging from 20 to 24.

One week after admission, bilateral resection of the cervical sympathetics was performed under ether anæsthesia. An incision

five inches long was made along the posterior border of the right sternomastoid muscle, which was reflected forward along with the great vessels and pneumogastric nerve. The sympathetic nerve and its three ganglia were found and removed entire from a point one-half inch above the superior ganglion to one-half inch below the inferior ganglion. The middle ganglion was located as lying upon the inferior thyroid artery, the inferior ganglion being behind the subclavian artery. After checking all hæmorrhage, the wound was closed with a continuous silk suture and a collodion dressing applied.

The operation was repeated on the left side, the middle ganglion being found just above the inferior thyroid artery and the inferior ganglion just below the same blood-vessel. On account of the high position of the lower ganglion, the nerve was cut well below it, in order to remove the entire origin of the inferior cardiac nerve. Silk sutures and a collodion dressing closed this wound also.

Patient took ether badly from the start; was cyanosed and full of mucus; had some trouble with nasopharynx previous to operation. Operation was interrupted several times on account of the anæsthetic. At completion of operation the patient's color was very bad and pulse rapid and irregular; was given oxygen for an hour after operation. On coming out of the anæsthetic she vomited clear mucus in gushes. Commenced cough almost at once, and cough continued, accompanied by intermittent expectoration of large quantities of seromucus. Several hours after operation both lungs were noted to be full of moist bubbling râles, and respiration was labored and harsh. Patient remained cyanotic, and received oxygen at fifteen-minute intervals for several days. The day following operation she was bled from left arm and lungs cupped posteriorly. Both bases flat. Patient remained cyanotic and with rapid pulse for several days. Symptoms gradually subsided, and patient made satisfactory recovery.

The immediate benefit of the operation to the tachycardia could not, unfortunately, be observed, as the patient developed a severe pneumonia twelve hours after the operation, and for several days she was in a perilous condition, the temperature reaching 105° F. and slowly declining, reaching the normal seven days after operation.

The exophthalmos was noticed to have disappeared almost

entirely twenty-four hours after the operation, and, after her recovery from the lung condition, convalescence was rapid. The wound healed by first intention, and on January 31, twenty-six days after operation, the patient was discharged, with no appreciable exophthalmos and with entire disappearance of all nervous symptoms. The goitre, though diminishing, was still present, but causing no discomfort. On February 26 the patient writes that she is quite well and markedly improved by the operation.

The underlying causes of exophthalmic goitre are obscure and subject to much debate; whether a direct or reflex stimulation of the sympathetic, a neurosis, a lesion, a compression, or an intoxication has not definitely been determined. The progress in the study of the internal secretion of this gland, like all the other ductless glands, has been slow, and has not furnished a satisfactory cause beyond the probable alteration of the secretion.

At the present time three theories are advanced, viz., hyperthyroidization, disease of the central nervous system, or alteration in the sympathetic system.

The arguments in favor of a lesion of the thyroid gland itself are mainly based on the failure to find reliable post-mortem evidence of disease of the nervous system, and the altered secretion of the thyroid is supposed to exert a direct or indirect toxic action upon the heart, nervous system, and general nutrition, the exophthalmos being caused by a local deposit of fat behind the eyeball. Mikulicz and Reinbach believe that while the presence of Basedow's disease cannot be explained by an excessive function of the thyroid, yet the hypertrophy of this gland plays a prominent rôle by adding the phenomena of thyroidism to the other symptoms. The failure of thyroidectomy is therefore to be ascribed to the fact that, in spite of the removal of this factor, the primary injury, viz., the nerve lesion, is sufficiently severe to render the phenomena of the disease continuous. The influences of heredity, age, sex, and temperament tend with remarkable unanimity to point to a nervous origin.

The tachycardia, hyperidrosis, tremor, decrease of electrical resistance, and general nervous unrest which are so constantly present would also denote a nerve influence. There are some cases, also, in which the enlargement of the thyroid is very slight or even absent.

For the present, at least, we must assume that exophthalmic goitre is dependent upon all these factors, and that a lesion of one may cause specific alterations in the others, with the production of the well-marked symptoms denoting the disease.

The diagnosis from simple parenchymatous goitre must be made in those cases where the exophthalmos is absent, particularly when the ordinary form of goitre is accompanied by cardiovascular symptoms. The most marked points in which the simple goitre differs are the irregularity of the position of the enlarged thyroid, the direct pressure upon the trachea from the size of the growth with dyspnœa and stridor, and the more mild character of the nervous and vascular phenomena if present together, of course with the absence of the exophthalmos.

The treatment of Graves's disease with drugs is unsatisfactory, and all like diseases, the medical cure of which has been unsuccessful, the number of so-called curative remedies is a large one. Digitalis, belladonna, bromine preparations, iron, and various nerve sedatives have been most frequently used.

Electricity, galvanic and faradic, has been tried without any benefit; iodine and thyroid feeding aggravate the symptoms.

There are four surgical procedures adopted:

1. Partial thyroidectomy.
2. Ligature of the thyroid vessels.
3. Operations upon the cervical sympathetic nerves.
4. Operations upon distant parts of the body.

In addition to these operations, exothyropexy has sometimes been employed, performed by exposing the gland and drawing it out of the wound and leaving it exposed to the

air. Atrophy is supposed to result, but the operation is dangerous, ineffectual, and very disfiguring.

Thyroidectomy has been the operation usually performed for the relief of exophthalmic goitre, especially when the cause is believed to be hypersecretion of the thyroid epithelium. It must be admitted that this operation has furnished good results, especially in the hands of Kocher, but the mortality has been very high. Starr, Sorgo, and Iricomi have published statistics up to 1896 with a mortality varying between 12 and 15 per cent. and a cure obtained from 25 to 39 per cent. Partial resection has been the method used, because, unlike the simple goitre, that in Graves's disease cannot be enucleated. Ætherization of these patients is difficult and fraught with danger, especially from a postoperative pneumonia, and Kocher, recognizing this fact, always uses local anæsthesia. The escape of the thyroid secretion over the cut surfaces during the removal has been believed to aid in the production of a postoperative thyroid intoxication.

Ligature of the thyroid vessels has been tried, especially by Kocher, in the hope that by cutting off the blood supply the gland will undergo atrophy. The exposure of the inferior thyroid vessels may be a difficult task. Kocher usually ties off both superior and one inferior thyroid artery, and frequently combined this operation with partial resection of the gland or resection of the cervical sympathetics in severe cases; the combined operations are often performed in several sittings.

Section of the cervical sympathetic for exophthalmic goitre was first performed by Jaboulay, of Lyons, in 1896, and later in the same year, Jonnesco, of Bucharest, resected part of the nerve together with the superior cervical ganglion. The results were not sufficient, however, and Jonnesco and others extended the operation until complete bilateral excision of the entire cervical sympathetic nerve with its three ganglia, and even in some cases the upper thoracic ganglion, was advocated.

The theory upon which the operation is based presupposes

the nervous origin of the disease with alteration of the sympathetic nerve. Each of the three cardinal and also the subsidiary symptoms are believed to be dependent upon stimulation of this nerve. Exophthalmos is caused by a stimulation of the cervical sympathetic leading to an energetic contraction of Müller's smooth muscle at the posterior pole of the bulb, the dilatation of the pupil is due to the same irritation of the cervical sympathetic which communicates with the lenticular ganglion and its ciliary branches to the iris.

The goitre depends either upon an enormous dilatation of the vessels of the thyroid from stimulation of the vasodilator fibres of the neck, or, as Jonnesco believes, it is due to an increased activity of the thyroid epithelium with hypersecretions which are dependent upon the permanent stimulation of the secretory nerve-fibres of the thyroid. Resection of the sympathetic, and consequently of the vasodilator, vasoconstrictor, and secretory nerve-fibres, results in atrophy of the thyroid.

Tachycardia is likewise to be attributed to the irritation of the sympathetic which communicates with the cardiac plexuses by several branches, the accelerator nerves of the heart muscle.

The nervous and digestive phenomena are dependent upon changes in the cerebral circulation, possibly a permanent cerebral anæmia produced by a continuous stimulation of the vasoconstrictor fibres of the cervical sympathetic. The vertebral nerve containing a number of vasomotor filaments is given off from the inferior ganglion. Removal of these fibres produces cerebral congestion.

The various operations on the cervical sympathetic for the relief of exophthalmic goitre are the following: (1) Simple division of the cervical sympathetic; (2) ablation of the cervical sympathetic by means of Jaboulay's operation, which, without a large incision, is devised to stretch and twist the nerve by means of forceps attached to its upper and lower ends; (3) simple stretching the cervical sympathetic; (4) partial resection of the latter; (5) partial and extensive resection; and (6) total resection.

Belacescue believes that extensive *partial* resection is only indicated in the cases of Basedow's disease in which the tachycardia is not intense. He believes that the entire bilateral resection with removal of the uppermost thoracic ganglion is easy of performance and harmless in its results, with a far greater percentage of cures than any other operation for the relief of exophthalmic goitre, and practically no mortality.

His statistics show 59 per cent. of cures, 29 per cent. of improvements, and 12 per cent. of failures, with no deaths directly due to the operation.

Jonnesco is also very enthusiastic, having performed over 130 bilateral sympathectomies in the last five years, in two cases removing the first thoracic ganglion. He has not observed in any of these cases any trophic or circulatory disturbances. Of this series, fifteen were performed upon patients suffering with exophthalmic goitre, with a complete cure or marked improvement. The three cardinal symptoms of the disease disappeared completely, nutrition became normal, and the nervous condition was restored to its original stability.

The operation should not be undertaken unless the surgeon is perfectly familiar with the anatomy of the area of operation and able to cope with any anomaly in the course of the nerve or the position of its ganglia. The difficulties encountered during anæsthesia are similar to those in all operations upon the thyroid, and require the careful attention of the anæsthetist at all times.

In severe cases with marked exophthalmos and pronounced nervous irritation, the operation may be performed in two sittings about a fortnight apart, removing one side at each sitting. This undoubtedly insures a more successful result.

In addition to exophthalmic goitre, cervical sympathectomy has furnished excellent results in chronic glaucoma. Jonnesco was the originator, and has collected thirty-five cases, twelve his own, with marked improvement in all but about six cases.

Suker has collected twelve cases, operated upon in this country, with removal of the superior cervical ganglion, with good results, and believes the operation should be performed

in absolute and hæmorrhagic glaucoma; in chronic glaucoma, especially when an iridectomy or sclerotomy has failed, and at all times when other operative measures are refused, irrespective of the form of glaucoma.

The removal of the ganglion causes: (1) Contraction of the iris, (2) relaxation of the circumbulbar muscle, (3) vascular dilatation, (4) lower intraocular tension, and (5) a decrease in the elements constituting the aqueous.

Only the side affected should be operated upon. Jonnesco has also obtained brilliant results in epilepsy by resection of the sympathetics, on the hypothesis that epileptic attacks are due to cerebral anæmia from irritation of the cervical sympathetics with narrowing of the lumen of the cerebral blood-vessels. "Section of the cervical sympathetics by cutting off the avenue through which such impulses are carried prevents the occurrence of brain anæmia, and so permits the uniform and constant nutrition of brain tissues on which cerebral stability depends. The section of the cervical sympathetic also seems to act favorably by preventing the flood of nervous impulse or reflexes from irritated abdominal or pelvic organs to the brain." (Jonnesco.)

Jonnesco has operated on over 100 epileptics, and records the results for 1896, '97, and '98.

During these years forty-nine were operated upon, with twelve cures and four improvements. These results are accurate, because they have been frequently observed after operation, and he does not regard any of his results as definitive until at least two years have passed.

In migraine, facial neuralgia, and maniacal irritation the operation has failed to produce results, though but few cases have been subjected to operation.

From my own simple observation, and from a study of the works of those whose experience with the operation has been extensive, I can make the following conclusions:

1. That as surgical treatment is recognized as the most satisfactory in exophthalmic goitre, so is complete bilateral cervical sympathectomy to be considered the operation of choice.

2. The operation should not be performed during the height of psychical irritation or tachycardia, nor by an operator who has not an absolute knowledge of the anatomy of the neck and a large experience in dealing with difficult operative procedures, or the means at hand to cope with any emergency.

3. The results of the operation are far better than the other procedures, the mortality is much lower, and in cured cases the improvement is permanent.

4. In chronic glaucoma, especially after the failure of iridectomy and sclerotomy, this operation may restore vision completely, unless the disease is too far advanced with absence of light perception.

5. In recurring attacks of epilepsy, sympathectomy should be resorted to. The results warrant the operation.

MYOSITIS OSSIFICANS.

WITH A REPORT OF TWO CASES,—ONE TRAUMATIC, THE OTHER NON-TRAUMATIC.

BY WILLIAM J. TAYLOR, M.D.

ALTHOUGH knowledge concerning the etiology of "myositis ossificans" is obscure, there have been enough cases recorded to establish it as a definite condition; but we are still very uncertain as to its cause. There are two great classes. The first those where bone has formed in the softer tissues, with or without history of injury, and in which no connection can be found apparently with the bones of the skeleton or their periosteum; and again, in others there may be osteophytes to which muscle tissue is attached and which has undergone osseous change.

The second is where there is a formation of new bone resulting directly from an accident to bone or its periosteum and involving the muscles and fibrous structures. All these conditions are found in youth. Those of the first class are characterized by local swelling, and, later, loss of function, with gradual ossification of the muscle. This is the most common. A number of cases have been reported under the second heading, in which the muscles become ossified quickly after a single injury, generally, as in my own case, following the kick of a horse, and, as in F. Munro's case, from an injury to the thigh received in a foot-ball game. (F. Munro, *Lancet*, February 21, 1891, p. 427.)

In Munro's case, a young man of twenty-four received a blow on the right thigh while playing foot-ball. He was incapacitated from work for three days. A week after the accident he noticed a hard swelling an inch and a half above the outer side of the knee-joint. This got larger, and five weeks after the accident he sought medical advice. On examination, there was found what seemed to be a lump of bone lying loose in the muscle of the outer

side of the thigh. It was about eight inches long, narrow, and projecting at its lower end and approaching the surface, but broadening out as it passed up the thigh and lying more in the muscles. It was slightly movable except at its upper end. The patient could walk about fairly well with the assistance of a stick, but was able to flex his thigh only very slightly. After about two weeks an incision three inches long was made over the projecting portion, and in the substance of the vastus externus was a mass which had to be removed with bone forceps. There were no complications, and the patient left the hospital well in the course of a few weeks.

Mr. Bilton Pollard (*Lancet,* December 31, 1892, p. 1491) reports a case of "myositis ossificans" in a boy of nine, where a large number of the muscles became ossified without there being any particular injury to account for it. An operation was performed and the teres major muscle was exposed. The bone was found to occupy the substance of the muscle in nearly its whole extent.

Dr. F. W. Burton-Fanning (*Lancet,* September 28, 1901, p. 849) reports a case of a man aged thirty-three, who at the age of eight years had gradual stiffening of the left shoulder without previous injury or pain. At the age of twelve the right knee became impaired until all power of motion had gone. Following this in order came stiffness of the left hip, sides of chest, and lower part of back. At the age of twenty-eight the right arm from the shoulders downward was much swollen, the skin being red and tender. The inflammation was so acute that the arm was thought to be poisoned, but the swelling gradually passed off, and the arm was found to be flexed in the extended position, while the movements of the shoulder previously impaired were diminished. Flexion and extension remained at the wrist, but the forearm could only be supinated through half the natural extent. Two years later stiffness of the right hip was noticed, and this gradually extended until the legs became affected and the patient had numerous falls, but he had never seriously hurt himself, and could not attribute an increase of his malady directly to any injury. He was remarkably free from any other disease.

There was a family history of his father having had "myositis ossificans," and dying at the age of thirty-three from an accident.

Mr. Charles Stonham (*Lancet,* December 31, 1892, p. 1485) speaks of the causation of the disease as being shrouded in obscurity, but that it is essentially one of early life. While heredity is supposed to be a large factor, there are comparatively few in which this can be traced. Most of the cases of "myositis ossificans" cannot be directly traced to any trauma, and there is a history resembling in large part muscular rheumatism; in the cases which he reports and the illustrations which he gives, there seems to be an overgrowth of the bony tissues and the formation of osteomata and osteophytes, as well as ossification of certain of the muscles.

In the illustrations which he gives, the osseous formations are many of them independent of the skeleton, but in some parts they are attached to it, spreading into the muscular insertions as pointed, stalactite-like masses. True spongy exostoses may also be met with. Usually in the form of flattened, perforated plates, the bony tissue may be in nodular masses or sharp and pointed.

He appends a large number of references to cases in English, American, and Continental journals.

Dr. Lydia M. Dewitt (in *The American Journal of Medical Sciences,* September, 1900, p. 295) published a very elaborate pathological report from two cases of "myositis ossificans."

The first case resulted from chronic inflammation (possibly tuberculous), in which ossified masses were found immediately surrounding the femoral vessels, and extending in all directions between the degenerating and regenerating muscle-fibres.

The second case resulted from an injury to bone,—a fracture of the thigh,—which may have injured also the muscles and other soft parts.

Munro (*Lancet,* February 21, 1891, p. 427) speaks of "myositis ossificans" as a result of chronic inflammation either localized or general. In the localized variety the inflammation of the connective tissue is usually the result of repeated slight injuries, the bony tumor in one case appearing five weeks after the injury.

Heredity, although claimed by many writers to be a factor in the causation of the disease, does not seem to play any large rôle in its production, although there are a few cases where it would seem to be operative.

Treatment in the non-traumatic variety has been of little avail in the majority of cases; excision of the muscles doing little or no good, as the ossification of some of the degenerated muscles has very soon taken place.

In Dr. Keen's case, reported in the present communication, excision of the ossified muscle has, however, been of distinct advantage, as in nearly two years there has been no recurrence nor apparently any disability resulting.

In the traumatic variety, or if we might use such a term as acute traumatic, where the condition has followed the receipt of one severe injury, operation and the complete excision of the degenerated muscle and fibrous tissues have resulted in complete relief.

Through the kindness of Dr. Keen, I am able to report his case, and thus give an illustration of the two great varieties of this very peculiar affection. It was my privilege also to assist him in the operation performed upon his patient, and to see her constantly during her convalescence.

These are the only cases I have ever been fortunate enough to see, and in my own case I was at a loss at first to account for the condition which I found at operation; indeed, for a time, and until I received the report of the pathological findings, I feared that it might be sarcoma. The complete freedom from pain made me feel somewhat reassured.

Case I. *Myositis Ossificans Traumatica.*—A young man, twenty-six years of age, of robust health and fine general physique, whose occupation was that of schooling young hunters, was kicked by a horse, December 15, 1900. He had never had rheumatism, but had a slight mitral murmur. The hoof struck him in the middle of the thigh on the anterior surface. The blow was so severe that he was knocked down, and he thought the thigh broken, but in a short while he was able to get up and walk, walked his horse for some distance, and then with the assistance

of some farmers was lifted into the saddle and rode home. The pain was intense, but not completely disabling. A remarkable thing about his injury was that the horse kicked him on Saturday with such force that he thought the thigh was broken, but he was able to walk; and the next day, being Sunday, he did not ride, for this is their custom at his stock farm; but on Monday he got on a horse and had ridden every day until I saw him. He had comparatively little pain except upon extending the thigh and flexing the leg upon the thigh; and he found of late that he did not feel secure in his seat when riding a restless horse, and that his efforts to clutch with his knees gave him pain. He had none of the dull aching or throbbing pain of a sarcoma.

When first seen by me on January 5, 1901, just three weeks after the receipt of the injury, there was a marked swelling on the anterior surface of the left thigh about its middle, and over which the muscles readily rolled. The swelling was hard, but did not feel bony; it gave rather the sense of an organized hæmatoma beneath the periosteum. With the limb at rest there was no pain whatever, but on certain movements of the limb there was pain; this was most marked upon flexing the leg upon the thigh.

On January 8 I made an incision through the rectus muscle down to the periosteum. I found the whole area of the bone—especially of the anterior surface—enlarged and the periosteum thickened, and the muscles—particularly the deeper fibres—containing small bony particles. The pieces of bone and muscular tissue that I removed were directly in contact with the periosteum, which was elevated and the bone beneath found roughened. At one place I removed a small spicule of loose bone. I curetted the bone, removed all the thickened portion of the muscles that I could, and closed the wound with an iodoform gauze wick for drainage. He made an absolutely uneventful recovery, and he had no pain or discomfort.

The muscles and fibrous tissue removed were sent to Dr. W. M. L. Coplin, who sent me the following report:

After a very detailed and minute description of the methods employed in making the examination and of the microscopic appearances of the specimen, he states:

"A definite diagnosis from the examination of disconnected fragments of tissue, such as those submitted in this case, may

seem hazardous, but the findings recorded above strongly suggest the diagnosis of ossifying myositis."

Case II. *Myositis Ossificans.*—Miss A., aged forty years, first consulted Dr. W. W. Keen on April 22, 1901. At nine years of age her mother discovered a slightly tender lump over the left fibula near the junction of the middle and lower thirds of the leg. She had some pain in the leg, which was thought to be rheumatism. At fourteen, walking became distinctly painful, and the muscles gradually contracted until her foot was in marked extension, *i.e.*, an acquired equinus. At sixteen, tenotomy was done, the deformity, however, returning immediately. Some X-ray pictures which she had had taken in Washington showed that there was apparently an irregular, sharp osteophyte growing from the fibula at the point indicated (Fig., A), and that the bone was thickened for some distance above and below this point. There were some other spots in the picture which made me suspect myositis ossificans, though I was doubtful whether they might not be defects in the photographic plate.

The muscles of the right calf were distinctly harder than those of the left calf. I advised operation, which was accepted at once.

Operation by Dr. Keen, May 3, 1901.—I had three objects in view: first, to chisel away the supposed osteophyte, which was still quite painful; second, to lengthen the tendo Achillis, and, third, to remove all of the supposed ossified plates if I could do so.

I made an incision somewhat posterior to the fibula. This passed through quite a thick layer of fat. The deep fascia I found to be irregularly thickened with plates of what I judged to be bone at various places. These multiple bone plates extended well back to the middle of the calf, but, apparently, not to the inner side of the leg. There were also a considerable number of them in the muscular tissue. There was no osteophyte growing from the fibula, but the irregular plates of bone were in contact with the fibula. In order to remove the whole of these bone plates, I was obliged to prolong my incision, so that it finally reached from the upper end of the calf nearly to the heel. At one place there was very annoying though not serious bleeding, which I could not control by repeated ligature and suture-ligature. What I thought to be a large vein ran along with the bleeding artery. Finally, in order to control the bleeding, I cut across

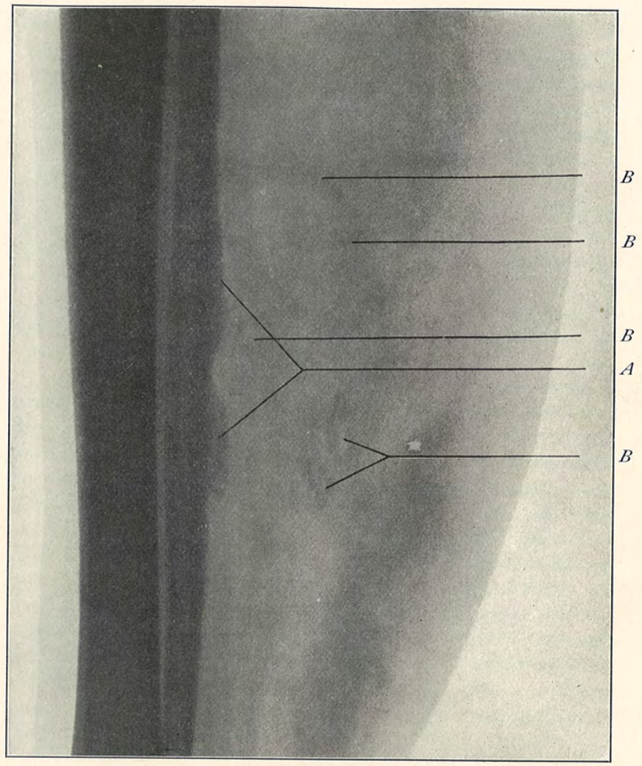

Skiagraph of the bony plates in Dr. Keen's case of myositis ossificans. *A*, the apparent exostosis from the fibula; *B*, the other osseous plates in the muscle.

both artery and vein, and to my surprise found that the supposed vein was a large nerve. It was very much enlarged, was beaded, and so intimately involved in one of the plates of bone and fibrous tissue constituting the disease that it could not be dissected out, and would have had to be sacrificed in any case. I stretched the two ends of the nerve (for they were separated 2.5 centimetres when the foot was flexed to a right angle), when I discovered what it was, and united them with two silk ligatures. The tendo Achillis was divided after Mr. Anderson's and my own method and lengthened by four centimetres, which allowed the foot to be placed at a right angle with the leg.

On May 12 I removed two small tumors, one from the right and one from the left breast under cocaine anæsthesia. Professor Coplin reported them to be "peri- and intercanalicular fibromata of the breast."

Recovery from all three operations was *per primam,* and she left the hospital on May 18. She was then able to move the foot quite freely both in flexion and extension.

I was extremely doubtful at the time, and still am, as to what nerve was divided. The day that she left the hospital, a hair lightly drawn across the foot was felt distinctly at every point, with the exception of the sole (due probably to the thickness of the epidermis), and at a small area above the heel, where sensation was quite imperfect. On the sole of the foot, however, a touch of a pencil was readily perceived. The nerve divided lay almost in the middle line of the leg between the calf muscles and the skin. This would exclude, of course, the posterior tibial; yet it was so large,—its size being about that of the normal posterior tibial,—that it did not correspond with any ordinary cutaneous nerve. Sensation, moreover, was but slightly affected by its division, as I have indicated. Unfortunately, I was not able to make more accurate and frequent examinations on account of absence from the city.

Miss A. writes me under date of December 17, 1902, nearly twenty months after operation, that she has suffered no pain in the muscles since leaving the hospital, that the foot can be flexed to a right angle, and that she can bear her weight on her toes. Non-recurrence of the disease, especially in view of the evidently diseased condition at the margin of the portions of tissue removed, as shown by Dr. W. G. Spiller's report, is especially noteworthy.

Dr. Spiller's report on the nerve and muscle is as follows:

"The tissue removed at operation and sent to me by Dr. Keen is exceedingly dense, much denser than any normal muscle, and in some places has a gritty feel. It can, however, be easily cut with a knife, and when embedded does not turn the edge of a microtome knife. It is not necessary to employ decalcification. To the naked eye the tissue has little or no resemblance to muscle, but appears like dense, fibrous material. In microscopical sections where the alteration is greatest the tissue resembles tendon, and has a glassy appearance when stained with eosine. Numerous masses of closely packed round cells are found throughout the sections, and much recent infiltration of red blood-corpuscles, the result of the operation, is found. The walls of the blood-vessels in the dense fibrous tissue are much thickened, and are infiltrated with round cells, and the lumen in some is very small. Where the tissue is most altered, the muscle-fibres are extremely atrophied, and in a large portion of the tissue have entirely disappeared. The sections in some parts consist almost entirely of fibrous and fatty connective tissue, and here the muscle-fibres are widely separated from one another by this fibrous tissue. In these places the muscle-fibres appear as long slender bundles in longitudinal section, and are many times smaller than normal muscle-fibres, and are without any striation, either transverse or longitudinal. The tendon-like appearance of certain parts of the sections is due to the fibrous proliferation which has caused more and more pressure upon these atrophying muscle-fibres until they have entirely disappeared. Here and there in these tendon-like masses a few scattered muscle-fibres may be seen. The Weigert hæmatoxylin stain shows their presence very beautifully. Where the muscle-fibres are very much atrophied, the sarcolemma nuclei appear unusually numerous; but this is chiefly because the atrophied fibres occupy less space, and the sarcolemma nuclei are, therefore, brought closer together. There is, however, some increase in the number of the sarcolemma nuclei. Only in tissue taken from the edges of the mass removed at operation have I been able to find muscle-fibres of anywhere near normal size; and here they are irregular in outline, are cleft transversely in longitudinal section, and have lost the transverse and longitudinal striations. The sarcolemma nuclei in these muscle-fibres are proliferated, and in places form chains of nuclei within a muscle-fibre.

"Osseoid plates are not very numerous, but are found in some sections. They are irregular in shape, and stain a deeper purple at the edges with hemalum and faintly in the interior. They contain concentric lines and numerous irregular starlike bone cells. The formation of the latter has not been of very long duration, as in old bone the cells do not possess these numerous proliferations. Although the tissue feels gritty before it is embedded, the sections under the microscope do not contain a large amount of osseoid tissue. I have found a mass in one of the sections that appears more like cartilage than bone. In this the nuclei are small and round and the cells resemble cartilage cells. The ground substance is pale yellow, and does not show the concentric markings seen in the distinctly osseoid tissue.

"The condition is one of myositis fibrosa passing into myositis ossificans.

"The nerve that was cut during the operation is much degenerated, and is embedded in the proliferated fibrous tissue, so that even under the microscope it forms an intimate part of this tissue. The connective tissue between the individual nerve-fibres is greatly increased in amount, and for this reason the nerve appears abnormally large.

"In regard to the recent literature on myositis ossificans, I may refer to the valuable paper by Lydia M. Dewitt (*The American Journal of the Medical Sciences,* September, 1900, page 295), and to the monograph on diseases of the muscles by H. Lorenz (Nothnagel's 'Specielle Pathologie und Therapie,' Band xi; 3. Theil; 1. Abtheilung). In these two publications most of what is known of myositis ossificans may be found."

DISCUSSION.

Dr. James K. Young reported a case of myositis ossificans that occurred in a man aged fifty. The rectus of the quadriceps extensor was the muscle involved, the exciting cause being the kick of a horse. The resulting mass was two and one-half inches wide and one inch thick. It was movable and very dense.

Dr. William J. Taylor said he wished to modify slightly the statement in his paper that the patient had had no trouble since. One year after the operation, a horse ridden by the man fell, and threw him in such a way that a root ran into the old operation scar. This was followed for a time by the discharge of

inflammatory material and dark-colored blood, but the wound afterwards healed entirely and has given no trouble since.

Dr. W. M. L. Coplin, who had reported the histological findings in the tissue removed by Dr. Taylor, spoke of the difficulty experienced by pathologists in making diagnoses from very small fragments of tissue, as in the case under discussion. The tissue in question contained masses of marrow cells in a cellular matrix, altogether resembling the cell picture of myeloid sarcoma. The suspicion of myositis ossificans was first aroused by finding newly-formed bone along the degenerating muscle-bundles. Ossifying myositis has been classified as idiomatic or traumatic, and disseminated or local. Regarding the origin of the condition, there is some question as to its inflammatory nature. It is held by some writers to be a dystrophy, thus belonging to the group of diseases including pseudohypertrophic muscular paralysis. This view, however, is not generally accepted. The fact that traumatism is frequently a cause, the presence of lymphoid infiltration and the formation of new fibrous tissue point to the inflammatory nature of the process. It has been thought that it might depend upon the presence of congenital or acquired ectopia of osteogenetic tissue which is stimulated to growth by irritation; the view that the bony change originates in a congenital defect in the involved parts is an adaptation of this theory. Regarding the condition as one that is essentially inflammatory in nature, places it in close relation to the ossifying inflammations of tendon sheaths and glands. Still another view is that myositis ossificans is essentially neoplastic in nature, and thus comparable to cases of multiple osteomata in the lungs, glands, etc. The many suggestions offered prove that the origin of the change is yet unknown. That it is infectious in character has even been suggested. In a reported case of gonorrhœal myositis and in a case of staphylococcus infection, similar but not identical changes have been recorded. It is not uncommon to find near tuberculous foci osteoid or chondroid or, perhaps better, cretaceous areas that may resemble bone. In closing, Dr. Coplin emphasized the possible difficulty in differentiating ossifying myositis from myeloid sarcoma, especially in tissue from the region of the jaw. This difficulty is particularly marked when the specimen consists of only fragments of tissue.

Captain Charles F. Keiffer, U. S. A., stated that he had excised a bony fragment from the deltoid muscle of a cavalry-

man who had first noticed the condition ten years before. The fragment was true bone and had reached the size of a half-dollar. In looking up the literature, he had found that in the times of Gustavus Adolphus and Frederick the Great the soldiers were troubled with what they called sesamoid bones in the deltoid muscles. Their formation was attributed to the irritation and pressure of the guns carried by the soldiers. This cause was probably active in the case of the cavalryman, whose gun was slung in such a manner as to jog against the deltoid.

Dr. William G. Spiller, who made a histologic study of the tissue removed by Dr. Keen, said that the large size of the nerve, of which a piece had been removed, was owing to connective-tissue proliferation. The removal of the segment may have been of advantage, as benefit has at times followed a similar operation, inasmuch as the ends brought together contain more nearly normal nerve tissue than the portion removed.