

face, temperature 104° F., a gangrenous condition of the alveolus, fetid breath, etc. On a hasty examination the case was thought to be one of noma, but after ether had been given it was found that the whole lower jaw was the seat of a fulminating, gangrenous osteitis. The mucous membrane covering the mental portion of the jaw was incised within the mouth, the jaw divided, and each half removed separately with sequestrum forceps by aid of very light traction. The cavity remaining was then curetted and the gangrenous tissue cut away with scissors, hæmorrhage being controlled by iodoform gauze packing. The patient's condition is most serious from systemic sepsis.

STATED MEETING, NOVEMBER 2, 1903.

The President, RICHARD H. HARTE, M.D., in the Chair.

OSTEITIS DEFORMANS.

DR. JOHN B. ROBERTS said that he had reported a case of leontiasis ossium, or hypertrophy of the bones of the face, at a meeting of the Section on Surgery of the College of Physicians of Philadelphia, November 8, 1895 (*ANNALS OF SURGERY*, 1896, Vol. xxiii, p. 303). The woman, who was twenty-two years of age, had suffered from the time she was six years old with a slowly increasing enlargement of the upper and lower jaw-bones. Such cases are supposed by some writers to be an early stage of osteitis deformans. He had unsuccessfully endeavored to find the woman mentioned, in order to see whether there has been any change in her condition that would throw light on the possible relationship of these two disorders of the bones.

Leontiasis ossium, sometimes called Virchow's disease, and osteitis deformans, often called Paget's disease, are evidently, in his opinion, trophoneuroses. The two conditions are therefore probably related, even if the disease manifested by enlargement of the bones of the face is not actually osteitis deformans, beginning in the facial bones instead of in those of the extremities and cranium. He presented an illustration of the face of the young woman. ("Deformities of the Face." By John B. Roberts. Second Edition, 1901, p. 19.)

Now he reported a case of typical osteitis deformans occurring in a man. The patient, sent to him about a year ago by Dr. H. E. Schlemm, had applied to that physician because of his increasing loss of stature, which had attracted the attention of his friends; otherwise he had, in his own opinion, no special symptoms of illness, except that he had been of late somewhat below par in general health. The bony lesions, other than the diminution of height, had been unobserved.

The gentlenian, who was aged forty-seven years, and un-

married, knew of no family history of gout or rheumatism, and had no definite knowledge of any condition similar to his in his ancestors or collateral relatives. His father's father had died at the age of eighty years of cystitis; his father's mother at the age of eighty years of dropsy; his mother's father at sixty of dropsy, and his mother's mother at eighty-two of dropsy. He knows of no instance of bandy-legs or bow-legs in the family, except that his father's father just mentioned is said to have become bow-legged as he increased in age. His father had died at the age of sixty-two years of what was called heart-failure, although there was also a history of some kidney disturbance. Some of the friends of the family say that his father before death walked like the patient. The latter, however, does not know that his father became shorter in stature, but says that he became very bent and stooped. His mother still lives at the age of seventy-two years and is in good health.

The patient has living at this time two sisters and three brothers in good health. One brother died of dropsy at the age of thirty-nine. Ten years previously he had received a shock by falling at a roller-skating rink and fracturing one arm. The patient does not know which arm, or whether the injury was above or below the elbow. Later he had suffered from an injury to the right hip, but there was no fracture at that region. During the ten years from the time of the receipt of the fracture of the arm and his death he gradually became weaker, and had to be rolled about in a chair for three or four years; but he was not paralyzed in the legs. The man was dropsical and swollen, and it gave pain to lift him, so that some sort of apparatus was made by which he could be lifted by the attendants.

The present patient does not know that this brother had any tendency to stiffness of the joints at this time, nor that there was any tendency for his bones to bend. The right side of the lower jaw was, however, swollen, and the patient thinks that this swelling of his brother's face was situated in the jaw-bone. He has no recollection of his brother complaining of pain in the jaw.

The patient is the eldest child of his parents. About fifteen years ago he fractured his left humerus about one inch above the elbow by being thrown from a street car. There was no cutaneous wound. The bone rapidly united, but he dates the beginning of his decline in health from the time of that accident. He

has never had any serious disease. There is no history of gonorrhœa or syphilis. He has never suffered from abscess and has never had scrofulous lesions, rickets, or typhoid fever. There is no history of ague, rheumatism, rheumatic pains, or jaundice.

About twenty years ago he had a boil upon his right thigh, but this lesion seems to have been unimportant. About ten years ago he weighed in the neighborhood of 160 pounds, and was about five feet nine and one-half inches in height. Now he measures five feet six and one-fourth inches with his shoes on, and weighs about 150 pounds. His physician says that the patient was very erect in his carriage.

Four or five years ago the patient's friends called attention to the fact that he was becoming shorter. He apparently paid very little attention to this symptom until recently. Since that time he has been taking a month's holiday each year, because he found that he was a little run down in health. His business has kept him a good deal confined to his office.

On examination the patient had a pallid, anæmic look, and gave the appearance of his arms and legs being too long for his body. He said that he had no digestive disturbance, was not constipated, and was temperate in eating and drinking. According to his own statement, the color of his skin was better than it had been for several years. Examination of the lungs was negative, as was that of the heart, except that there seemed to be a systolic murmur, possibly attributable to the excitement of the examination. He, however, said that he got easily out of breath from going upstairs, and that when he walked his knees felt weak. There had been no hæmoptysis. His urine was acid, had a specific gravity of 1026, and was free from albumen and sugar.

He used glasses for reading and had a slight degree of hyperopic astigmatism, his refraction being plus .75 sphere combined with plus .75 cylinder axis 90 in each eye. His hearing and teeth were good. He himself had no knowledge of his change in stature until his attention was called to it by his friends, though he had been feeling that he was not quite up to his general standard of health.

When the patient was stripped, the normal hollow of the back in the lumbar region was gone, and the spine in that location bulged backward just above the sacrum so as to change the normal lumbar concavity into a slight prominence backward.

This change was not at all like the angular deformity which occurs in tubercular spondylitis, but was a general bulging backward of the whole region. The femurs, especially the right one, were unnaturally convex forward and perhaps bowed a little outward. The right clavicle, which had never been fractured, was massive, being at least twice as thick as the left clavicle, which seemed to be of normal shape and size. The left humerus was very much thicker than the right, especially in the lower half of the shaft and the condyles. This was the bone which had been fractured years previously, but the enlargement is a general one, and not like that at the seat of an old fracture with displacement and callus. The enlargement of this bone existed in the upper portion to a less extent than in the lower portion. The left tibia had a distinct enlargement in the region of the tubercle, which extended downward in a promontory-like mass upon the front of the bone. The rest of the tibia was normal in size and shape.

There was no stiffness of the joints. There were no gouty deposits in the fingers, toes, or ears. There was no rachitic rosary upon the ribs, and no rachitic-like deposits at the wrists or ankles. Because of the bending of the lumbar region of the spine, the lower ribs and the crests of the two ilia were only about a finger's-breadth apart.

The head looked very big at the back, though he had not been aware of this peculiarity until asked whether he had recently been obliged to increase the size of his hat. He then said that about two years ago the number of his hat was $7\frac{1}{4}$, whereas now it was $7\frac{1}{2}$. There was no enlargement of the jaws or facial bones nor of the hands or feet.

In an article by Dr. J. C. Wilson, in the *Philadelphia Medical Journal* of the early part of this year, it is stated that up to that time there had been but seventeen cases of osteitis deformans reported as observed in this country. Hence the report of the present case, which shows most of the typical symptoms, and differs from most of the cases reported only in the circumstance that the kyphosis, or bending backward of the spine, occurred in the lumbar rather than in the cervicodorsal region.

The pathology of the condition is interesting. Microscopical examination shows absorption of healthy bone and formation of new bone coincident with this absorption, but apparently not con-

nected with the absorptive process. The new bone may show a failure of calcification, may itself become absorbed, or may finally become calcified. The condition appears to differ from osteomalacia, because synchronously with the absorption of the bone a process of regeneration takes place, and because, instead of fracture occurring, the bones have a tendency to bend as in rickets. The statement that leontiasis ossium affects the bones of the face only, and not those of the cranium or extremities, does not seem to be verified. On the other hand, some cases of osteitis deformans, it is said, show hypertrophy of the bones of the face as well as of those of the cranium, which is the region of the head that ordinarily is affected. It seems probable that there is some relation between these two conditions and the common disease called osteo-arthritis, rheumatoid arthritis, and rheumatic gout. Acromegaly differs from the conditions under discussion, at least in its clinical manifestations, because in it the enlargement occurs in the feet and hands as well as the head, and seems to involve the soft parts as well as the bones. From a study of the recent articles on the subject, Dr. Roberts was inclined to believe that osteitis deformans is a nutritive or trophic disorder, due, as suggested by Prince (*American Journal of the Medical Sciences*, 1902, Vol. cxxiv, p. 796), to a modification or perversion of the natural processes occurring in normal bones.

DR. DE FOREST WILLARD said that, owing to the rarity of this condition, no one physician had the opportunity to make a clinical study of many cases. He has seen but two cases, both being aged women. The pathology of the affection is uncertain. Dr. Willard believes that rheumatoid arthritis, osteitis deformans, and leontiasis ossea are in some way related to each other. In all there is a tendency towards the deposit of extra bone and the production of deformities. When the pathology of the conditions in question is ultimately worked out, it will probably be found that, although dissimilar, they all belong to one general group.

DR. WILLIAM J. TAYLOR mentioned a case of leontiasis ossium that involved the frontal bone. A mass of the new formed bone varying from one to two inches in thickness was chiselled away by Dr. Keen. This bone was subjected to a very careful microscopic examination, which revealed no definite structure other than that of normal bone. The patient made a good recovery from the operation, but whether recurrence followed is not known.

DR. HENRY R. WHARTON had seen two cases of osteitis deformans, one of which, occurring in a man, was under the observation of the late Professor Ashhurst and himself during more than ten years. The second case was in a woman forty years of age. Among the points of interest in these cases is the diagnostic importance of a gradually diminishing stature. This change is largely due to curvature of the bones of the thigh and leg, but changes in the spine also aid. This curvature also involves the bones of the upper extremity, including the clavicle. Another interesting point was the slight impairment of general health in both cases mentioned. The one under observation for ten years showed no failure of his general condition. The other patient was seen only for a short time, but her health was then good. As to treatment, nothing seems to be of avail. The man was for months given potassium iodide without producing any effect.

SUBACUTE INTESTINAL OBSTRUCTION.

DR. W. J. HEARN said that many cases were brought to the Jefferson Hospital to be operated on for a supposed obstruction of the bowel which really does not exist. The history of such cases is usually as follows: The patient has probably had an attack of acute indigestion with pain, and, as happens too often in such cases, morphine has been administered to relieve the pain. Then follows the necessity of opening the bowels which the morphine has constipated. Frequent doses of purgatives cause the patient to vomit; enemas are given which only wash out the lower, but do not relieve the upper, bowels, and soon the patient is supposed to have obstruction of the bowel. But certain important symptoms that indicate genuine obstruction are wanting. There is no temperature; the pulse is almost normal; it may be somewhat rapid, but that will be due to the excitement and apprehension suffered by the patient on finding the bowels cannot be opened. There is but slight distention of the abdomen. There is no muscular tension of the abdominal walls. There are no points of tenderness nor general tenderness over the abdomen. In these cases Dr. Hearn usually recommends a cessation of attempts to evacuate the bowels. He simply permits the patient to rest without any medicine at all, and soon nature rights itself. Many cases of appendicitis or general peritonitis from any cause whatever are mistaken for obstruction, but the lack of abdominal

distention and the presence of the usual symptoms of appendicitis and peritonitis reveal the cause of the trouble. Persistent vomiting, great abdominal distention, and inability to pass any gas whatever through the intestines, and, later, great tenderness, a rapid pulse, and a significant facial expression indicate, as a rule, acute obstruction, and if there be fecal vomiting, which is usual, the diagnosis is complete. But in the subacute and chronic obstruction the diagnosis is much more difficult. Then the surgeon confronts a question of great gravity and peril to the patient. In these cases the obstruction is not at first complete and the symptoms develop more slowly. The abdominal distention is later coming on, and the patient is able to pass some gas from the bowels. By the time the symptoms are those of complete obstruction, the patient suffers either from general peritonitis or local gangrene of the intestines, and the prognosis, as is well known, is much more unfavorable than in the acute cases. These facts are demonstrated in four cases now reported, as follows:

Intestinal Obstruction due to an Enterolith in the Small Intestine.—A patient of Dr. Kollock, of Newark, Delaware. A woman, aged sixty years, well nourished, abdomen very fat, without previous history of colic of any kind whatever. She was attacked with colicky pains in the lower portion of the abdomen. Up to the time of this attack the bowels had been opened as well as usual as far as she knew. The pains were at first accompanied by vomiting the contents of the stomach and afterwards bile and mucus. Then the vomiting would cease, and two days would elapse before it would occur again. On the seventh day after the first attack she vomited fecal matter for the first time. She was able to pass flatus through the intestinal canal and with some relief to the pain, but no fecal matter. On the tenth day, when seen by Dr. Hearn, she was suffering considerable abdominal pain, but there had been no vomiting at all on that day. There was moderate distention of the abdomen and a more rapid pulse than normal. The area of tenderness on pressure was in the right iliac region. Laparotomy was advised on the basis of the vomiting of fecal matter which had occurred. No other symptoms were present to justify it, with the exception that her bowels had not been opened. An incision was made in the middle line and the parts were explored by the sense of touch. In doing so the hand accidentally came upon a mass in the ileum

about eighteen inches from the ileocæcal valve. This mass was delivered through the abdominal incision, and by palpation appeared to be the size of a hen's egg. It apparently filled the entire lumen of the bowel and was immovable. There were areas of gangrene in the peritoneal coat, also areas of gangrene in the mucous membrane of the bowels. As these areas were apparently in a straight line, an incision was made into the bowel through these areas of gangrene about two inches long and the concretion removed. The mucous membrane was closed first and then two rows of Lembert sutures through the peritoneal coat, thus inverting the gangrenous areas. The patient made an uneventful recovery. Nausea all ceased, and the bowels were opened on the second day voluntarily without any laxative. The enterolith has been examined chemically by Dr. Stellwagon, who gives the following report. "The concretion had for its base biliary calculus composed of cholesterin and fatty crystals surrounded by triple phosphates." While this stone has for its nucleus a biliary calculus, yet the patient gave no history of ever having had an attack of colic. Of fifty-one cases of intestinal obstruction caused by the impaction of gall-stones, collected by Wissing, thirty-eight died. In some of these cases the calculi were of great size. In the cases reported by Smith and Fagge they measured four and one-half by two and one-half inches in circumference. In all cases enterotomy should be performed at once, and no attempt should be made to crush the enterolith in the lumen of the bowel, as has been suggested by some. The method suggested by Tait, of passing a stout steel needle obliquely through the intestinal wall and attacking the calculus in order to break it up, is not worthy of approval.

RICHTER'S HERNIA; LOCAL GANGRENE; PERITONITIS AND DEATH AFTER OPERATION.

Miss P., aged forty-two years; well nourished, of rather large stature, previous health always good. Eight days before admission to the Jefferson Hospital she took an overdose of an expectorant mixture for a cold. It nauseated her and caused intense straining in the attempt to vomit. While straining in the effort to vomit, she suddenly felt a sharp colicky pain over the entire abdomen. She then vomited the contents of the stom-

ach. On the following day there was no vomiting. Nausea was somewhat relieved, but there was no cessation of the pain, nor were her bowels open, notwithstanding she was given very active purgatives. On the fourth day the abdomen began to swell, and Dr. Hearn saw her then for the first time with Dr. Piper, her attending physician. Obstruction of the bowel was not then suspected, as the vomiting had apparently ceased. The groins were examined for hernia, but none was found, and she insisted she had never suffered from hernia. On the evening of the seventh day the vomiting commenced again, and was of a fæcal character. When Dr. Hearn saw her again, the next day, there was every evidence of general peritonitis; constant vomiting, rapid pulse, temperature 101° F.; a general tenderness over the entire abdomen, but no defined area of tenderness, with a facial expression that of general peritonitis. She was at once transferred to the Jefferson Hospital and operated the same day. An incision large enough to permit the entrance of the hand was made below the umbilicus. In carrying the hand down the side in the right iliac region, a portion of the intestine was found fixed in the right femoral canal. This was carefully detached from the point of adhesion and brought outside the abdomen. A portion of the bowel delivered presented the appearance of a large nipple and was gangrenous. Some of the contents of the bowel had escaped into the abdomen through the gangrenous tip of this nipple-like projection. About half of the lumen of the bowel had been drawn into the ring, and its width on the length of the bowel surface was about one inch and a half, culminating in a point. As the larger portion of this nipple was gangrenous, it was necessary to perform a resection of the bowel. Her condition was alarming, and, as it was necessary to terminate the operation quickly, a Murphy button was used. The abdomen was thoroughly washed out with a salt solution, and closed in the usual manner with a drainage in the lower angle of the wound. During and after the operation her pulse was 140 and her temperature rose to $103\frac{2}{5}^{\circ}$ F. The patient died the following day of general peritonitis.

SUBACUTE OBSTRUCTION CAUSED BY MECKEL'S DIVERTICULUM; OPERATION; DEATH.

Mrs. S. W., aged fifty-six years, for twelve years had suffered from occasional attacks of intestinal colic, accompanied by constipation and followed by diarrhoea, which would last for a week or ten days. On June 20, 1902, she was seized with pain in the abdomen, which was not localized to any particular region; during the following four days she had attacks of pain with intervals of complete freedom; the abdomen would become moderately distended and tender, and again these symptoms would disappear. Purgatives and enemas would bring away some faecal matter and gas, but no free bowel movement was produced. Temperature between 98.6° and 100° F.; pulse between 80 and 90. Her family physician, Dr. Henry Lovett, of Langhorne, called Dr. Hearn to see her on the day after she was taken ill, but owing to his absence from the city his assistant, Dr. Roe, saw her on the second and third day, and they both saw her on the fourth day. Unfortunately, about the time of their visits, her symptoms had improved, and, as she was and had been a very delicate woman for many years, and as she had passed through very similar attacks previously, and more especially as her importunities not to operate if we could possibly avoid it were great, a waiting policy seemed justified. During the night of the fifth day her abdomen became distended and vomiting began, which soon became stercoraceous. The following morning the abdomen was opened by an incision through the median line; the intestines were found injected with some serous effusion in the peritoneal cavity. While exploring the posterior abdominal region, there came into view a short obliterated diverticulum, having a short mesentery, coming from the right side of the ileum about twenty inches from the ileocaecal valve and crossing over the free border and adherent to the posterior parietal peritoneum. The diverticulum was divided between a distal and proximal ligature which included its mesentery. The intestine was then liberated and showed the point of constriction, which, however, did not require any repair. Although the symptoms of obstruction were relieved, the patient died four days later of general peritonitis, following the usual course of chronic obstruction.

GANGRENOUS RICHTER'S HERNIA RESULTING IN INGUINAL ABSCESS; INCISION AND DRAINAGE; SUBSEQUENT RESECTION AND ANASTOMOSIS OF THE ILEUM; RECOVERY.

A man, aged sixty-eight years, consulted Dr. Hearn, July 26, 1896, for a large phlegmon of the right groin. Previous to the present illness he had an attack of enteric fever at the age of twenty-five years, and twelve years before he had an enlarged gland in the right groin, which disappeared under treatment, and very probably was a hernia. There was no history of injury or infection of the genitals. About four weeks before coming to Dr. Hearn he was seized with griping pains in the abdomen; in the meantime he observed an enlargement in the right groin; a week later it took on growth and steadily increased. The skin over the enlarged area in the groin was dusky, pain throbbing, tension marked and fluctuation. He was admitted to the hospital and prepared for immediate operation. Upon incising the abscess it was found to contain about ten ounces of an admixture of pus and bowel contents. At the site of the femoral canal there was a small opening which communicated with the bowel. The cavity was irrigated and tamponed with iodoform gauze. A faecal fistula remained after the abscess healed, and six months later he re-entered the hospital. On the following day Dr. W. J. Roe opened the abdomen, and after freeing the bowel did a resection and end-to-end anastomosis, using Halstead's rubber bobbins. Recovery was uninterrupted and uneventful.

DR. JOHN B. ROBERTS referred to two specimens of intestinal calculus that he had placed in the Mütter Museum. One of them was passed by a physician after an attack of acute pain in the epigastric region which had not yielded to treatment. Surgical advice was contemplated, but before it was obtained something was felt to give away in the abdomen, and two days later a large calculus, together with a piece of sloughed tissue, was passed from the bowel. The second specimen referred to by Dr. Roberts was a calculus, one by three inches in size, which he removed from a woman who had had severe constipation during many years, and secured movements by rectal enemata. The calculus, which was located near the ileocaecal valve, was removed by enterotomy, and the patient soon afterwards died, al-

though there were many reasons to believe that she would recover. This case was interesting because of the history that many years before the patient had suffered from some affection that produced jaundice. At the time of operation the hepatic region was explored, with the result of finding adhesions about the liver, but no trace of the gall-bladder. The nucleus of the calculus, which has never been opened, is believed to be a gall-stone which ulcerated its way into the intestine years before.

DR. JOSEPH M. SPELLISSY reported that in his service at St. Joseph's Hospital, and assisted by Dr. Davis, he had removed an enterolith having as its nucleus a common pin. The condition leading to interference existed for months, caused little distress, and consisted of an apparent thickening of the anterior and internal margin of the right iliac bone. While the density of the mass suggested it to be a new growth, its late characteristics pointed to a possible inflammatory origin. Incisions close to the iliac crest passed through an inch thick, apparently fibrous mass, into a small extraperitoneal abscess close to the bone, and containing the spindle-shaped enterolith. A persisting faecal fistula marred an otherwise uneventful recovery. This fistula was later operated upon during the service of Dr. Davis and by him.

DR. JOHN H. GIBBON said that in the majority of cases of chronic obstruction of the bowels the large intestine was the site of the lesion, and that the cause of the obstruction producing subacute or chronic symptoms was usually a malignant growth. These patients, however, were generally admitted to the hospital for a complete obstruction following previous attacks of subacute obstruction. When operating on such cases where the obstruction is complete and the patient's condition is not good, it is thought to be better surgery to relieve the obstruction by performing colostomy rather than to do an immediate resection. Littlewood, in a recent article in the *Lancet*, has shown the great advantage to be derived from pursuing the former plan of treatment. Gibbon referred to a case of complete obstruction of the bowel due to a cancer of the sigmoid, in which he did an immediate resection and lost his patient. He believes that this patient might have been saved had he done a left inguinal colotomy and later resected the bowel.

EXCISION OF THE CONDYLE OF THE LOWER JAW FOR
BONY ANKYLOSIS OF THE TEMPORO-
MAXILLARY JOINT.

DR. FRANCIS T. STEWART presented a girl, aged six years, who twenty-two months ago was attacked by severe pain in the lower jaw and convulsions. The face swelled, pus escaped into the mouth, and five teeth were extracted without relief. Four months later some carious bone was removed from the lower jaw by an external incision. He first saw the child fifteen months ago at the Polyclinic Hospital. She then presented a complete ankylosis of the jaws and two sinuses on the right side, one near the chin and one near the angle of the lower jaw. An incision was made along the body of the jaw connecting these sinuses and a sequestrum the length of the body of the jaw removed. The wound resulting from this operation gradually contracted to a small sinus, but there was no improvement in the ankylosis, it being impossible to move the jaw in any direction. The region of the right temporomaxillary articulation was occupied by a swelling having the consistency of bone. September 28, 1903, the patient was etherized, a scab of collodion placed over the old sinus, and a small vertical incision made over the joint, the parotid gland and the temporofacial fibres being retracted towards the ear. The condyle could not be defined, a mass of bone continuous with the zygoma and glenoid fossa occupying the usual situation of the joint. The neck of the condyle was severed with a chisel, and as much condyle as possible was gouged from the joint cavity. Just at the completion of the operation, a large vessel was severed, and it became necessary to pack the wound. Two days later the wound was sutured except at the lower end, at which point a sinus still persists. Immediately after operation the patient was able to open her mouth to the normal limit. She now eats solid food with comfort and has a jaw as freely movable as a normal jaw. There is a slight palsy of the orbicularis palpebrarum, which will probably disappear, as the temporofacial fibres were simply stretched and not severed.

DR. DE FOREST WILLARD gave a brief history of a case upon which he operated three weeks ago. The patient was a child who two or three years before had fallen while playing and

had run a pointed stick into its mouth. The result was the repeated formation of abscesses which opened in a number of places on the cheek and near the ear. After some months a piece of wood was discharged from the temporal region, and healing of the sinuses followed. For two years nothing had been done to restore motion to the jaw, and the incisor teeth could be separated only one-fourth inch. From the history it was believed that interference with motion came principally from cicatricial contraction of the masseter and temporal muscles, and that myotomy of at least the masseter would be necessary. After etherization of the patient, screw power was inserted between the teeth, and the yielding was so marked that cutting of the masseter was dispensed with. By steady pressure the jaws were separated one and three-fourths inches. Now, at the end of three weeks, the mouth can be fully opened and mastication is nearly normal.

RUPTURE OF THE BRANCHES OF THE MIDDLE MENINGEAL ARTERY BY CONTRECOUP.

DR. STEWART related the history of a man, aged forty-five years, who was struck on the head by a weapon, and admitted to the Polyclinic Hospital in an unconscious condition September 19, 1903. There was a compound depressed fracture of the right parietal bone and a paralysis of the right arm and leg, but not of the face. The pupils were moderately dilated and reacted sluggishly to light. The depressed fragments of the right parietal bone were removed and a piece of gauze packed against a small opening in the longitudinal sinus. The left parietal bone was trephined and a clot of blood measuring about two inches in thickness and about four inches in length was found separating the dura from the skull and compressing the brain. The clot was evacuated and the cavity packed with gauze, the bleeding apparently coming from a number of small vessels. The paralysis entirely disappeared by the third day, but the unconsciousness continued for two weeks. One week after operation there were a number of severe general convulsions; after reopening the wound on the left side and evacuating a large clot which had reformed, the convulsions ceased. The patient is now perfectly well, both mentally and physically.

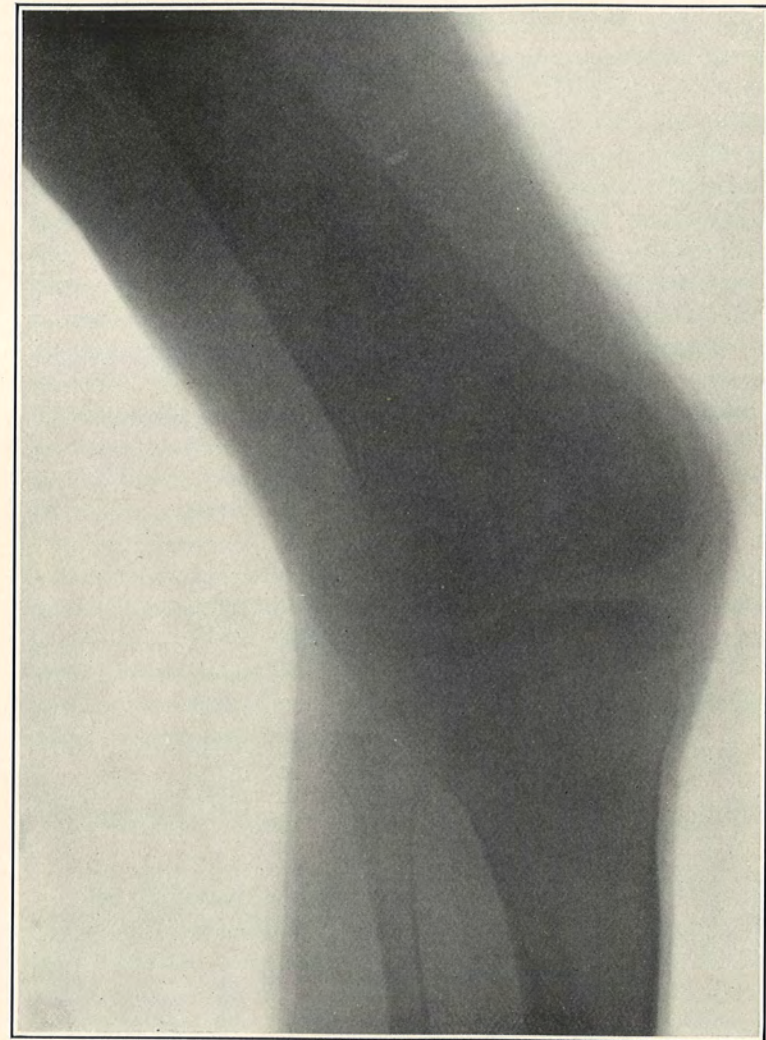


FIG. 1.—Congenital dislocation of patella.

DR. G. G. ROSS mentioned a case in which there was rupture of branches of the middle meningeal instead of the main trunk. He packed the area with gauze for three days, and there was no further trouble. He operated in three hours after the injury, though there were no symptoms, because of a depressed fracture. A clot of considerable size was found.

DR. JOHN H. JOYSON cited a case of meningeal hæmorrhage under his care one year ago in which there was rupture of the middle meningeal artery, but no accompanying fracture. He explains the so-called rupture by contrecoup by the fact that adhesions of the dura mater are weak in the region of the middle meningeal artery. Tension on the branches of the vessel at the time of injury, especially after a blow, may be great enough to cause rupture. Fracture of the skull may not occur, the artery being ruptured by the springing back of the bone. This he is inclined to think was the cause in Dr. Stewart's case. This form of rupture is apt to involve the branches instead of the main trunk of the vessel, and hence might easily account for the hæmorrhage from several places.

DR. HENRY R. WHARTON believes that, in packing to control hæmorrhage from the middle meningeal or the sinuses, the gauze is generally left in for too short a time. He has made it a rule to leave the packing in from five to six days or even a week if the wound remains sterile. The late removal of the packing is usually not followed by any considerable bleeding, as is the case where it is removed at an earlier period.

CONGENITAL DISLOCATION OF THE PATELLÆ BRACHY- DACTYLIA.

DR. STEWART presented a man, aged thirty-nine years, who came under observation at the Pennsylvania Hospital for fracture of the radius. His ancestors were German. His parents, two sisters, two brothers, and all his relatives are normally formed, excepting one first cousin, who has six toes on one foot. He is five feet high, of fair intelligence, is dolicocephalic, has a slight exophthalmos, brows slanting upward in Mongolian fashion, and a high arched palate. All the digits of both hands and of both feet are abnormally short, being about two-thirds the normal length. All the fingers of both hands except the

index and little, which each have two phalanges, have three bones, as shown by the skiagraph. By palpation only two bones can be distinguished in each finger. Each thumb exhibits three irregularly shaped bones and a sesamoid in place of the phalanges. The ring and middle fingers of the left hand are webbed to the end of the proximal phalanx. Each foot has six toes, all of which are webbed, and each toe has two phalanges. The accessory toe has two large phalanges and a small metatarsal bone which articulates with the internal cuneiform. The internal cuneiform bone is larger than normal and projects well below its usual level. The middle and external cuneiform bones cannot be seen in the skiagraph, the two middle metatarsal bones apparently articulating with the scaphoid. The patient has knock-knees, and when standing the patella rests on the external surface of the external condyle, the internal edge looking forward, the anterior surface facing outward. When the leg is flexed the patella passes farther outward and backward until it touches the head of the fibula. The skiagraphs were made by Dr. Francis Allen, of the Pennsylvania Hospital.

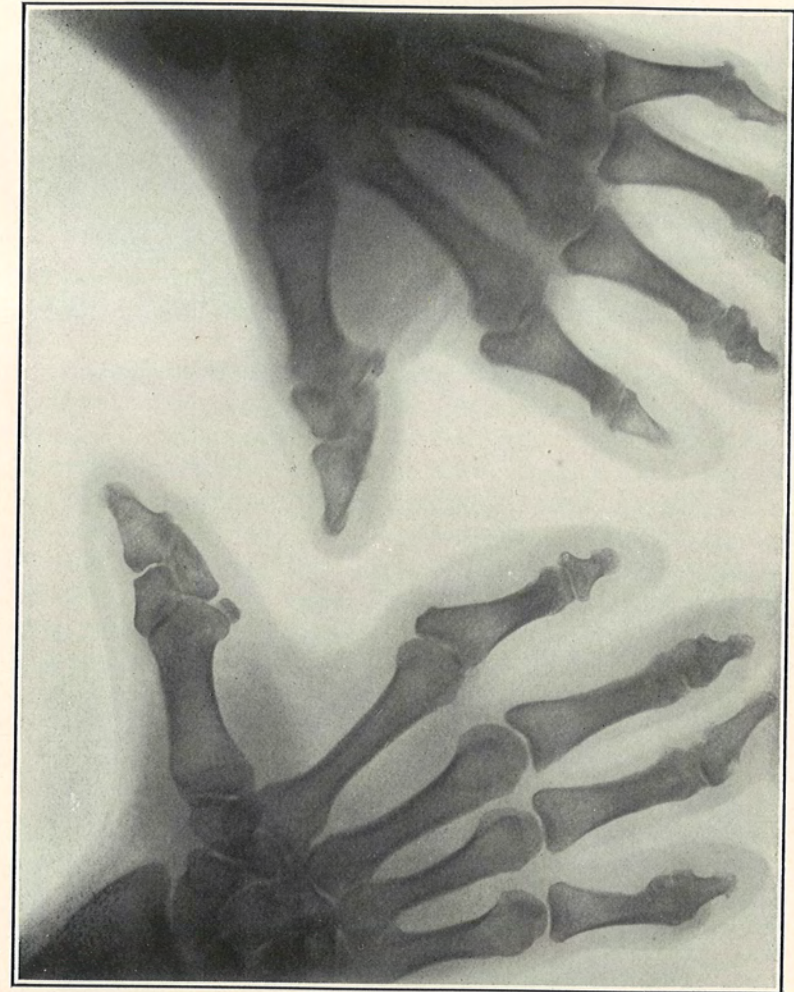


FIG. 2.—Malformation of hands. "Brachydactylyia."

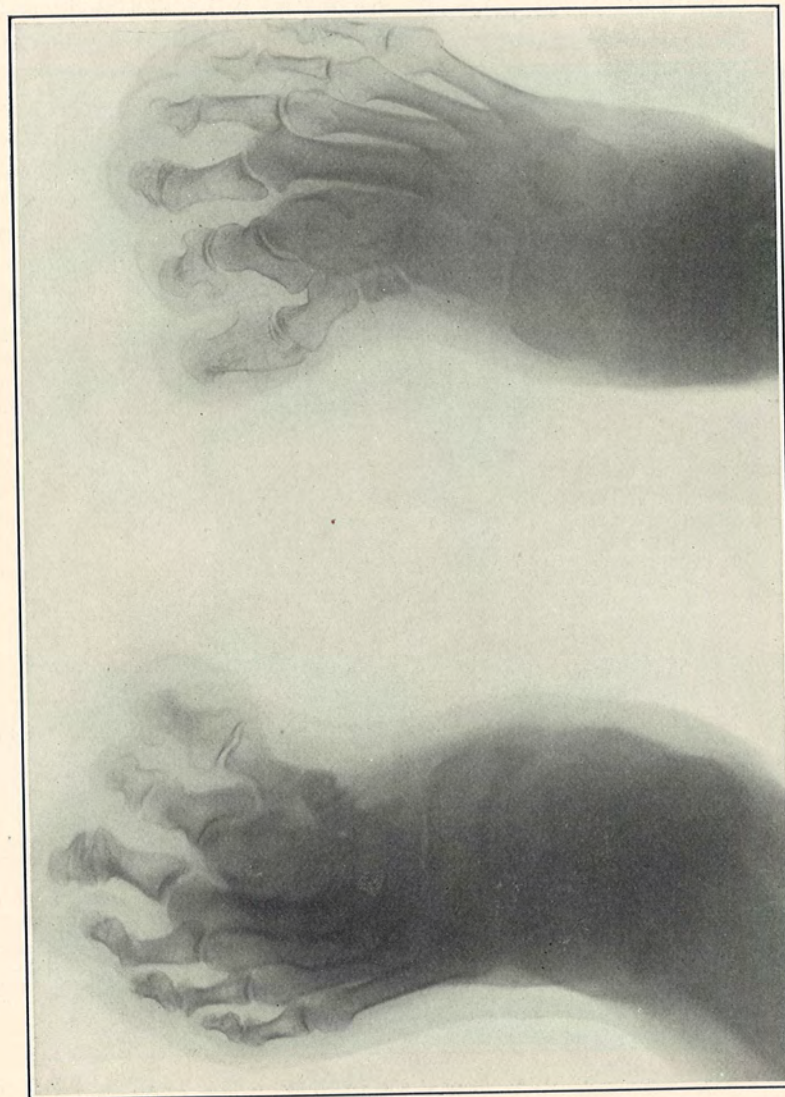


FIG. 3.—Malformation of feet. "Brachydactylia." Supernumerary Toes.

STATED MEETING, DECEMBER 7, 1903.

The President, RICHARD H. HARTE, M.D., in the Chair.

CHOLECYSTOTOMY.

DR. LEWIS W. STEINBACH presented three patients who had been subjected to operation for cholelithiasis.

The first case was a woman, aged forty years, who was admitted to the Polyclinic Hospital, June 17, suffering since one o'clock in the morning with intense abdominal pain, which could not be relieved by hypodermic injections of morphine administered within the limits of safety. There was vomiting, tenderness over upper half of the abdomen, and a slight yellow discoloration of the scleræ. An immediate operation was decided upon. The patient was anæsthetized with ether. A long incision through the abdominal parietes exposed an enlarged, tense gall-bladder, in which no stones were felt until after evacuation of the fluid contents by means of a trocar. The fluid evacuated approximated eight ounces in quantity and resembled normal bile. The neck of the bladder contained three gall-stones, while a fourth was separated by a valve-like partition and was removed with some difficulty, the thumb and forefinger of the right hand steadying the cystic duct while the left hand manipulated forceps or scoop. The stones were globoid with facets, were of almost equal size, each one having about three-fourths of an inch in diameter. A sound was passed into two branches of the hepatic duct and into the common duct without detecting other calculi. In order to verify this condition, a colleague probed the biliary passages and perforated the common bile duct. An elongated gauze pad was placed in contact with the perforation in the common duct, a large rubber drainage tube was inserted into the distended cystic duct and stitched with the edges of the incision in the gall-bladder to the parietal peritoneum at the lip of the abdominal incision; the sutures were permitted to remain long. Three additional stitches secured the gall-bladder to the peritoneum.