

STATED MEETING, HELD NOVEMBER 5, 1906.

The President, JOHN B. ROBERTS, M.D., in the Chair.

LAMINECTOMY FOR TUBERCULOSIS OF THE SPINE.

DR. JAMES K. YOUNG presented a girl, 14 years of age, who, on February 7, 1902, fell on the ice, striking the dorsal region against a step. Two months later, she was sent by her attending physician to the Orthopædic Hospital and a brace was applied. In the spring of 1903 she was admitted to the University Hospital for beginning loss of power in the lower limbs. Subsequently she was admitted to St. Joseph's Hospital and to the Polyclinic Hospital. In January, 1906, she was admitted to St. Joseph's Hospital under his care, and he performed a laminectomy the day following her admission. Throughout all this time from the date of the accident to the time of operation her condition had progressed steadily worse, with slight intervals of improvement. The 8th, 9th, and 10th vertebræ were involved; there was a marked kyphosis, and paraplegia came on early and was intermittent, but steadily growing increasingly worse. Fourteen months before the operation her limbs became spastic and she had exaggerated knee jerks, marked ankle clonus, and Babinsky reflexes on both sides, with at times crossed reflexes. There was still some motor power. The following month, November, 1904, she could walk around the bed holding on for support, but rather awkwardly. One week later she could walk alone, and there was great improvement.

She again relapsed after this, and in April, 1905, upon her admission to the Polyclinic Hospital, she was completely paralyzed and there was slight incontinence. In July, 1905, there was complete motor paralysis with slight incontinence which increased until at the time of the operation there was complete incontinence and complete motor and sensory paralysis.

On January 19, 1906, an incision five inches long was made from the third to the eleventh vertebra, the spinous processes of the ninth and tenth vertebræ were removed, and the lamina of the ninth vertebra was removed. An abscess was found beneath

this on the right side which was opened and drained. A catgut drain was inserted and the wound closed, except for the drainage.

On February 26 the sensation in the lower extremities was slightly delayed but was present on both sides, and slightly hyperesthetic. The patellar reflexes were exaggerated, ankle clonus was present on both sides, the left more marked, and Babinsky reflexes were present on both sides and were marked. There was some contraction of the right knee at this time. Thermal sensation was diminished.

She was treated with electricity and massage and sent to the seashore. The motor power has gradually improved, the abscess has closed, and she is now able to walk a short distance unassisted, and has regained perfect control of the bladder and rectum.

Dr. Young said that two points were illustrated by this case, first, the diagnosis of abscess by the intermission of symptoms, improvement and relapses; second, the possibility of recovery by means of the operation of laminectomy after complete loss of motion and sensation.

He did not share the ultra-conservative opinion expressed by some surgeons in regard to laminectomy, but believed that under certain conditions this operation is a justifiable one. For abscess pressing upon the cord and for early spastic contractions of the extremities he believed the operation should be performed earlier than is customary.

DR. HENRY R. WHARTON said the case reported by Dr. Young was eminently one for laminectomy, the presence of an abscess in the spinal canal showing that the patient's condition was hopeless without operation. Simple rest in some cases of Pott's disease results in restoration of motion and practical recovery, but in others laminectomy is the only alternative. The diagnosis of abscess is difficult; as pointed out by Dr. Young, intermissions in improvement are a valuable sign in this respect.

DR. YOUNG, in closing, said the crossed Babinsky reflex was the unusual feature of the case. Usually this sign is present on one or both sides. Here it was present on both sides and irritation of one foot caused the reflex on the opposite side.

TRUE DOUBLE LOWER LIP.

DR. JOHN B. ROBERTS presented a patient upon whom he had operated for the removal of a true second lower lip. The photo-

graph (Fig. 1), taken before operation, showed the double lip to consist of a thick outer lip and a thinner internal structure separated from the outer by a deep fossa lined with mucous membrane. In the median line of the mouth the two lips were fused together at the vermilion border and downward to the attachment of the structure to the alveolar portion of the mandible. The inner lip was dissected from the outer and incised. The raw surface was then covered by drawing flaps of mucous membrane over it. The patient's curious anomaly was corrected and his appearance much improved.

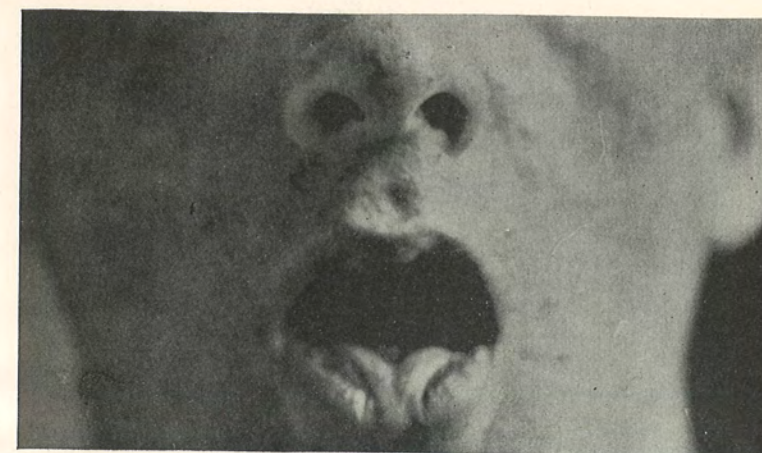
EXCISION OF HALF OF THE LOWER JAW AND HALF OF THE TONGUE FOR EPITHELIOMA.

DR. H. S. CARMANY exhibited, by invitation, a patient on whom he had operated one year previously for carcinoma of the tongue and jaw. The disease was of three months duration, and extended from the under surface of the tongue to the alveolar process of the inferior maxilla on the right side, and from a little beyond the median line to the last molar tooth. It was painful and growing rapidly, and the cervical glands were enlarging on the same side. Dr. Carmany excised the lower jaw on the right side from just below the sigmoid notch to a point a little beyond the median line, and with it the right half of the tongue, the submaxillary gland and a few small cervical lymph glands. The wound healed kindly, and the man has remained in good health. Dr. Carmany asked the opinion of the Fellows as to the advisability of applying a dental splint in these cases.

DR. CHARLES F. NASSAU said that one should never operate on carcinoma of the lower lip, tongue or jaw without taking out the glands of the neck. Twelve years ago Dr. Nassau operated in this manner upon two patients and five years afterward both were still free from recurrence. In any extensive growth of the jaw there is almost surely infection of the neighboring glands before they are palpable. Their removal is just as necessary as in connection with carcinoma in other portions of the body where the lymph channels are followed in the dissection. In Dr. Carmany's case life has undoubtedly thus been prolonged.

DR. CHARLES H. FRAZIER said, in response to Dr. Carmany's inquiry regarding the use of dental splints in connection with partial resections of the lower jaw, that it had been his habit in his clinic at the University Hospital, always to consult a dentist

FIG. 1.



Double lower lip.

prior to the operation. Dr. Cryer or one of his assistants had always been kind enough to examine the case before the operation and construct a temporary splint, which was applied at the completion of the operation. A permanent splint in the meantime may be made and adjusted after the wound is healed. By adopting this method the disfigurement accompanying the removal of the lower jaw may be largely, if not altogether avoided.

DR. JOHN B. ROBERTS said that he had seen a case of this kind in which Dr. McBurney had a dental appliance made before operation. It was held in place by a spring and fitted so well there was almost no deformity of the part.

## RUPTURE OF THE KIDNEY.

DR. MORRIS BOOTH MILLER, by invitation, reported the history of a man of 31, a special officer of the B. & O. Railroad, who while chasing thieves fell, striking on his left side over the lower rib. He walked a distance of fifty feet before feeling faint. He then passed by urethra what appeared to be at least a quart of blood and twenty minutes later a second quantity containing many clots. While on his way to the Polyclinic Hospital on a street car he was obliged to leave the car and again pass blood and urine. He walked into the hospital where six ounces of blood were withdrawn by catheter. Dr. Miller saw the man one and one-half hours later. There was no shock but the side was rigid and tender and an indistinct dull mass could be felt in the loin. An oblique lumbar incision was made. A mass the size of two fists was revealed and opened, showing extensive hæmorrhage and rupture of the kidney. The two poles were separated and the finger could be passed between numerous small fragments into which the middle segment of the organ had been divided. This caused severe bleeding. Wicks of gauze were placed against the kidney in front and behind, and by pressure the poles were brought approximately together. The patient did well, hæmorrhage practically ceasing in five days though at two later periods blood appeared in the urine. The amount of urine passed was at first 22 ounces but soon rose to 30 and then to 40 ounces. On the seventh day the wound dressings showed the presence of urine which then leaked through the back for a period of two weeks, the quantity being estimated at 20 ounces a day. On the twelfth day the packing was all removed

and the opening finally healed. Suppuration was not present in the wound at any time. The temperature chart of the patient shows three rather sudden rises, probably due to cystitis as the bladder was frequently washed.

DR. HENRY R. WHARTON stated as his personal experience that conservative surgery of an injured kidney is good surgery. He knows of several cases in which there were symptoms of ruptured kidney, including hæmorrhage from the urethra and a mass in the side, and the majority recovered. Another class of cases is formed by those in which infection occurs and abscesses form in the loin or abdominal cavity. He has also seen several of this type in which urinary fistula followed opening of the abscesses, but these sinuses all closed spontaneously.

DR. CHARLES F. NASSAU agreed with Dr. Wharton that it is not always necessary to operate on a ruptured kidney; this accident is probably more frequent than generally alleged. One patient, a woman, undoubtedly had a severe kidney injury, as shown by a mass in the loin and bloody urine for several days. She recovered. A second case was seen in the absence of a hospital colleague and would have been subjected to operation had he not been going to return soon. The colleague waited and did not operate for ten days. By that time the patient had bled so much he died when under operation. Some days ago a man was kicked in the back by a horse, the injury being followed by hæmaturia with free blood in the abdominal cavity, as clearly shown by physical signs. The pulse increased rapidly and the abdomen was opened. A rent in the liver four inches long was found, but in addition there was blood behind the peritoneum and the kidney was found torn in half and absolutely loose from all surrounding structures. The kidney was removed and the man did well. He passed 35 ounces of urine on the third day. He then developed pneumonia and died in two days. If in cases of kidney injury hæmorrhage continues and other conditions do not prevent it, an incision into the loin is indicated. This has not even the danger of an abdominal section and will at least get rid of a hæmatoma which might otherwise become infected.

DR. JOHN B. ROBERTS described the case of a boy of 10 or 12 who was run over by a wagon, the wheel passing over his abdomen. He was brought to the Polyclinic Hospital where nothing definite regarding his condition could be determined.

There was pain in the abdomen as though due to local peritonitis but the abdomen was not opened. In two weeks all symptoms had disappeared and the boy was discharged. Two or three weeks afterward he came in with an enormous bulging mass in the right side which was dull and tender. An incision gave vent to limpid fluid and it was supposed that there had been rupture of a ureter or that a traumatic hydronephrosis had been tapped. Examination of the fluid led to the report by the pathologist that it was from a cyst of the pancreas. This appeared to the operator to be unlikely. Later the fluid that came from the drainage tube was examined and reported to be urine. Dr. Roberts does not know whether the fluid first obtained actually came from the pancreas and the later drainage from the urinary tract or not; but the boy recovered and is now perfectly well.

DR. FRANCIS T. STEWART regards the time before operation as the proper time for conservatism. If operation be necessary, radical procedure is then probably the best, as often the kidney will be found badly injured and had better be removed, although, of course, one must be guided by the conditions found. The dangers are hæmorrhage and sepsis. The two early indications for operation are a progressively increasing hæmatoma and constitutional symptoms of hæmorrhage. Usually these two go together. Sepsis is at times a later indication. Hæmaturia is not necessarily an indication for operation. His chief difficulty has been to make a correct diagnosis. In one case, that of a man injured by a crush, a large amount of blood was passed by the urethra, the abdomen was rigid and there was marked shock. Rupture of the bladder was suspected by Dr. Gibbon who also saw the case and Dr. Stewart believed the condition to be a rupture of the kidney. Incision revealed intact kidneys and bladder and a ruptured liver. In this case, although the man died of hæmorrhage from the liver, the pulse never rose above 100, though it was very weak. In another case, secondary hæmorrhage after an abdominal operation, a large quantity of blood was passed by the urethra though there had been no injury of the bladder, ureter, or kidney. A third case was that of a boy who had been kicked in the abdomen. The symptoms were those of an intraperitoneal lesion and no blood was found in the urine. Operation revealed no injury to the abdominal viscera but a ruptured kidney. The kidney was removed and the case terminated

satisfactorily. In several cases of moderate bleeding he has operated and afterward been sorry that he had interfered.

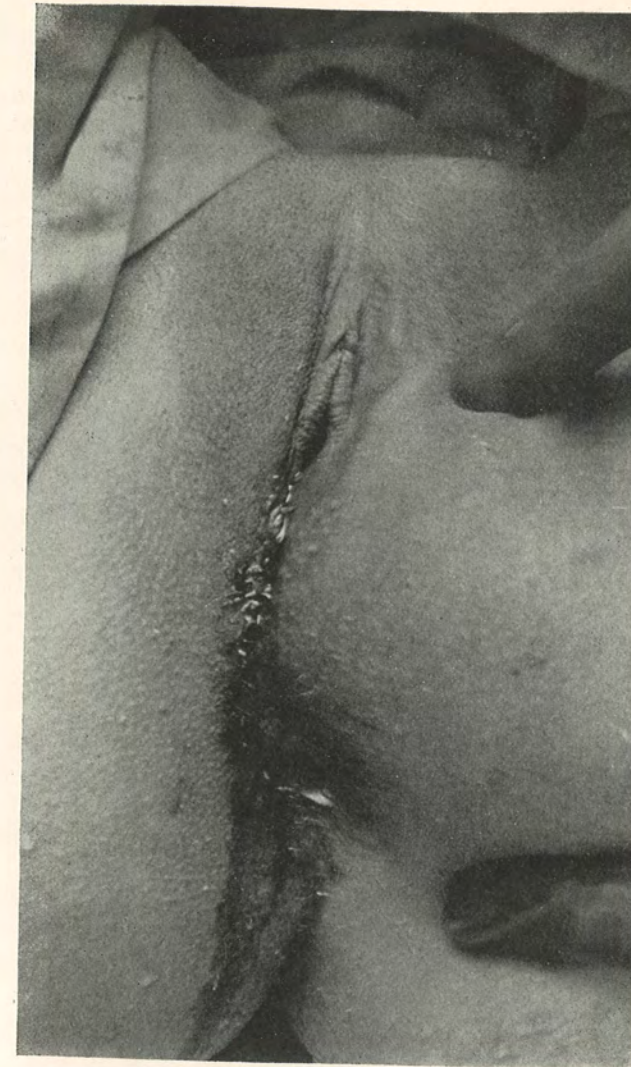DR. JOHN H. GIBBON said he saw the man referred to by Dr. Stewart and because of blood passed by the urethra regarded the case as one of probable rupture of the bladder. He agrees with Dr. Stewart as to conservatism in cases of injury of the kidney when hæmorrhage is not sufficiently severe to cause death. He does not agree with the statement that hæmorrhage severe enough to demand operation usually means an injury sufficiently extensive to require nephrectomy. The question of nephrectomy must be decided when the kidney is exposed. If the rupture extends into the pelvis of the organ and implicates large vessels the kidney should be removed. He has seen cases in which one-third of the kidney was separated from the remainder of the organ by blood clot terminate in good recovery after removal of the clot and insertion of packing. If suppuration does not occur in such cases one has a right to believe that function of the kidney has been restored. Removal of a kidney is so easily done that some are removed when nephrectomy is not demanded; this is also true of the spleen. Dr. Gibbon believes that a kidney which shows numerous lacerations, as did the one in Dr. Miller's case, is easier to save than is one containing a single large rent. A good working rule in rupture of the kidney is that if the bleeding can be controlled the kidney should not be removed.

DR. MILLER, in closing, said the justification for immediate operation in the case reported was the hemorrhage. Often in these cases if the surgeon waits he loses the favorable moment for operation. Dr. Miller agrees with Dr. Gibbon that only when the kidney is exposed can the surgeon determine what is the wisest procedure. In his case he decided that barring anuria or later suppuration the man might get well with a functioning kidney. It is to be remembered in deciding these cases that the patient has only two kidneys and if one be removed, loss of the other means death. So far as nephrectomy is concerned, the ruptured kidney in his case could have been removed with probably only slightly increased risk to the patient.

#### SARCOMA ORIGINATING IN THE ISCHIO-RECTAL FOSSA.

DR. GEO. ERETY SHOEMAKER said that sarcomatous growths may be found at widely distributed points in the body, as they

FIG. 2.



Sarcoma of ischio-rectal fossa. Two-thirds normal size. Age 21.

may occur wherever there is a connective tissue. It is, however, unusual to find them situated in the ischio-rectal fossa. Sarcomata are from time to time reported in the pelvis, behind the peritoneum, involving uterus or ovary, intestine, sacrum or one of the iliac bones in the pelvic basin, but such cursory search of indices and such inquiry among surgeons as he had been able to make would indicate that the perineal or ischio-rectal region is a most unusual location for this form of tumor.

In a series of 54 cases of osteosarcoma of bones of the pelvis, collected by Havage\*, there were none springing from the ischium or pubis and none in the ischio-rectal region. He now reported a case in which its early stage the differential diagnosis was difficult in comparison with a low grade of connective tissue inflammation. Careful observation, however, showed a continuous growth, a complete absence of tenderness, a discreet form, no tendency to involve the rectal wall and no tendency to point externally. On extirpation of the mass it proved to be a mixed type of sarcoma, with a small central area breaking down. The case was as follows:

A well developed, strong and vigorous girl of 21, a student in typical health, resident of Kansas. Family history negative, weight 118; tuberculosis in a maternal uncle and in a grandmother. Menstruation regular and normal, no history of injury of the part. One month before being referred by her physician a lump about the size of a walnut was noticed deep in the left perineum; aching, but with neither pain, tenderness nor throbbing. No history of discharge and none of constipation. Had been unusually well for a year. Examination showed superficially to the left of the rectum and vagina and behind a line drawn from the posterior vaginal commissure to the tuberosity of the ischium, extending from the rectal wall out nearly to the ramus of the pubis and nearly to the tuber ischii, a mass three inches from front to back, two inches from right to left, against the rectal wall but not infiltrating it, firm, somewhat movable. No softening, no redness. The condition resembled a low grade of inflammation in the pararectal tissues but was too firm. As a definite increase in size occurred with a tendency to greater fixation, the diagnosis of tumor was made (Fig. 2).

\*Tumors of the Pelvis. 1882.

An antero-posterior incision over the prominence was made  $1\frac{1}{4}$  inches to the left of the median line, immediately opposite the center of the perineum. There was no true capsule and no sharply defined line between normal and new tissue. Small areas of hardening projected from the growth anteriorly toward the vulva. At no point was the skin or mucous membrane involved. One or two small tortuous subcutaneous veins were visible. The growth invaded all tissue up to the rectal and vaginal walls and between them and the tuber ischii including muscle and fat. Half an inch behind the edge of the ischium it appeared to be firmly attached. The fingers were used to enucleate the mass and by blunt dissection it was separated from the pubis and ischium. It did not appear to infiltrate or expose bone. A superficial portion of the sphincter ani was preserved and only the superficial portions of the left labium majus. The constrictor vagina on the left side was sacrificed and the erector clitoridis cut in two. Hæmorrhage was not severe. The trunk of the internal pubic was caught behind the tuber ischii, giving a comparatively dry field. The tumor removed was three inches in antero-posterior diameter,  $2\frac{1}{2}$  inches in lateral diameter and 2 inches from without inward. The deeper parts of the wound were partly drawn together with catgut and the skin united except at the center, where gauze drainage was applied. There was no secondary hæmorrhage. Marked œdema of the anterior portion of the genitalia developed, making catheterization very difficult. Union appeared at the end of the first week, except at the point of drainage. There was no lack of control of the sphincter ani, but complete anæsthesia of the rectum and vagina on one side from division of nerves. The rectum did not slough.

Microscopical examination of the growth in the Laboratory of the Presbyterian Hospital showed sarcoma of mixed type. Although every vestige of visible or tangible disease was removed at the operation, recurrence was rapid locally and generally. The vulva and perineum of the left side were first invaded, the inguinal glands later. At the end of six months a mediastinal pressure is interfering with respiration and death is reported as imminent. Trypsin treatment has been used by her Kansas physician without benefit.

DR. CHARLES F. NASSAU cited a case seen three years ago which was similar to that of Dr. Shoemaker's, even to rapid

recurrence and death. The patient was a young man sent to the hospital with the diagnosis of ischio-rectal abscess. Suspecting malignancy, Dr. Nassau cut very wide of the lesion, taking everything to the tuberosity of the ischium. The tumor recurred in three months.

EXTREMELY VICIOUS UNION OF A FEMORAL FRACTURE  
SUCCESSFULLY TREATED BY OSTEOTOMY, NAIL-  
ING AND VERTICAL TRACTION.

DR. JOHN B. ROBERTS showed skiagraphs of this case to illustrate, (1) an unusual displacement as the result of a fracture; (2) the result gained by the use of nails and traction, and (3) the unreliability of the X-rays. The patient was a child of three years who was thrown down in a field by a calf winding him in the coils of a rope. He was seen by Dr. Roberts at the end of eleven weeks, when the leg showed five inches shortening. Operation by Dr. Roberts showed that the femur had been fractured, the fragments crossing and also being twisted. There was solid union and great force was required to chisel apart the fragments. Contraction of the muscles could not be entirely overcome by pulling. The fragments were adjusted, but still overlapped; to prevent twisting again taking place, two fracture nails were driven into them; and horizontal traction applied by the ordinary method. At the end of a week the nails were withdrawn, the leg put in the vertical position and a weight applied to stretch the muscles. The leg is now straight, there is solid union and careful measurement shows a shortening of about one and one-half inches. The skiagraph taken shows what appears to be an overlapping of three inches. The Crookes tube was probably not carefully placed over the fracture when the exposure was made. The medical profession should now deprecate too great reliance on the X-rays. Skiagraphs, taken as they usually are by a man who is not a surgeon and who does not know the case, are apt to lead to erroneous deductions. They may lead us into errors and should not be relied upon as much as people usually think.

DR. GEORGE G. ROSS agreed with Dr. Roberts as to the danger of the X-rays in fracture work; the picture is correct, but the interpretation is wrong. As corroboration of clinical diagnoses he has used many skiagraphs. He advises against having skiagraphs of results taken, as there may clinically and functionally

be a satisfactory termination and yet the X-rays shows an amazing condition.

DR. ROBERTS replying to a question as to how much was gained by traction upon the leg after removal of the nails, said that the nails were put in to prevent twisting, not overlapping, as he was afraid the original twist would recur. The nails were a temporary expedient to maintain apposition of the raw bone surfaces. As he thought that five days were sufficient to prevent twisting, the leg was then placed in the vertical position and traction with a weight and pulley applied. He does not know exactly how much was gained by this expedient but he felt that the operation had reduced the shortening from five to three inches. As the leg now is only one and one-half inches shorter than its fellow, he believes that he gained about three and one-half inches by the operation. There is, of course, the possibility that the legs were of unequal length before the fracture occurred.

BULLET WOUND PIERCING LUNG, DIAPHRAGM,  
AND THE SPLEEN.

DR. R. P. McREYNOLDS said gunshot wounds which penetrate the lungs, the diaphragm and some one or more of the abdominal viscera are not unusual but they are perhaps rare enough to justify the report of the following case which was seen in a private house in consultation with the attending physician, Dr. M. Graham Tull. A sixteen-year old boy attempted to shoot himself through the heart; but his knowledge of anatomy was not accurate and he missed his aim. The bullet entered the seventh interspace, mid-nipple line, ranged downward, passed through the diaphragm and came out posterior between the eleventh and twelfth ribs mid-scapular line.

DR. McREYNOLDS saw him within an hour of the accident; he had some dyspnoea, and some pain, but on the whole his general condition was good; he was but little shocked and the external hæmorrhage had been insignificant. But from the range of the bullet, the rigidity of the abdominal muscles and a marked increase in the leukocytes an immediate operation was advised. He was hurried to the Presbyterian Hospital and under general anaesthesia the abdomen was opened high up through the left rectus muscle. The spleen was found to have been almost bisected by the bullet and was bleeding freely; none of the other abdom-

inal organs were injured. An attempt to suture the wound in the spleen was made but failed and resort was had to tamponnage—the gauze being placed so as to approximate the edges of the wound and to stop the hæmorrhage. The usual after-treatment for such cases was instituted and wound healed by granulation.

From the thoracic wound a septic pneumonia developed from which a long and severe illness followed. However, he finally made a good recovery and now, two years after the injury, is strong and healthy.

Remarking upon this case Dr. McReynolds said that there are no early physical pathognomonic signs of internal hæmorrhage; prompt surgical action will however establish the diagnosis, and in the majority of cases give the patient the best chance for his life. In abdominal injuries requiring laparotomy, the rule “when in doubt operate at once” seems to be a good one. Penetrating wounds of the lung give a high mortality and the treatment of such cases is not altogether satisfactory. Dr. Rodman, in an excellent monograph on this subject, has very aptly summed it up in two words—“masterly inactivity.” This is certainly the accepted treatment of all simple penetrating wounds of the thorax, such as usually occurs when the wound of entrance is above the sixth interspace. But if the wound is below this point and there is reason to believe the diaphragm has been punctured and the abdominal viscera injured, the modern tendency is towards masterly activity. Dr. Daniel H. Williams in an article published in the ANNALS OF SURGERY, November, 1904, advocates resection of a rib, suturing the rent in the diaphragm and following the wound to the end. The success in a number of cases so treated would seem to justify this procedure, especially in cases where there is no wound of exit and therefore an uncertainty about the injury to the abdominal viscera.

Statistics show that gunshot wounds of the spleen have been most always fatal, the majority of the cases dying from hæmorrhage and generally within twenty-four hours. In dealing with a splenic wound there may be a choice of several procedures, *i.e.*, suturing with catgut and reënforcing by sewing the omentum over it, tamponnage with strips of gauze, splenectomy, cauterization. The first two are the methods of election. It would seem that the ideal procedure would be to close the wound with catgut sutures and then reinforce by sewing the omentum over it.



The spleen was first sutured by Lamarchia in 1896; his patient promptly died from hæmorrhage (he did not sew the omentum over the wound). However, others have been more successful—there are in this country two and probably more cases reported of successful splenorrhaphy. Treatment by tamponnage has given very good results. Berger in exhaustive statistics covering one hundred and twenty-seven cases of splenic wounds from various causes treated by laparotomy records ten cases treated by tamponnage with only one death. Successful cases of ruptured spleen treated by this method have been reported by Gibbon, Brewster and others. Senn from extensive experiments upon dogs concludes that marginal compression of the wound by hæmostatic forceps should precede the introduction of the catgut sutures, claiming that the compression diminishes the hæmorrhage and permits of the more easy and successful introduction of the sutures.

If the spleen has been so extensively injured that it cannot be sutured and tamponnage will not control the hæmorrhage a splenectomy is indicated; but this materially adds to the danger. The kind of the operation performed is not of so much importance as the time when it is performed. He had seen two cases of rupture of the spleen and both lost their lives, he thought because they were not operated on early enough.

#### PHANTOM URETERAL CALCULI.

DR. FRANCIS T. STEWART exhibited X-ray plates which were made from a patient in whom Dr. Dwyer suspected ureteral calculus because of pain radiating from the iliac regions to the loins, and the passing of large numbers of uric acid crystals. No blood was found in the urine. The plate, taken by Dr. Manges, shows shadows which at first were thought to be those of ureteral calculi. There were five on the left and two on the right side, one being large as a pea. More careful examination of the plate raised the suspicion that the shadows were not those of ureteral calculi, as the five on one side were not in perfect alignment and were outside the course of the ureter. Further investigation was decided upon and the bladder was inspected and both ureters catheterized, the latter appearing free. Both vaginal and rectal palpation, however, showed between the vagina and rectum extremely hard, apparently calcareous masses, five

on one side, and two on the other. They were not excised, hence their nature is unknown, but they were thought to be phleboliths. Cystoscopy showed that the orifice of the right ureter was in the middle line and that of the left further to the side than normal, so the situation of shadows out of the usual line might in some cases be regarded as due to calculi in the ureter.

The diagnosis of ureteral calculi by the X-rays is not absolutely positive, whether shadows are or are not shown. In one case ureteral colic was felt on one side, but two X-ray plates proved negative. As there was a little blood in the urine and colic persisted it was concluded that the X-rays were wrong. Catheterization of the ureter showed no obstruction, but as no urine came through the catheter for ten hours salt solution was injected. Aspiration then brought away many uric acid crystals which may have caused the obstruction. Dr. DaCosta has reported a case of calcareous lymphatic gland supposed to be a ureteral calculus. He operated in this case upon a perforated gastric ulcer which was followed by a long-persisting sinus. Incision finally showed at the bottom of the sinus a fecal and calcareous concretion. It is not known if this mass came from the stomach. Foreign bodies in the intestine may deceive the skiagrapher, though careful operators see that the bowels are well opened before taking the picture.

DR. JOHN B. ROBERTS said the possibility of erroneous showing of the X-rays is an interesting topic. In one instance under his observation they did reveal that a resident physician was not giving his patient proper attention and reporting all that he should. The patient had diarrhœa and had been given bismuth by the resident without reporting the matter to the surgeon. A skiagraph, taken for a lesion of the hip, incidentally showed by reason of the bismuth an impacted rectum, to which the diarrhœa was due.

DR. WILLIS T. MANGES, who had taken the skiagraphs exhibited by Dr. Stewart, said the X-ray makes no mistake but man makes the mistakes. Its character is shown by the fact that by it a foreign body in the eye or other part of the body can be localized and its position determined with absolute accuracy. The average hospital skiagrapher has too many cases to examine to do careful work. Dr. Manges has noticed in other cases shadows similar to those in Dr. Stewart's plates. In one case with

symptoms referable to the genito-urinary tract, the kidney region showed no evidence of stone, but on skiagraphing the pelvis there was shown two or three small, perfectly round bodies on either side, apparently calcareous or other hard masses. These bodies in the pelvis have been noticed only in cases examined for calculi. At times it is difficult to distinguish them from calculi, but ureteral calculi are rarely round. Among the skiagraphs exhibited by Dr. Manges was one of a patient who had ureteral or renal colic. There was no tenderness of the ureters and catheterization showed no obstruction; there was no blood in the urine. Dr. Manges made the diagnosis of ureteral calculus. The patient refused operation and improved. He is undetermined as to the exact condition present. The shadows are in the position of ureteral calculi, but they are perfectly round. Now in such a case, instead of insisting on operation he would say that calculi were not present. In another case of renal colic, blood in the urine, tenderness, but no obstruction to the catheter, the skiagraph showed small shadows which were not round. Two weeks later the patient had another attack of colic and a skiagraph then showed no bodies. In still another case of Dr. Stewart's the skiagraph agreed with the clinical diagnosis, but the patient refused operation. One year later a skiagraph showed a ureteral calculus still present. There was no obstruction to a catheter though the calculus was large as the end of a finger. The question is what are the small perfectly round bodies in the pelvis at times in the position of calculi or at other times near the brim of the pelvis where they clearly are not calculi? Dr. Manges intends to experiment upon cadavers for the purpose of determining what these bodies are.

DR. JOHN H. GIBBON, referring to the case mentioned by Dr. Manges in which skiagraphs were taken one year apart, said he examined three plates, each showing the presence of a body. Clinically there were attacks of renal colic. A catheter was passed, but that does not rule out the diagnosis of ureteral calculus, as he believes it possible to pass a catheter when a calculus is present. He believes the man has a calculus. Dr. Gibbon showed two plates, one of a case of ureteral calculus and one in which none was present. The one proved to be no calculus though there was blood in the urine and tenderness over the ureter. The skiagraph shows what appears to be a large stone.

The case was very deceptive, but after going over it several times the diagnosis of stone was made. When the abdomen was opened there was found a large hard body, but it was situated in the broad ligament instead of in the ureter. When removing it the mass ruptured, allowing the escape of material resembling white lead. The capsule was tense and it was finally decided the mass was tuberculous. The pathologist has not yet given an opinion as to its nature. This body had cast a shadow in the position of the ureter. The plate that does show a calculus was made from the patient from whom Dr. Gibbon removed the large cystic kidney shown at the previous meeting of the Academy. The calculus was removed by the extraperitoneal method. The patient is making a good recovery.

DR. GEORGE ERETY SHOEMAKER said he frequently turns phleboliths out of the pelvic veins during operations upon women. He has seen a loose calcareous body the size of a pigeon egg free in the peritoneum. Very small dense masses of dermoid material must also be reckoned with forming either the whole or part of dermoid tumors. He has seen one entire dermoid the size of a bantam's egg and one smaller. In one girl a calcareous mass was found against the bladder on the peritoneal side. Cheesy bodies in the pelvis are common. That day he had with difficulty turned out back of the broad ligament a sac with thick organized wall and cheesy contents resembling an ovary. This mass was the result of inflammatory and retrograde changes and would have given an X-ray picture in the line of the ureter.

DR. KELLY, who examined the bodies removed from the frimbria by Dr. Stewart, said there were five bodies about twice the size of the head of a pin and were round and smooth. They were composed of fibrin with calcareous material in the center.

DR. STEWART, in closing, said that in addition to phleboliths, foreign bodies in the intestine, calcareous glands, defective X-ray plates and dermoids, two other conditions are to be remembered in this connection. First, atheromatous plates in a blood vessel. Second, small, hard, calcareous masses in the end of the Fallopian tubes. The latter seem to be composed of fibrin and calcareous matter. During the past week he found several calcareous masses of this character apparently spring from the fimbriæ of the tubes. These were in the line of the ureter and would have suggested ureteral calculi had an X-ray plate been made.